



Original Article

## Craniofacial measurements in children with sella turcica shape's anomalies

Wafa Hammami<sup>1</sup>, Hiba Gmat<sup>2</sup>, Khoulood Ezzina<sup>3</sup>, Yamina Elelmi<sup>3</sup>, Chiraz Baccouche<sup>4</sup>, Soumaya Touzi<sup>4</sup>, Hichem Ghedira<sup>3</sup>

<sup>1</sup>Department of Dental Anatomy and Pediatric Dentistry, Dento-Facial Biological and Clinical Approach laboratory, Monastir, Tunisia, <sup>2</sup>Department of Orthodontics, Farhat Hached Hospital, Sousse, <sup>3</sup>Department of Pediatric Dentistry, <sup>4</sup>Department of Dental Anatomy, Monastir, Tunisia.



**\*Corresponding author:**

Wafa Hammami,  
Department of Dental Anatomy and Pediatric Dentistry, Dento-Facial Biological and Clinical Approach Laboratory, Faculty of Dentistry, Monastir, Tunisia.

hammamiwafaaa@gmail.com

Received : 19 January 2021


Accepted : 09 March 2021

Published : 12 January 2022

**DOI**

10.25259/APOS\_11\_2021

**Quick Response Code:**



### ABSTRACT

**Objectives:** The objective of the study is to evaluate the cephalometric measurements of Tunisian children who presented sella turcica's (ST) shape anomalies.

**Materials and Methods:** This cross-sectional study was conducted between January and June 2019 in the Department of Pediatric Dentistry of Monastir and Faculty of Dentistry of Tunisia. Radiographs were gathered from patients aged between 7 and 12 years old ( $n = 104$ ) who had consulted for a malocclusion. The inclusion criteria were considered as follows: Good visibility of anatomic structures and absence of congenital craniofacial deformities. We excluded bad radiographs with errors and discrepancies: Double limits, deformities as well as children having hereditary craniofacial anomalies and underlying diseases. The cephalometric analysis was conducted according to Segner and Hassund's method. ST's shape was identified according to Axelsson's classification modified by Becktor. The sample size was divided into groups: Group 1 with normal ST's shape and Group 2 with sella's anomaly. Statistics were performed using IBM SPSS STATISTICS 22. Data normality has been tested using Shapiro-Wilk test. The normality of variance was investigated too with Levene's test, and comparison of means between groups was performed with  $t$ -test.

**Results:** The prevalence of aberrations of ST's form in Tunisian children is about 59.6%. The inclination of upper incisors to the maxilla differed in children with ST's anomaly compared to normal kids. Children with sella aberration are characterized by retroclination of upper incisors to the maxilla. The variables which showed a statistically significant relationship between abnormalities of ST and cephalometric measurements were 1+NA with  $P = 0.03$  and NL-NSL with  $P = 0.04$ .

**Conclusion:** The prevalence of ST's shape anomalies in Tunisian children is about two-thirds. It seems that the anomaly of ST influences the position of the maxilla to the cranial base and the position of upper incisors to the maxilla.

**Keywords:** Sella turcica, Anomalies, Children, Cephalometric, Dysmorphia

### INTRODUCTION

Several cephalometric analyses and different landmarks have pursued through the literature to diagnosis skeletal craniofacial relationship and dentoalveolar malocclusion. Sella turcica (ST) is a very important structure and considered as a reference in the cephalometric analysis. The center of the sella, the S point, is used to measure the position of structures (such as the maxilla or the mandible) to the cranium or to each other.<sup>[1]</sup> The development of ST took place with this of the

This is an open-access article distributed under the terms of the Creative Commons Attribution-Non Commercial-Share Alike 4.0 License, which allows others to remix, tweak, and build upon the work non-commercially, as long as the author is credited and the new creations are licensed under the identical terms.

©2021 Published by Scientific Scholar on behalf of APOS Trends in Orthodontics

pituitary gland and finished after it.<sup>[2]</sup> Thus, any anomaly of the gland will affect the form of the ST.<sup>[2]</sup> In the embryological development, neural crest cells and mesodermal cells are involved. Thus, shape anomalies of the ST may be accompanied by functional disorders in the pituitary gland and by morphological abnormalities of the facial bones.<sup>[2]</sup>

Pediatric dentists and orthodontists are the first detectors of this defect and they contribute to an early diagnosis of hormonal troubles.

The literature reported that the morphological form of ST has been established since the early embryonic stage.<sup>[1]</sup> Normal shape has been identified since 1924 with three types: Flat, round, and oval. The flat type is the least found and the oval type is the most detected.<sup>[3]</sup>

The aim of this study is to evaluate the cephalometric measurements of Tunisian children with ST's shape anomalies.

## MATERIALS AND METHODS

One hundred and four lateral radiographs were collected from the Department of Pediatric Dentistry of Monastir of children aged between 7 and 12 years old who had consulted for a malocclusion.

### Inclusion criteria

- A good visibility of anatomic structures
- The absence of congenital craniofacial deformities and underlying diseases.

### Non-inclusion criteria

- The presence of hereditary craniofacial malformations
- Radiographs with errors and discrepancies
- Radiographic deformities
- Double limits.

Cephalometric measurements were performed according to Segner and Hassund's analysis.<sup>[2]</sup> Landmarks were represented in [Figure 1] and measurements in [Table 1].

ST's shape identification was performed according to Axelsson *et al.*'s classification modified by Becktor *et al.*<sup>[4]</sup> [Table 2].

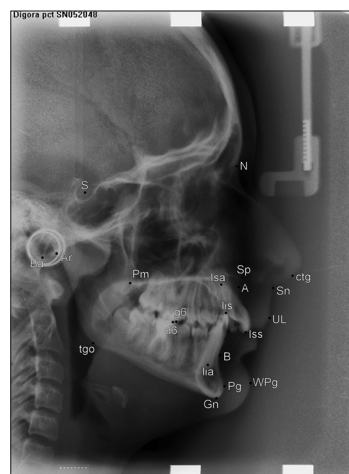
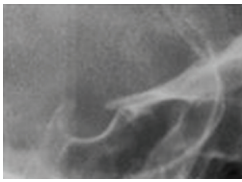
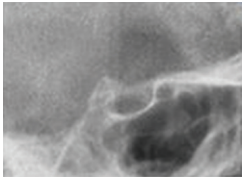
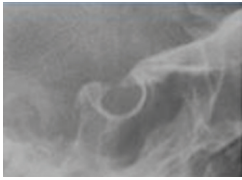
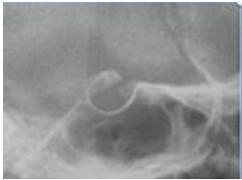
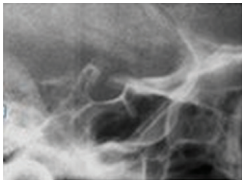

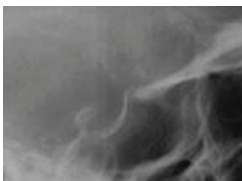
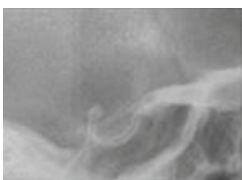


Figure 1: Segner and Hassund landmarks.

Table 1: Cephalometric measures according to Segner and Hassund.

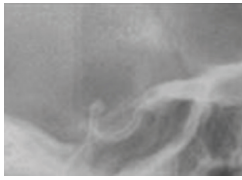
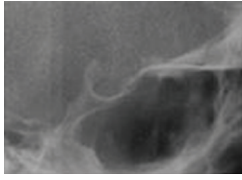
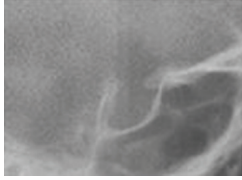
Cephalometric value	Definition
SNA	Anteroposterior position of point A in relation to anterior cranial fossa. Clinically, this angle describes the sagittal position of the maxilla
SNB	Anteroposterior position of mandible in relation to the anterior cranial fossa
ANB	Sagittal relation between the maxilla and mandible
SNPg	Angle describing the sagittal position of the mandible
NSBa	Angle of the cranial base describing the degree of cranial base bending, for example, the relation of clivus to the anterior cranial fossa
Gn-tgo-Ar	Mandibular angle describing the inclination between the ramus and corpus of the mandible
NL-NSL	Angle describing the inclination of maxillary base to the anterior cranial fossa
ML-NSL	Angle specifying the inclination of mandibular base to the anterior cranial fossa
ML-NL	Angle describing the inclination between the bases of maxilla and mandible
H	Relationship between soft-tissue profile and hard-tissue profile
1+1-	Interincisal angle. The angle between the axis of the upper and lower central incisors
1+:NA	Axis of the upper incisors in reference to maxillary base
1-:NB	Axis of the lower incisors in reference to mandibular base
Nasolabial angle	Relationship between the upper lip and nose
PG: NB (mm)	Distance between Pg point line between points N and B
1+NA (mm)	Upper incisors in reference to maxillary base
1-NB (mm)	Lower incisors in reference to mandibular base
Index	Ratio (%) between the middle and lower face
Wits (mm)	Distance between the perpendicular projection of points A and B on occlusal plane

**Table 2:** Classification of the morphology of sella turcica according to Axelsson *et al.*

Shape of sella turcica	SPSS symbol	Figure
Normal sella turcica.	1	
Sella turcica bridge type A—ribbon-like fusion	2	
Sella turcica bridge type B—extension of the clinoid processes	3	
Incomplete bridge	4	
Hypertrophic posterior clinoid process	5	
Hypotrophic anterior clinoid process	6	
Irregularity (notching) in the posterior part of the sella turcica.	7	
Pyramidal shape of the dorsum sellae	8	

(Contd...)

**Table 2:** (Continued)

Shape of sella turcica	SPSS symbol	Figure
Double contour of the floor	9	
Oblique anterior wall	10	
Oblique contour of the floor	11	

The sample size was divided into two groups according to the shape of the ST.<sup>[3]</sup> – “Group 1” without anomaly of ST with 42 participants and a second “Group 2” of 64 children with sella anomalies. Statistics were performed with IBM SPSS Statistics 22. Data normality was tested using Shapiro–Wilk test. Levene’s test was used for equality of variance and student *t*-test for comparison of means between the two groups.

## RESULTS

### Cephalometric measurements

Cephalometric values of the two groups were represented in [Tables 3 and 4]. For each variable, the mean, median, standard deviation, minimum and maximum, and percentiles were calculated.

The comparison of means for each tested variable had led to a small difference between them. Only the inclination of upper incisors to the maxilla (1+NA) was lower in the studied group, Group 2, than the control group with 10° of difference [Table 5].

Levene’s test for equality of variances [Table 6] showed for all the variables,  $P > 0.05$ .

Independent sample student *t*-test has given a statistical significant relationship for two variables: 1+NA with  $P = 0.03$  and NL-NSL with  $P = 0.04$  [Table 6].

Levene’s test had shown for all variables,  $P > 0.05$  [Table 6].

**Table 3:** Cephalometric values of “Group 1.”

Variable	Mean	Standard deviation	Median	Percentile (25)	Percentile (75)	Min	Max
SNA	81.19	4.29	81.00	77.00	84.00	75.00	89.00
SNB	76.90	4.24	77.00	73.50	79.00	70.00	87.00
ANB	4.33	4.10	5.00	2.00	6.50	-3.00	16.00
SNPg	76.28	4.78	75.00	73.00	81.00	69.00	87.00
NSBa	132.76	7.11	132.00	129.50	138.00	119.00	143.00
Gn-tgo-Ar	131.47	3.85	132.00	128.50	134.50	124.00	139.00
NL-NSL	9.42	3.34	09.00	7.00	11.00	6.00	20.00
ML-NSL	9.33	6.01	39.00	34.50	41.00	31.00	55.00
1+1-	119.95	12.03	118.00	110.00	128.50	103.00	150.00
1+:NA angle	115.33	7.70	113.00	110.50	121.05	100.00	131.00
1-:NB angle	92.61	9.89	92.00	84.50	98.00	79.00	116.00
Nasolabial angle	106.38	16.35	105.00	93.00	116.00	85.00	143.00
Pg: NB (mm)	1.42	1.39	1.00	0.50	02.00	0.00	05.00
Index	0.81	0.08	0.82	0.76	0.88	0.63	0.96
Wits (mm)	2.19	3.50	2.00	1.50	4.00	-11.00	07.00
Class I	1.87	0.99	2.00	1.25	2.75	0.00	0.30
Class II	7.27	3.22	6.00	05.00	07.00	5.00	16.00
Class III	-02.00	1.41	-02.00	-3.00	-	-3.00	-1.00

**Table 4:** Cephalometric values of “Group 2.”

Variable	Mean	Standard deviation	Median	Percentile (25)	Percentile (75)	Min	Max
SNA	79.25	5.42	79.00	75.00	82.00	68.00	91.00
SNB	75.29	5.00	76.00	72.00	78.00	66.00	87.00
ANB	3.95	2.88	4.00	2.00	6.00	-3.00	10.00
SNPg	75.70	5.00	76.00	73.00	79.00	66.00	88.00
NSBa	134.25	5.96	135.00	131.00	137.00	121.00	147.00
Gn-tgo-Ar	131.12	5.38	131.00	128.00	135.00	121.00	142.00
NL-NSL	7.29	3.62	07.00	5.00	10.00	1.00	14.00
ML-NSL	6.87	5.48	37.00	34.00	41.00	24.00	46.00
1+1-	125.54	12.39	126.00	116.00	132.00	101.00	150.00
1+:NA angle	104.83	21.24	110.00	100.00	115.00	4.00	122.00
1-:NB angle	93.03	9.22	92.00	89.00	100.00	67.00	110.00
Nasolabial angle	107.90	14.85	112.00	100.00	120.00	77.00	128.00
Pg: NB (mm)	1.51	1.23	1.00	1.00	02.00	0.00	05.00
Index	0.73	0.09	0.75	0.71	0.78	0.42	0.92
Wits (mm)	2.48	2.17	2.00	1.00	4.00	-03.00	07.00
Class I	2.75	1.18	3.00	2.00	4.00	01.00	04.00
Class II	6.46	1.80	6.00	5.00	7.50	05.00	10.00
Class III	-2.50	0.70	-2.50	-3.00	-	-03.00	-2.00

**DISCUSSION**

Cephalometric radiograph is a helpful tool in the diagnosis, treatment planning, and predicting the outcome in our practice. The center of ST is routinely used as a cephalometric landmark to act as a reference point for evaluating spatial position of both jaws as their relation to the cranial base.

The variation of ST's shape has been described by several authors such as Gordon and Bell;<sup>[5]</sup> Camp;<sup>[6]</sup> and Tetradis

and Kantor.<sup>[7]</sup> In a recent study, it was categorized into six main types: Normal ST, oblique anterior wall, double-contoured sella, ST bridge, irregularity in the posterior part of the sella, and pyramidal shape of the dorsum sellae.<sup>[3]</sup> Becktor *et al.* detailed the sella bridging in complete and incomplete ones.<sup>[4]</sup>

Several pathologies of the pituitary gland which sat on the pituitary fossa of the sphenoid bone can alter the shape and size of ST. Some patients with an abnormal ST are suffering from several underlying diseases: intrasellar primary

**Table 5:** Comparison of means of the two groups.

Measure	Normality of shape of sella turcica	Mean	Std. Deviation	Std. Error Mean
SNA	1	81.19	4.297	0.938
	0	79.40	5.456	0.996
SNB	1	76.90	4.242	0.926
	0	75.43	5.029	0.918
ANB	1	4.33	4.103	0.895
	0	3.97	2.930	0.535
SNPg	1	76.29	4.787	1.045
	0	75.87	5.008	0.914
NSBa	1	132.76	7.120	1.554
	0	134.20	6.065	1.107
Gn-tgo-Ar	1	131.48	3.855	0.841
	0	131.33	5.352	0.977
1+1-	1	119.95	12.035	2.626
	0	125.53	12.607	2.302
1+: NA	1	115.33	7.703	1.681
	0	104.83	21.134	3.859
1- :NB	1	92.62	9.892	2.159
	0	92.80	9.294	1.697
NL-NSL	1	9.43	3.340	0.729
	0	7.20	3.652	0.667
ML-NSL	1	39.33	6.019	1.314
	0	36.73	5.521	1.008
Nasolabial angle	1	106.38	16.357	3.569
	0	107.43	14.871	2.715
Pg/NB	1	1.43	1.399	0.305
	0	1.57	1.223	0.223
Index	1	0.8176	0.08360	0.01824
	0	0.7317	0.09498	0.01734
Wits	1	2.19	3.502	0.764
	0	2.53	2.193	0.400

\*1: Normal sella turcica, 0: Abnormality in the morphology of sella

tumors, hypopituitarism, and syndromes such as Down and Williams.<sup>[8]</sup>

Hence, the abnormal morphology of the ST may provide an insight to examine patients suffering from these conditions.

Our study represents a first research in this field in Tunisia. Comparing to the world, the prevalence of ST anomaly in the polish children was 46.9% which is not far from our findings 59.6%.<sup>[2]</sup>

This difference may be due to ethnicity and population special specificities.

Comparison of mean value led to similar cephalometric measurements between the studied and the control group. The only variable that showed a huge difference in mean value was the inclination of upper incisors to the maxilla: 1+:NA with a value of 10° [Table 5]. It seems that the Tunisian children with ST anomalies presented a posterior position of

the maxilla to the cranial base comparing to normal children. This result is similar to the polish pediatric population.<sup>[2]</sup>

Levene's test had shown for all variables,  $P > 0.05$ , which means that the variances of the two groups were equals [Table 6].

Student *t*-test revealed a statistic significant relationship between the anomaly of ST and the inclination of upper incisors to the maxilla: 1+:NA with  $P = 0.03$  [Table 6] and the position of the maxilla to the cranial base: NL-NSL with  $P = 0.04$  [Table 6]. Thus, ST's morphology effects the inclination of maxillary bone to the anterior cranial fossa and the anteroposterior position of the upper incisors to the base of the maxilla.

Numeric analysis software is recommended for more precision. Abnormal findings in the morphology of ST which are found in lateral cephalograms should be subjected to advance imaging modalities such as MRI and scanner for confirming the pathology.

**Table 6:** Student *t*-test for independent sample.

Measures	Variances	Levene's test for equality of variances		<i>t</i> -test for equality of means						
		F	Sig.	<i>t</i>	df	Sig. (2-tailed)	Mean difference	Standard error difference	95% confidence interval of the difference	
									Lower	Upper
SNA	Equal variance assumed	0.66	0.42	1.37	50	0.18	1.93	1.42	-0.91	4.77
	Equal variance not assumed			1.43	48.67	0.16	1.93	1.35	-0.78	4.65
SNB	Equal variance assumed	0.51	0.47	1.21	50	0.23	1.62	1.33	-1.06	4.29
	Equal variance not assumed			1.25	47.42	0.22	1.62	1.29	-0.98	4.21
ANB	Equal variance assumed	2.39	0.13	0.38	50	0.71	0.37	0.97	-1.58	2.31
	Equal variance not assumed			0.35	33.13	0.73	0.37	1.03	-1.74	2.47
SNPg	Equal variance assumed	0.01	0.90	0.42	50	0.68	0.57	1.39	-2.22	3.38
	Equal variance not assumed			0.42	44.35	0.68	0.57	1.38	-2.20	3.35
NSBa	Equal variance assumed	1.30	0.26	-0.80	50	0.43	-1.46	1.82	-5.13	2.20
	Equal variance not assumed			-0.77	37.84	0.44	-1.46	1.89	-5.28	2.35
Gn-tgo-Ar	Equal variance assumed	1.78	0.19	0.25	50	0.80	0.35	1.36	-2.39	3.09
	Equal variance not assumed			0.27	49.80	0.79	0.35	1.28	-2.28	2.92
1+1-	Equal variance assumed	0.01	0.91	-1.62	50	0.11	-5.60	3.46	-12.55	1.36
	Equal variance not assumed			-1.62	43.94	0.11	-5.60	3.44	-12.54	1.34
1+: NA	Equal variance assumed	2.21	0.14	2.16	50	0.03	10.49	4.85	0.75	20.24
	Equal variance not assumed			2.52	40.49	0.02	10.49	4.17	2.07	18.92
1- :NB	Equal variance assumed	0.05	0.81	-0.15	50	0.88	-0.41	2.68	-5.80	4.98
	Equal variance not assumed			-0.15	41.03	0.88	-0.41	2.72	-5.91	5.03
NL-NSL	Equal variance assumed	1.01	0.32	2.15	50	0.04	2.19	0.99	0.14	4.13
	Equal variance not assumed			2.19	45.40	0.03	2.19	0.98	0.17	4.11
ML-NSL	Equal variance assumed	0.07	0.79	1.53	50	0.13	2.46	1.61	-0.77	5.70
	Equal variance not assumed			1.50	40.31	0.14	2.46	1.64	-0.85	5.78
Nasolabial angle	Equal variance assumed	0.17	0.68	-0.35	50	0.73	-1.52	4.37	-10.31	7.26
	Equal variance not assumed			-0.34	40.21	0.73	-1.52	4.46	-10.53	7.48
Pg/NB	Equal variance assumed	0.17	0.68	-0.24	50	0.81	-0.09	0.37	-0.83	0.65
	Equal variance not assumed			-0.23	39.37	0.82	-0.09	0.38	-0.85	0.68
Index	Equal variance assumed	0.10	0.75	3.36	50	0.00	0.08	0.02	0.03	0.13
	Equal variance not assumed			3.43	46.16	0.00	0.08	0.02	0.03	0.13
Wits	Equal variance assumed	0.11	0.75	-0.37	50	0.71	-0.29	0.79	-1.87	1.28
	Equal variance not assumed			-0.34	30.42	0.73	-0.29	0.86	-2.04	1.46

**CONCLUSION**

About 30% of the studied group had a normal sella shape. Cephalometric measurements which range with the sella form are NL-NSL and 1+NA.

The results of the present study can be used as reference standards for Tunisian pediatric population.

Further researches should be conducted to more investigate this participant and to detail the distribution of different ST anomalies in terms of sex and why not to study the relationship between skeletal class and ST aberrations.

**Declaration of patient consent**

Patient's consent not required as patient's identity is not disclosed or compromised.

**Financial support and sponsorship**

Nil.

**Conflicts of interest**

There are no conflicts of interest.

**REFERENCES**

- Alkofide EA. The shape and size of the sella turcica in skeletal Class I, Class II, and Class III Saudi subjects. *Eur J Orthod* 2007;29:457-63.
- Kucia A, Jankowski T, Siewniak M, Janiszewska-Olszowska J, Grocholewicz K, Szych Z, *et al.* Sella turcica anomalies on lateral cephalometric radiographs of Polish children. *Dentomaxillofac Radiol* 2014;43:20140165.
- Axelsson S, Storhaug K, Kjaer I. Post-natal size and

morphology of the sella turcica. Longitudinal cephalometric standards for Norwegians between 6 and 21 years of age. *Eur J Orthod* 2004;26:597-604.

4. Becktor JP, Einersen S, Kjaer I. A sella turcica bridge in subjects with severe craniofacial deviations. *Eur J Orthod* 2000;22:69-74.
5. Gordon MB, Bell AL. A roentgenographic study of the sella turcica in normal children. *Endocrinology* 1923;7:52-6.
6. Camp JD. The normal and pathologic anatomy of the sella turcica as revealed at necropsy. *Radiology* 1923;1:65-73. Available from: <https://www.pubs.rsna.org>. [Last accessed on 2021 Jan 07].
7. Tetradis S, Kantor ML. Prevalence of skeletal and dental anomalies and normal variants seen in cephalometric and other radiographs of orthodontic patients. *Am J Orthod Dentofacial Orthop* 1999;116:572-7.
8. Valizadeh S, Shahbeig S, Mohseni S, Azimi F, Bakhshandeh H. Correlation of shape and size of sella turcica with the type of facial skeletal class in an Iranian group. *Iran J Radiol* 2015;12:e16059.

**How to cite this article:** Hammami W, Gmati H, Ezzina K, Elelmi Y, Baccouche C, Touzi S, *et al.* Craniofacial measurements in children with sella turcica shape's anomalies. *APOS Trends Orthod* 2021;11:288-94.