

Experts Corner

## Early treatment of dentoskeletal Class III malocclusion: SEC III protocol

Letizia Perillo

Multidisciplinary Department of Medical – Surgical and Dental Specialties, University of Campania Luigi Vanvitelli, Naples, Italy.



**\*Corresponding author:**

Letizia Perillo,  
Multidisciplinary Department  
of Medical – Surgical and  
Dental Specialties, University  
of Campania Luigi Vanvitelli,  
Naples 80138, Italy.

[letizia.perillo@unicampania.it](mailto:letizia.perillo@unicampania.it)

Received : 13 May 19


Accepted : 14 May 19

Published : 29 June 19

**DOI**

10.25259/APOS-56-2019

**Quick Response Code:**



### ABSTRACT

Dentoskeletal Class III malocclusions are one of the greatest challenges to the orthodontists due to the interaction of both environmental and genetic etiological factors. Over the years, several interceptive treatments for Class III dentoskeletal malocclusions have been proposed in growing patients. Our orthopedic approach includes two occlusal Splints combined with Class III Elastics and Chincup and so it is named SEC III protocol. The main difference with all the other appliances is the vertical control that is crucial, above all, in the most difficult cases as the hyperdivergent Class III malocclusions.

**Keywords:** Class III malocclusion, Early treatment, SEC III protocol

### INTRODUCTION

Dentoskeletal Class III malocclusions are one of the greatest challenges to the orthodontists due to the interaction of both environmental and genetic etiological factors.<sup>[1]</sup>

The incidence in the White population is low, ranging between 1% and 5%, but – sooner or later – a child with a Class III malocclusion may peek out in our practice and we have to decide if to treat him or not.<sup>[2]</sup>

Currently, we have many options of treatment, from the interceptive treatment to perform during the childhood to the treatment in permanent dentition with fixed appliances eventually associated with extractions and/or temporary anchorage devices, from the surgery first to the surgery in the adulthood.<sup>[3-5]</sup>

However, when a child shows a dentoskeletal Class III malocclusion, very often the parents require an orthodontic treatment to improve both the occlusion and the esthetics.

Moreover, the early treatment may help these children to avoid psychological problems, increasing their self-confidence and self-esteem and, at the same time, the worsening of the Class III malocclusion during the growing period.

For these reasons, although aware of the uncertainty of the result, it may be useful to perform an early treatment of the Class III malocclusion, at least in some cases.<sup>[4]</sup>

The early treatment can help to promote a favorable skeletal equilibrium correcting the negative overjet, enhancing the maxillary growth and limiting the mandibular one, controlling and/or eliminating the environmental factors, and minimizing the incisor compensation.<sup>[1-2,4]</sup>

This is an open-access article distributed under the terms of the Creative Commons Attribution-Non Commercial-Share Alike 4.0 License, which allows others to remix, tweak, and build upon the work non-commercially, as long as the author is credited and the new creations are licensed under the identical terms.

©2019 Published by Scientific Scholar on behalf of APOS Trends in Orthodontics

Moreover, the early treatment, if successful, may reduce the length of the fixed appliance phase and, even in case of failure, can make less invasive surgery at the end of the growth.<sup>[4]</sup>

Over the years, several interceptive treatments for Class III dentoskeletal malocclusions have been proposed in growing patients<sup>[3-5]</sup> although most of them aim to correct the dentoskeletal Class III malocclusion not only through sagittal

skeletal changes associated with some dental compensation but also through a compensative clockwise mandibular rotation. Moreover, for these options, there is often a lack of long-term outcomes.

I am delighted to describe our orthopedic approach, including two occlusal splints combined with Class III Elastics and Chincup and so named SEC III.<sup>[4]</sup>

The main difference with all the other appliances is the vertical control that is crucial, above all, in the most difficult cases as the hyperdivergent Class III malocclusions.

### SEC III protocol

The SEC III protocol includes two occlusal Splints, Class III Elastics, and Chincup [Figure 1].

The aim is to facilitate the correction of the dentoskeletal Class III malocclusion on the sagittal plane, avoiding clockwise mandibular rotation and minimizing incisor compensation.

The two removable acrylic splints cover not only the occlusal surface but also the buccal and lingual ones. The splints have to be completely smooth to avoid any discomfort to the patient and need to have a flat occlusal plane to freely sliding one over the other, facilitating the sagittal Class III correction. Moreover, the splints help to eliminate or control Class III

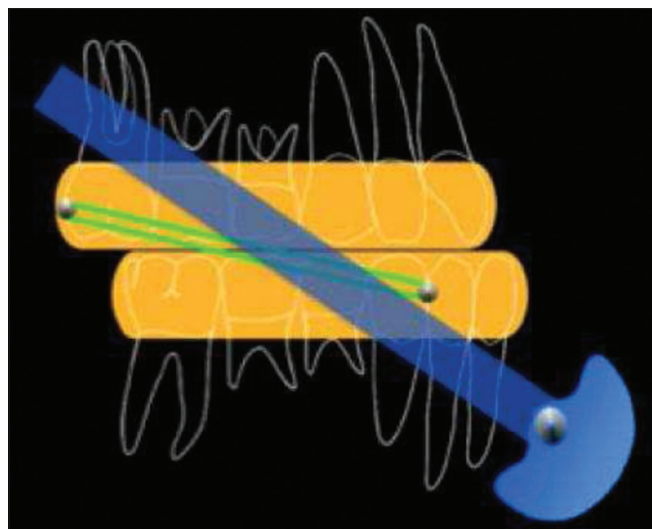


Figure 1: SEC III protocol.

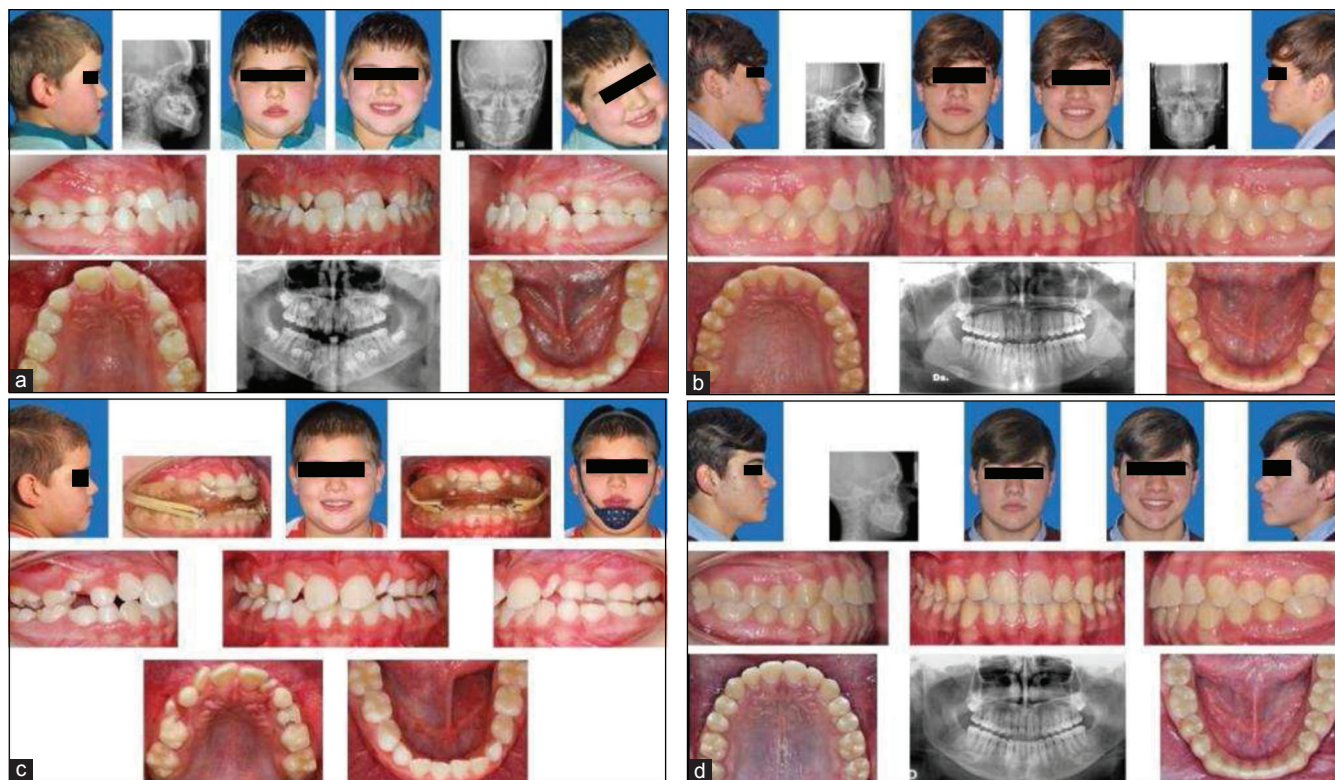


Figure 2: (a) Clinical Case – initial checkup (b) Clinical Case – checkup, after SEC III treatment (c) Clinical Case – final checkup, after multibracket fixed appliances (d) Clinical Case – checkup, after 2-year retention.

worsening factors such as the anterior interposition and the lower position of the tongue and the deflecting contacts.

Four buccal hooks, two in the upper and two in the lower arch, are symmetrically located on each side of the splints, distally to the maxillary last molars and between the mandibular canines and lateral incisors.

The Class III elastics are applied on these hooks with a force ranging from 5 to 25 ounces (between 150 and 750 g) per side. Force levels depend mainly on the splint stability. Patients are instructed to wear them for a minimum of 16 h per day and to change them at least twice a week.<sup>[4]</sup> These elastics allow a forward movement of the maxilla along with the upper arch and a posterior movement of the mandible with the lower arch.

The side effect is the extrusion of the upper molars with a following clockwise mandibular rotation. To avoid such undesirable side effect, a chincup is applied with the force vector passing through the first upper molars.

The chincup develops a force ranging from 16 to 32 ounces (between 500 and 800 g) per side [Figure 1], and the patient is required to wear it for a minimum of 14 h per day. However, the magnitude of force is always related to the individual tolerance. Temporary side effects such as local alopecia and inflammation of the chin may be reported and have to be explained to the parents.

This SEC III active phase lasts until a positive overjet (2–3 mm) is reached. On average, about 1 year of SEC III protocol is needed. However, time differences are mainly related to a patient's age, cooperation, and severity of the dentoskeletal problems.<sup>[4,5]</sup>

At the end of the active phase, if necessary, patients receive supplemental treatment – e.g. rapid maxillary expansion, lingual grid, transpalatal bar, etc., useful to solve other problems.

During this waiting period, patients are asked to wear the chincup only at bedtime. The aim is to maintain and stabilize the occlusal sagittal correction achieved during the active phase and, above all, to control the mandibular growth. Thus, the chincup vector has to pass through the condyle delivering a force ranging from 16 to 32 ounces (between 500 and 800 g) per side.

This protocol allows a sagittal dentoskeletal Class III correction associated with a minimum dentoalveolar compensation and, above all, with a good vertical control without clockwise mandibular rotation. Here, you can see a clinical case treated with the SEC III protocol, followed by fixed appliances [Figure 2 a-d]. Written consent was obtained from the patient's parents.

The outcomes of the SEC III protocol are mainly stable at the end of the growth.<sup>[4]</sup>

However, for the few patients showing a relapse, usually hyperdivergent cases, a modified SEC III protocol has been proposed.

### Modified SEC III protocol

The modified SEC III protocol aims to achieve a greater vertical control [Figure 3].

For this purpose, the upper splint is trimmed from the first upper molar to molar to create a wedge effect with a single contact point on the last molars.

This wedge effect is stressed adding to the lateral Class III elastics, an anterior elastic with a force ranging from 8 to 15 ounces (between 250 and 500 g), placed on three hooks: two located in the upper arch, between the cuspids and the lateral incisors, and one positioned in the lower arch on the midline.

This modified SEC III protocol allows a greater intrusion of the posterior teeth, associated with an increased counterclockwise mandibular rotation and a deeper overbite,

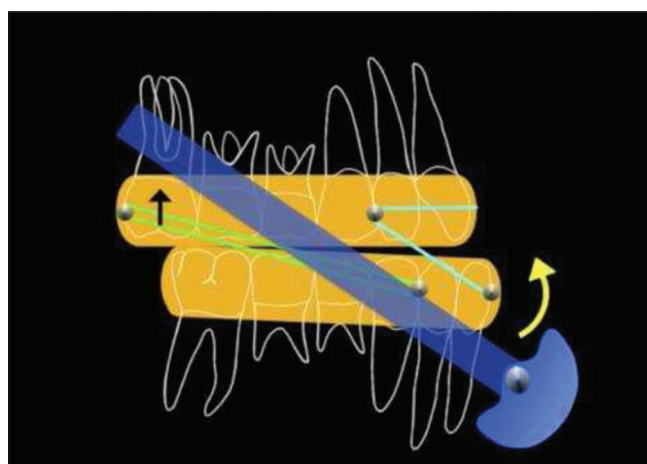


Figure 3: Modified SEC III protocol.

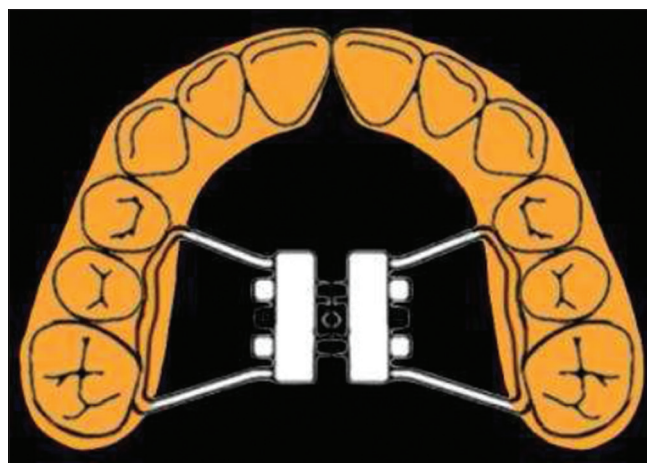


Figure 4: Bonded upper splint with an expansion screw.

goals useful, above all, in patients with a vertical growth pattern.

Moreover, because hyperdivergent Class III malocclusions frequently show also a dentoskeletal cross-bite, it is possible to insert an expansion screw in the upper splint to correct it.<sup>[6,7]</sup>

In these cases, the upper splint has to be bonded on the upper arch [Figure 4] from the deciduous canines to the second deciduous molars or to the first permanent molars when erupted.

Patients are instructed to wear the lower splint, the elastics, and the chin cup with a force vector through the first upper molars for about 1 year, as previously described.

Afterward, even in the new protocol, waiting for the transition period, the upper bonded splint may be eventually substituted with other needed appliances, wearing the chin cup only at bedtime with a force vector passing through the condyle for a better control of the mandibular growth.

## CONCLUSIONS

Today, the early treatment is the gold standard for a growing child with a dentoskeletal Class III malocclusion.

The different protocols now available, including SEC III and modified SEC III, allow to achieve a sagittal dentoskeletal correction with some degree of incisor compensation.

However, the key point that makes the difference is the vertical control.

The SEC III protocol allows a good vertical control with no clockwise mandibular rotation, whereas the modified SEC III protocol provides even a better vertical control and, if required, the correction of the cross-bite.

## Declaration of patient consent

The authors certify that they have obtained all appropriate patient consent forms. In the form, the patient has given her consent for her images and other clinical information to be

reported in the journal. The patient understand that their names and initials will not be published and due efforts will be made to conceal their identity, but anonymity cannot be guaranteed.

## Financial support and sponsorship

Nil.

## Conflicts of interest

There are no conflicts of interest.

## REFERENCES

1. Perillo L, Monsurrò A, Bonci E, Torella A, Mutarelli M, Nigro V, *et al.* Genetic association of ARHGAP21 gene variant with mandibular prognathism. *J Dent Res* 2015;94:569-76.
2. Perillo L, Masucci C, Ferro F, Apicella D, Baccetti T. Prevalence of orthodontic treatment need in southern Italian schoolchildren. *Eur J Orthod* 2010;32:49-53.
3. Jamilian A, Cannavale R, Piancino MG, Eslami S, Perillo L. Methodological quality and outcome of systematic reviews reporting on orthopaedic treatment for class III malocclusion: Overview of systematic reviews. *J Orthod* 2016;43:102-20.
4. Ferro A, Nucci LP, Ferro F, Gallo C. Long-term stability of skeletal class III patients treated with splints, class III elastics, and chin cup. *Am J Orthod Dentofacial Orthop* 2003;123:423-34.
5. Perillo L, Vitale M, Masucci C, D'Apuzzo F, Cozza P, Franchi L, *et al.* Comparisons of two protocols for the early treatment of class III dentoskeletal disharmony. *Eur J Orthod* 2016;38:51-6.
6. Grassia V, D'Apuzzo F, Ferrulli VE, Matarese G, Femiano F, Perillo L, *et al.* Dento-skeletal effects of mixed palatal expansion evaluated by postero-anterior cephalometric analysis. *Eur J Paediatr Dent* 2014;15:59-62.
7. Grassia V, d'Apuzzo F, DiStasio D, Jamilian A, Lucchese A, Perillo L, *et al.* Upper and lower arch changes after mixed palatal expansion protocol. *Eur J Paediatr Dent* 2014;15:375-80.

**How to cite this article:** Perillo L. Early treatment of dentoskeletal Class III malocclusion: SEC III protocol. *APOS Trends Orthod* 2019;9(2):73-6.