



Original Article

## Changes in the nasal and pharyngeal airway volume with miniscrew-assisted rapid palatal expansion appliances

Peter Ngan<sup>1</sup>, Joanna Song<sup>1</sup>, Jun Xiang<sup>2</sup>, Hong He<sup>3</sup>, Chris A. Martin<sup>1</sup>, Bryan Weaver<sup>4</sup>

Departments of <sup>1</sup>Orthodontics and <sup>2</sup>Family Medicine, Health Sciences Center, West Virginia University, Morgantown, West Virginia, United States,

<sup>3</sup>Department of Stomatology, Wuhan University School of Stomatology, Wuhan, China, <sup>4</sup>Department of Oral and Maxillofacial Surgery, Health Sciences Center, West Virginia University, Morgantown, West Virginia, United States.



**\*Corresponding author:**


Peter Ngan,  
Department of Orthodontics,  
West Virginia University,  
Morgantown, West Virginia,  
United States.

ngan@hsc.wvu.edu

Received: 10 December 2021  
Accepted: 02 February 2022  
Epub Ahead of Print: 23 June 2022  
Published: 29 November 2022

DOI  
10.25259/APOS\_175\_2021

**Quick Response Code:**



### ABSTRACT

**Objectives:** The purpose of this study was to assess the volumetric changes in the nasal and pharyngeal airway volume in patients with maxillary transverse deficiency treated with miniscrew-assisted rapid palatal expansion (MARPE) appliances.

**Material and Methods:** The pre- and post-treatment cone-beam computed tomography scans of 20 subjects who underwent treatment with the MARPE appliance as part of their orthodontic treatment were included in the study. Pre- and post-expansion airway volume measurements of the nasal cavity, nasopharynx, and oropharynx were measured. Linear measurements of the skeletal structures surrounding the nasal cavity were taken to assess the pattern of airway expansion. Paired *t*-tests were used to evaluate nasal and pharyngeal airway volume changes with expansion. Pearson correlation test was utilized to assess the relationship between nasal and pharyngeal volume changes.

**Results:** A total of 17 out of 20 samples had a successful split of the mid-palatal sutures. A significant increase in nasal airway volume (12.0%) was found post-expansion. In addition, a significant increase in linear measurements of the nasal cavity base width in the frontal plane (7.1%) and both the anterior and posterior widths in the transverse dimension (9.4% and 3.4%, respectively) were found. Significant positive correlations were found between airway volumes and increase in width of the maxillary expansion appliance.

**Conclusion:** The effects of maxillary expansion with a MARPE appliance include an increase in nasal cavity volume, but not the nasopharyngeal and the oropharyngeal airway volume. The nasal cavity expands in a triangular pattern in both the frontal and transverse dimensions following orthopedic expansion with the MARPE appliance. Increase in airway volume is a result of the increase in width of the maxillary expansion appliance.

**Keywords:** Sleep apnea, Airway volume, Miniscrew-assisted rapid expansion appliance, Orthopedic expansion, Maxillary transverse deficiency

### INTRODUCTION

A transverse deficiency of the maxilla is a pervasive skeletal problem that can affect almost 25% of the primary dentition population.<sup>[1]</sup> Most clinicians recognize a transverse deficiency when it manifests as a posterior dental crossbite where the posterior maxillary dentition occludes lingually to the mandibular dentition. However, a transverse skeletal imbalance of the maxilla can also present in more nuanced ways such as dental crowding, abnormal incisor inclination, the presence of soft-tissue buccal corridors, or anterior-posterior malocclusions where a narrow maxilla is

This is an open-access article distributed under the terms of the Creative Commons Attribution-Non Commercial-Share Alike 4.0 License, which allows others to remix, transform, and build upon the work non-commercially, as long as the author is credited and the new creations are licensed under the identical terms.

©2022 Published by Scientific Scholar on behalf of APOS Trends in Orthodontics

unable to accommodate the mandibular dentition.<sup>[2]</sup> Once a proper diagnosis is made, the treatment goal is typically to orthopedically expand the maxilla. In pre-pubescent patients, the circummaxillary sutures are still patent and a rapid palatal expander (RPE) is the treatment of choice. As the patient ages, the cranial sutures surrounding the maxilla become increasingly interdigitated which increases the resistance to orthopedic expansion. In adults, the surgically assisted RPE (SARPE) is the gold standard for orthopedic expansion. However, many clinicians and patients shy away from treatment with a SARPE since it necessitates all the surgical cuts of a LeFort I surgical procedure to separate the maxillary palatal halves. In recent years, the miniscrew-assisted RPE (MARPE) has become increasingly popular due to its increased orthopedic effect with the addition of miniscrews or temporary anchorage devices.<sup>[3-7]</sup> The MARPE appliances can be inserted by the orthodontist's chairside, which avoids the need for an invasive surgical-assisted RPE procedure while providing increased orthopedic force that a tooth-borne RPE lacks. Due to the relative novelty of the MARPE appliance, the literature studying its effects on expansion is scarce.

As the role of clinicians and orthodontists changes today, clinicians are increasingly focused on the importance of diagnosing obstructive sleep apnea (OSA) as a part of routine treatment.<sup>[8]</sup> The prevalence of OSA has been reported in the literature to be as high as 37% in men and 50% in women,<sup>[9]</sup> and 7.45% in the pediatric population.<sup>[10]</sup> In addition to the large array of morbidities associated with pediatric OSA, the long-term effects can persist into adulthood. Studies have shown that adults with OSA have an increased risk of developing serious medical issues, such as stroke, hypertension, coronary artery disease, and risk of early death.<sup>[8]</sup> Pediatric patients diagnosed with both a maxillary transverse discrepancy and OSA have demonstrated improvements in apnea-hypopnea index<sup>[11]</sup> and clinical symptoms such as nocturnal enuresis, snoring, excessive daytime sleepiness, and school-related problems after being treated with rapid maxillary expansion appliances.<sup>[12]</sup> With the intimate relationship of maxillary expansion on the upper airway, it would behoove the profession to determine if a commonly performed orthodontic procedure has an impact on the surrounding upper airway.

At present, there are few studies that study the effects of MARPE appliances on airway volume changes.<sup>[11,13-17]</sup> A review and meta-analysis on rapid maxillary expansion and obstructive sleep apnea in children reported that this treatment appeared to be effective but not conclusive.<sup>[11]</sup> The purpose of this study was to investigate the volumetric changes in the nasal and upper pharyngeal airway after MARPE treatment using cone-beam computed tomography (CBCT) imaging. The volumetric changes of the upper airway were divided into three anatomical compartments: The nasal airway, nasopharynx, and the oropharynx. In addition, this study

aims to investigate the pattern of expansion the nasal cavity experiences following treatment with the MARPE appliances.

## MATERIAL AND METHODS

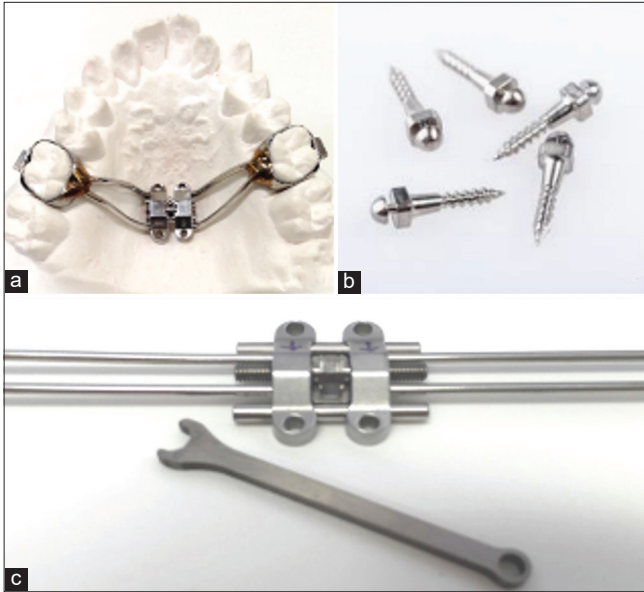
### Sample collection

The protocol of this study was reviewed and approved by West Virginia University Institutional Review Board for human research protection (Protocol #1908679933). Permission was also granted by Wuhan University School of Stomatology to use the records from their institution. A total of 250 records of patients who completed maxillary expansion with the maxillary skeletal expander (MSE) appliance between January 1, 2015, and July 1, 2020, were reviewed. A total of 20 cases met the following inclusion criteria: Complete late mixed or permanent dentition excluding third molars; non-smoker; no gender or race predilection; and complete pre-treatment and post-treatment records, including intraoral scans; and no previous orthodontic treatment. The exclusion criteria included: No previous orthodontic or orthopedic treatment and no craniofacial anomalies. With a sample size of 20, we achieved 80% power for a two-sided test with a significance alpha level of 0.05 based on the effect size of 0.66 (calculated from data). Each subject was given a random identification number, and all protected health information identifiers were removed for de-identification purposes. The final age of the sample ranged from age 8 to 22. The cervical vertebral maturation (CVM) ranged from Stages 2 to 6.

### Appliance design and activation protocol

All patients were treated with the MSE manufactured by BioMaterials Korea, Inc. The MSE appliance is one type of design of the MARPE appliance. It consists of a central expansion screw, which is held in place against or close to the palate. The design of the appliance may vary from patient to patient, but commonly the maxillary first premolar and first molar are pre-fit with orthodontic bands to allow the MSE arms to be soldered to. Four miniscrews are inserted through the guide holes surrounding the expansion screw and seated fully against the metal framework of the MSE appliance [Figure 1]. Each screw is inserted perpendicular and bicortically through the palate for maximum skeletal anchorage. The miniscrews are 1.8 mm in diameter, and although the length varies depending on the anatomical thickness of the patient's palate, a length of 11–13 mm was routinely used.

Every subject began maxillary expansion 2 weeks after the placement of micro implants. Patients were instructed to turn the expansion screw one turn in the morning and one turn in the evening. Maxillary expansion was suspended if patients complained of unbearable pain; if jackscrew was too tight to turn; if one or more micro-implants were loose; and if micro-implants or linkages were wrapped by soft tissue and there was obvious



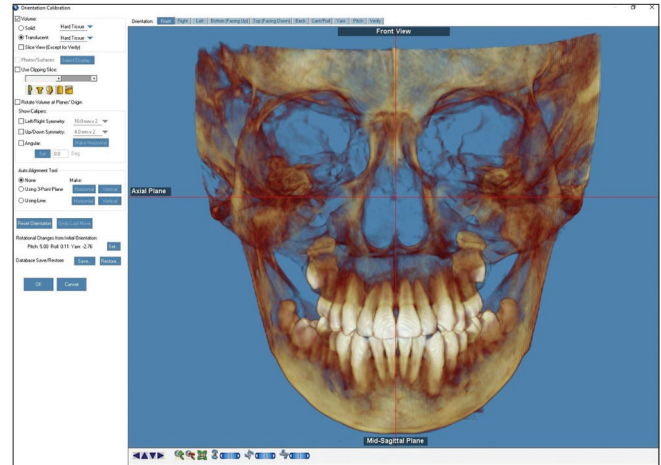
**Figure 1:** (a-c) Maxillary skeletal expander (MSE) manufactured by BioMaterials Korea, Inc.

localized inflammation. Patients were instructed how to activate the expansion and how to flush the palatal region after meals to keep oral hygiene. The number of turns of expansion appliance was recorded and adverse event was reported. The expansion was terminated when 2–3 mm of overexpansion was achieved.

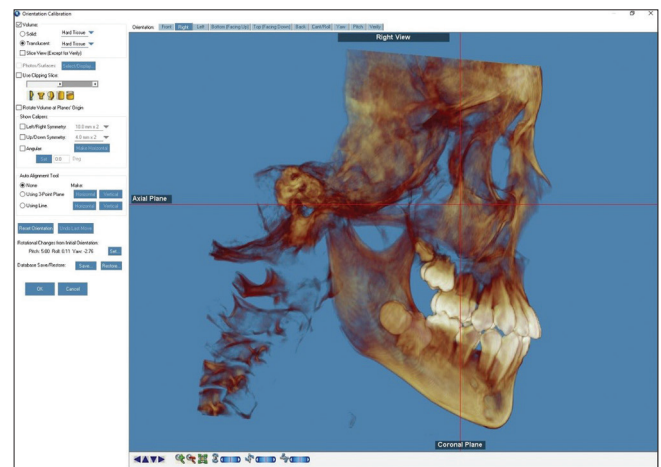
### CBCT analysis

CBCT scans were taken before pre-treatment and immediately after expansion with MSE appliance. The CBCT scans from West Virginia University were obtained with a Gendex GX-DP-700 cone-beam three-dimensional imaging scanner, and the Wuhan University CBCT scans were obtained with a NewTom VGi 9 cone beam (Imola, Italy). The chosen field of view was 17 × 13 cm with a 300 voxel size and 16 bit grayscale. Exposure components were pre-adjusted to the selected field of view: 11.30 s scan time, 85 KV, and 4.0 mA. All patients were scanned in standing supine position, upright head posture, and in maximum intercuspation. The data of each patient were reconstructed with a 0.0 mm slice thickness, and the DICOM images were assessed using the Dolphin imaging software (11.95).

To standardize the image analysis procedure, all CBCT scans were oriented in three planes of space (sagittal, coronal, and transverse). Image orientation was done with the use of the Dolphin imaging software (version 11.95). Sagittal orientation was determined with a line of best fit down the skeletal midline [Figure 2]. Coronal orientation was based on Frankfort horizontal plane from the right lateral perspective. Transverse (axial) orientation was based on a line passing through the furcation of the permanent first molar from the

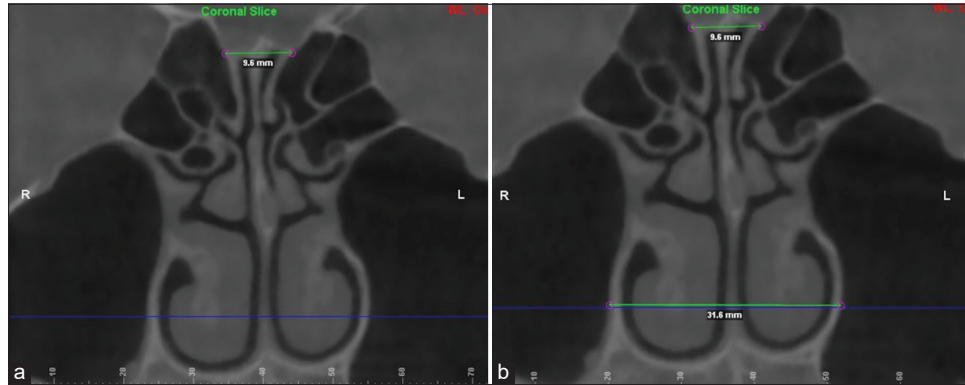


**Figure 2:** Head orientation in the mid-sagittal plane of a CBCT scan.

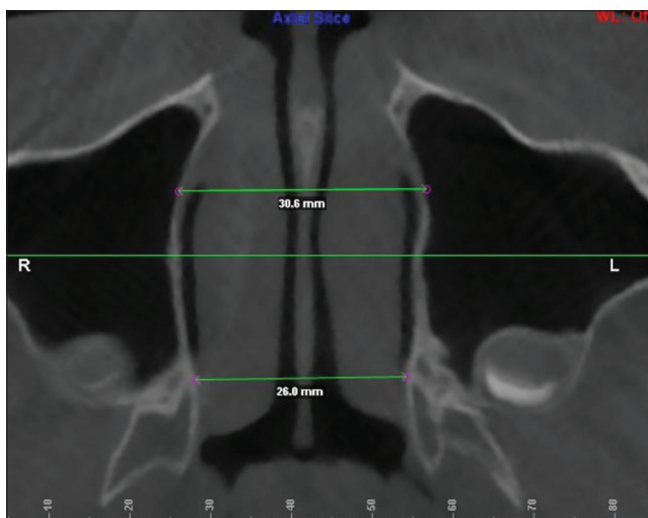


**Figure 3:** Head orientation in the coronal and transverse planes of a CBCT scan.

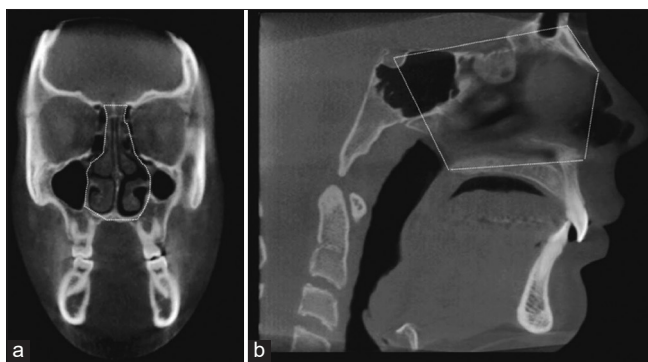
right lateral perspective [Figure 3]. Definition of the airway compartments was adopted from Kavand *et al.*<sup>[16]</sup> to allow for the comparison of results. The upper airway was divided into three compartments in the mid-sagittal plane: Nasal cavity; nasopharynx, and the oropharynx. For the nasal cavity, the sagittal view was defined as the nasal cavity was defined as the airway space bound by the lines connecting sella (S), nasion (N), the tip of the nasal bone, anterior nasal spine, posterior nasal spine (PNS), and back to sella. The frontal view was outlined avoiding the surrounding maxillary, ethmoidal, and sphenoid sinuses [Figures 4-6]. For the nasopharynx: The airway space bound by the lines connecting S, PNS, to the tip of the odontoid process, and back to S. For the oropharynx: The airway space bound by the lines connecting the tip of the odontoid process, PNS, menton, the most anterior-inferior point of the third cervical vertebrae, and back to the tip of the odontoid process [Figure 7].



**Figure 4:** Frontal dimension showing measurements for superior and inferior nasal cavity width. (a) Green line showing measurement. (b) Blue line delineating the tip of the vomer bone.

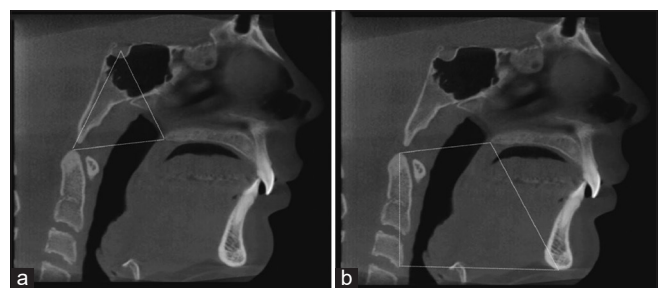


**Figure 5:** Transverse dimension showing measurements for anterior and posterior nasal cavity width at the level of the vomer tip.



**Figure 6:** Boundaries of the nasal cavity in the (a) frontal view; (b) sagittal view.

To determine the pattern of expansion for the nasal cavity following treatment with the MSE appliance, skeletal landmarks of the nasal cavity were defined in the frontal and transverse dimensions. The landmarks chosen for this study

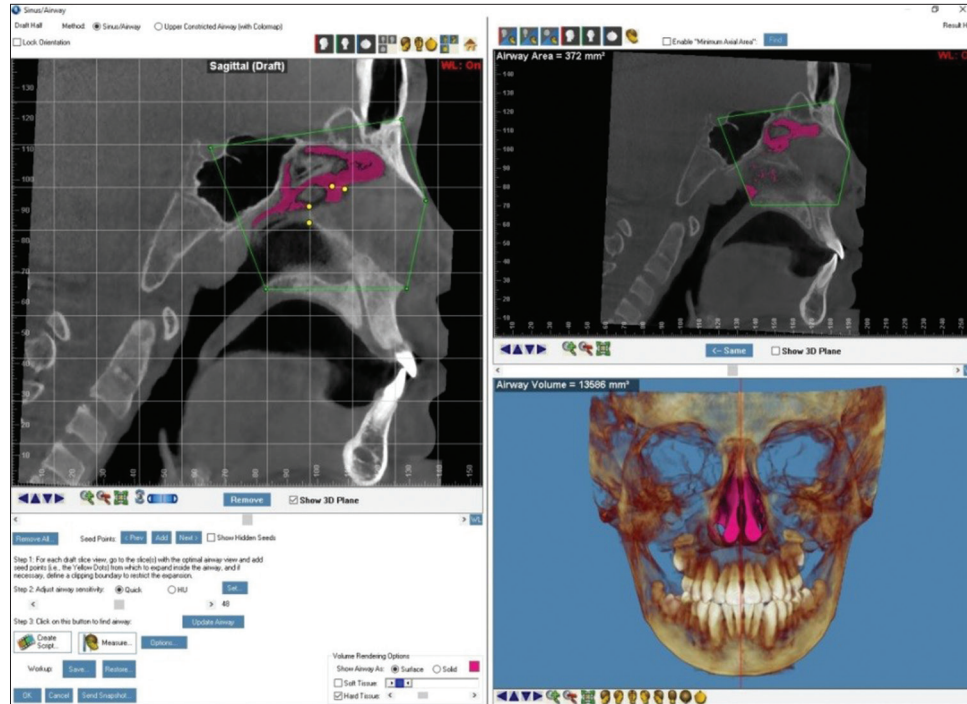


**Figure 7:** (a) Boundaries of the nasopharynx in the sagittal view; (b) Boundaries of the oropharynx in the sagittal view.

were based on easily identifiable and repeatable structures but not currently used in the literature as cephalometric landmarks. For the frontal view: CBCT oriented to view a coronal slice through the landmark of the furcation of the permanent first molar. Superior landmark is defined as the widest point of the frontoethmoid suture. An inferior landmark is defined as the widest point of the wall of the nasal cavity passing through the tip of the vomer. For the transverse view: Orient CBCT axially through the superior tip of the vomer bone. Anterior landmark is defined as the widest point of the nasal cavity anteriorly. Posterior landmark is defined as the widest point between the walls of the pterygoid plates [Figure 8].

### Statistical analysis

All statistical analyses were conducted using SAS (version 9.4, 2013, SAS Institute Inc., Cary, NC). Paired *t*-tests were performed to evaluate nasal and pharyngeal airway volume changes between pre- and post-measurements with the treatment of MARPE appliances. We calculated intraclass correlation coefficients to evaluate the reliability of the measurements. Pearson correlation test was utilized to assess the relationship between nasal and pharyngeal volume changes. All statistical tests were two-sided and  $P < 0.05$  was considered statistically significant.



**Figure 8:** Example of airway volume creation for the nasal cavity. The airway boundary was defined on the cone-beam computed tomography as specified in Figures 6 and 7 with green points and lines. Seed points (yellow dots) were added to the negative space on each draft slice to calculate the airway volume (shown in pink). An airway sensitivity ranging from 20 to 50 was determined based on the examiner's judgment to best fill the negative spaces of the specific airway compartment in question while avoiding any of the surrounding cranial sinuses.

## RESULTS

### Intrarater reliability analysis

To assess the intrarater reliability measurements, pre- and post-expansion measurements for 10 randomly selected subjects were repeated 2 weeks apart. The intraclass correlation coefficient was high for all measurements, indicating a high level of agreement between the two sets of measurements done by the evaluator [Table 1].

### Comparison of pre- and post-expansion measurements on all subjects

Seventeen of the 20 patients had a successful split of the mid-palatal suture following expansion with the MARPE appliance. Two of the three patients who did not have successful splitting of the mid-palatal suture had CVM Stage 5, and the other patient had a CVM of 6.

Significant increase in nasal cavity volume, frontal dimension inferior nasal width in the frontal dimension, nasal anterior width in the transverse dimension, and transverse nasal posterior width were found following expansion [Table 2]. No significant changes were seen for volume changes of the nasopharynx, oropharynx, and frontal nasal superior width.

The nasal cavity volume increased by 12.0% following expansion with the MSE appliance. The percent change of

linear measurement of the nasal cavity is useful to describe the pattern of expansion. In the frontal plane, the inferior nasal width increased by 7.1% post-expansion. In the transverse plane, the anterior nasal width increased by 9.4%, and the posterior nasal width increased by 3.4% post-expansion.

### Correlation between the changes in variables

Pearson's correlation coefficients between the pre- and post-expansion difference of the variables presented in Table 3 showed that there were significant positive correlations between measurements (post-pre) of the nasopharynx and oropharynx volumes ( $r = 0.63$  and  $P = 0.003$ ), nasopharynx volume and frontal nasal inferior width ( $r = 0.55$  and  $P = 0.01$ ), oropharynx volume and frontal nasal inferior width ( $r = 0.49$  and  $P = 0.03$ ), frontal nasal inferior width and transverse nasal anterior width ( $r = 0.63$  and  $P = 0.003$ ), transverse nasal posterior width and frontal nasal inferior width ( $r = 0.46$  and  $P = 0.04$ ), and transverse posterior nasal width and transverse anterior nasal width ( $r = 0.77$  and  $P < 0.0001$ ).

## DISCUSSION

### Effect of maxillary expansion on airway compartments

Significant orthopedic separation of the mid-palatal sutures was found with maxillary expansion with the MSE appliance.

The present study showed significant differences between the pre-treatment and immediately post-treatment airway volumes for the nasal cavity (12.0% increase). These results

agree with the previous studies reported by Smith *et al.*<sup>[18]</sup> and Kavand *et al.*<sup>[16]</sup> Significant increase in nasopharyngeal volume (8.48%) was reported by Yi *et al.* in a recent study.<sup>[22]</sup> No statistically significant changes were observed for the nasopharynx and oropharynx volume following expansion, which agrees with the studies by Zhao *et al.*,<sup>[19]</sup> Smith *et al.*,<sup>[18]</sup> Kavand *et al.*,<sup>[16]</sup> and Pereira-Filho *et al.*<sup>[20]</sup>

**Table 1:** Intraclass correlation coefficient of measurements.

Variables	Intraclass correlation coefficient
Nasal volume pre	0.991
Nasal volume post	0.993
Nasopharynx pre	0.989
Nasopharynx post	0.993
Oropharynx pre	0.999
Oropharynx post	0.998
Nasal width tip pre	0.986
Nasal width tip post	0.993
Nasal width base pre	0.993
Nasal width base post	0.989
Nasal transverse anterior pre	0.996
Nasal transverse anterior post	0.997
Nasal transverse posterior pre	0.985
Nasal transverse posterior post	0.986

**Expansion pattern of the nasal cavity**

Rapid maxillary expansion with conventional tooth-borne RPE and surgical-assisted RPE has been shown to follow a triangular or “V” pattern of expansion. The expansion pattern with the MARPE appliance varied among the subjects in this study. It was thought that since the jackscrew is closer to the center of resistance of the maxilla, the lateral forces applied with appliance activation promote a greater parallel sutural opening in the coronal view. In addition, if the jackscrew is placed more posteriorly along the palate, the lateral forces are applied closer to the pterygoid plates. Since the pterygoid plates are an area of high resistance to expansion,

**Table 2:** Comparison of pre- and post-expansion measurements for all subjects (n=20).

	Pre-treatment		Post-treatment		T (df=19) <sup>a</sup>	P <sup>b</sup> -value
	Mean	SD	Mean	SD		
Nasal volume	16181.9	3257.8	18122.1	4915.7	2.98	0.008**
Nasopharynx	5238.5	2331.8	5926.2	2185.0	1.65	0.12
Oropharynx	16361.2	7249.4	17325.2	7594.1	0.95	0.35
Nasal width tip	7.6	1.5	7.7	1.4	1.43	0.17
Nasal width base	32.5	3.2	34.8	3.0	6.86	<0.0001***
Nasal transverse anterior	28.6	4.4	31.3	4.6	6.10	<0.0001***
Nasal transverse posterior	26.5	2.1	27.4	1.8	3.74	0.001**

<sup>a</sup>T-value from paired *t*-test. df: Degree of freedom. <sup>b</sup>P-value from paired *t*-test. \*P<0.05, \*\*P<0.01, \*\*\*P<0.001

**Table 3:** Pearson’s correlation coefficients between the change (post-pre) variables.

Change (post-pre) variable	Pearson’s correlation coefficients					
	Nasopharynx	Oropharynx	Nasal width tip	Nasal width base	Nasal transverse anterior	Nasal transverse posterior
Nasal volume	0.33	0.40	0.03	0.14	-0.07	-0.18
Nasopharynx	0.15	0.08	0.87	0.56	0.77	0.44
Oropharynx		0.63	-0.06	0.55	0.36	0.31
Nasal width tip		0.003**	0.79	0.01*	0.12	0.18
Nasal width base			0.11	0.49	0.32	0.36
Nasal transverse anterior			0.63	0.03*	0.17	0.11
Nasal transverse posterior				0.06	0.08	-0.02
				0.81	0.75	0.92
					0.63	0.46
					0.003**	0.04*
						0.77
						<0.0001***

<sup>#</sup>P-value from Pearson correlation test. \*P<0.05, \*\*P<0.01, \*\*\*P<0.001

a posteriorly placed jackscrew can promote a more parallel sutural opening compared to a more anteriorly placed tooth-borne RPE. Thus, the pattern of maxillary sutural separation with MSE appliances can vary among patients [Figure 9].

The effect of RME on the surrounding nasal structure is not as widely studied. Tausche *et al.*<sup>[21]</sup> studied the change in nasal volume following surgical-assisted RPE and concluded that the greatest percent change occurred anteriorly at the level of the nasal floor, which matched the “V”-shaped opening of the mid-palatal suture. It is probable that the pattern of nasal expansion is correlated with the shape of the mid-palatal suture opening as the soft-tissue anatomy is intimately related to the skeletal structure. With a tendency toward a more parallel sutural separation with the miniscrew-assisted expansion jackscrew, this research supported the hypothesis that the separation of the nasal cavity also tended to be more parallel.

In the majority of patients with a successful split of the mid-palatal sutures, the only nasal width measurement that showed no significant increase was the superior measurement of the frontal view. The other three nasal width measurements indicated a significant increase following expansion. These results strongly support that the anatomy of the nasal cavity was influenced by orthopedic changes of the palate. However, the pattern of expansion for the nasal cavity appears to be more triangular than parallel. In the frontal plane, the apex of the triangle is situated between the junction of the frontal and ethmoid bones which showed a 1.3% increase in width. The inferior nasal measurement increase is more than 5 times that of its corresponding measurement at a width increase of 7.1%. Similarly, the transverse plane shows a triangular pattern of expansion. The posterior nasal width increased by 3.4%, while a 9.4% change in anterior nasal width increased almost 3 times the posterior width following expansion. This triangular expansion pattern is likely due to the complex bony articulations surrounding the nasal cavity that prevents a parallel separation, unlike what can be observed at the mid-palatal suture. With greater resistance along the cranial base, the change in skeletal nasal

width is restricted more superiorly and posteriorly compared to the inferior and anterior portions of the nasal cavity.

### Correlation among the treatment variables

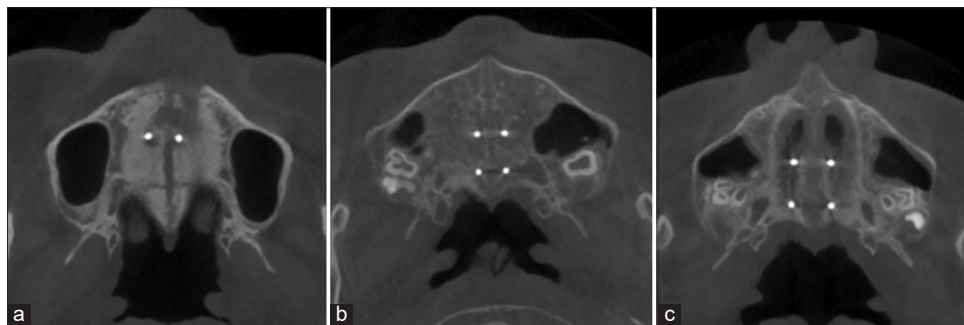
The present study found significant positive correlations between the change in nasopharynx and oropharynx volumes, nasopharynx volume and frontal nasal inferior width, oropharynx volume and frontal nasal inferior width, frontal nasal inferior width and transverse nasal anterior width, transverse nasal posterior width, and frontal nasal inferior width, and transverse posterior nasal width and transverse anterior nasal width. These positive correlations support the hypothesis that the increase in airway volume is a result of the increase in width of the maxillary expansion appliance.

### Clinical implications and limitation of the present study

Rapid maxillary expansion may be a useful adjunct for the treatment of OSA in conjunction with comprehensive orthodontic treatment. The use of a MARPE appliance for maxillary expansion can increase the scope of treatment to young adults which is not possible with convention rapid palatal expansion appliance without using miniscrews as additional anchorage. The increased orthopedic effect with the MARPE appliance can be used in pubertal patients to increase nasal cavity and nasopharyngeal volume.

The present study included patients ranging from 8 to 22. According to the study by McMullen *et al.*,<sup>[23]</sup> the treatment of patients with MARPE appliances is effective in growing and non-growing patients. Although greater skeletal and dental changes were observed in growing patients, a similar ratio of skeletal to dental transverse changes was observed in both groups. Due to the small sample size, the airway response of growing and non-growing patients to maxillary expansion was not studied to determine whether airway response will be greater in growing patients.

The present study also did not determine if the increase in airway volume decreases airway resistance. The present



**Figure 9:** Examples of sutural separation pattern following expansion with the MARPE appliance. (a) “V” separation pattern; (b) parallel separation; (c) reverse “V” separation pattern.

study showed an increase in nasopharyngeal airway but limited changes in the oropharynx. The point of greatest restriction (minimum axial area) for an OSA patient can be located anywhere along the upper airway. Expansion therapy is unlikely to alleviate any sleep apnea symptoms if the minimum axial area is in the oropharynx. As expected, the severity of OSAS also plays a factor in the treatment necessary to resolve symptoms. The standard of care for patients with severe OSAS is a double jaw advancement to open the airway and decrease the resistance to airflow. Future studies could investigate the extent that RME has on mild, moderate, and severe OSAS patients, although the likely effect of expansion on the oropharynx will be limited. Another limitation of this study is the lack of data on airflow dynamics. Perhaps, the most useful method to correlate changes in airway volume and airflow dynamics would be to study a group of OSAS patients prospectively and evaluate both airway volume changes with any observed improvements in airflow with 3D-computational fluid dynamics/fluid-structure interaction.

## CONCLUSION

1. There is a significant increase seen in nasal airway volume (12.0%) following treatment of patients with the MARPE appliance
2. There is a significant increase in linear measurements of the nasal cavity base width in the frontal plane (7.1%) and both the anterior and posterior widths in the transverse dimension (9.4% and 3.4%, respectively)
3. There is no significant difference seen in nasopharynx airway volume following treatment of patients with the MARPE appliance
4. There is no difference observed in oropharynx airway volume following expansion with the MARPE appliance.
5. The nasal cavity expansion pattern is more triangular than parallel in both the frontal and transverse dimensions following expansion with the MARPE appliance.

## Declaration of patient consent

Patient's consent not required as patient's identity is not disclosed or compromised.

## Financial support and sponsorship

Nil.

## Conflicts of interest

There are no conflicts of interest.

## REFERENCES

1. Agarwal A, Mathur R. Maxillary expansion. *Int J Clin Pediatr Dent* 2010;3:139-46.

2. Southard TE, Marshall SD, Allareddy V, Shin K. Adult transverse diagnosis and treatment: A case-based review. *Semin Orthod* 2019;25:69-108.
3. Brunetto DP, Sant'Anna EF, Machado AW, Moon W. Non-surgical treatment of transverse deficiency in adults using micro-implant-assisted rapid palatal expansion (MARPE). *Dental Press J Orthod* 2017;22:110-25.
4. Cantarella D, Dominguez-Mompell R, Mallya SM, Moschik C, Pan HC, Miller J, *et al.* Changes in the midpalatal and pterygopalatine sutures induced by micro-implant-supported skeletal expander, analyzed with a novel 3D method based on CBCT imaging. *Prog Orthod* 2017;18:34.
5. Carlson C, Sung J, McComb RW, Machado AW, Moon W. Micro implant-assisted rapid palatal expansion appliance to orthopedically correct transverse maxillary deficiency in an adult. *Am J Orthod Dentofacial Orthop* 2016;149:716-28.
6. Zong C, Tang B, Hua F, He H, Ngan P. Skeletal and dentoalveolar changes in the transverse dimensions using micro implant-assisted rapid palatal expansion (MARPE) appliances. *Semin Orthod* 2019;25:46-59.
7. Choi SH, Shi KK, Cha JY, Park YC, Lee KJ. Nonsurgical miniscrew-assisted rapid maxillary expansion results in acceptable stability in young adults. *Angle Orthod* 2016;86:713-20.
8. Capdevila OS, Kheirandish-Gozal L, Dayyat E, Gozal D. Pediatric obstructive sleep apnea: Complications, management, and long-term outcomes. *Proc Am Thorac Soc* 2008;5:274-82.
9. Franklin KA, Lindberg E. Obstructive sleep apnea is a common disorder in the population—a review on the epidemiology of sleep apnea. *J Thorac Dis* 2015;7:1311-22.
10. Lumeng JC, Chervin RD. Epidemiology of pediatric obstructive sleep apnea. *Proc Am Thorac Soc* 2008;5:242-52.
11. Machado-Júnior AJ, Zancanella E, Crespo AN. Rapid maxillary expansion and obstructive sleep apnea: A review and meta-analysis. *Med Oral Patol Oral Cir Bucal* 2016;21:e465-9.
12. Villa MP, Rizzoli A, Miano S, Malagola C. Efficacy of rapid maxillary expansion in children with obstructive sleep apnea syndrome: 36 months of follow-up. *Sleep Breath* 2011;15:179-84.
13. Deeb W, Hansen L, Hotan T, Hietschold V, Harzer W, Tausche E. Changes in nasal volume after surgically assisted bone-borne rapid maxillary expansion. *Am J Orthod Dentofacial Orthop* 2010;137:782-9.
14. Hur JS, Kim HH, Choi JY, Suh SH, Baek SH. Investigation of the effects of miniscrew-assisted rapid palatal expansion on airflow in the upper airway of an adult patient with obstructive sleep apnea syndrome using computational fluid-structure interaction analysis. *Korean J Orthod* 2017;47:353-64.
15. Kaban O, Gordon J, Heo G, Lagravère MO. Nasal airway changes in bone-borne and tooth-borne rapid maxillary expansion treatments. *Int Orthod* 2015;13:1-15.
16. Kavand G, Lagravere M, Kula K, Stewart K, Ghoneima A. Retrospective CBCT analysis of airway volume changes after bone-borne vs tooth-borne rapid maxillary expansion. *Angle Orthod* 2019;89:566-74.
17. Nada RM, van Loon B, Schols JG, Maal TJ, de Koning MJ, Mostafa YA, *et al.* Volumetric changes of the nose and nasal airway 2 years after tooth-borne and bone-borne surgically assisted rapid



- maxillary expansion. *Eur J Oral Sci* 2013;121:450-6.
18. Smith T, Ghoneima A, Stewart K, Liu S, Eckert G, Halum S, *et al.* Three-dimensional computed tomography analysis of airway volume changes after rapid maxillary expansion. *Am J Orthod Dentofacial Orthop* 2012;141:618-26.
  19. Zhao Y, Nguyen M, Gohl E, Mah JK, Sameshima G, Enciso R. Oropharyngeal airway changes after rapid palatal expansion evaluated with cone-beam computed tomography. *Am J Orthod Dentofacial Orthop* 2010;137:S71-8.
  20. Pereira-Filho VA, Monnazzi MS, Gabrielli MA, Spin-Neto R, Watanabe ER, Gimenez CM, *et al.* Volumetric upper airway assessment in patients with transverse maxillary deficiency after surgically assisted rapid maxillary expansion. *Int J Oral Maxillofac Surg* 2014;43:581-6.
  21. Tausche E, Deeb W, Hansen L, Hietschold V, Harzer W, Schneider M. CT analysis of nasal volume changes after surgically-assisted rapid maxillary expansion. *J Orofac Orthop* 2009;70:304-17.
  22. Yi F, Liu S, Lei L, Liu O, Zhang L, Peng Q, *et al.* Changes of the upper airway and bone in micro implant-assisted rapid palatal expansion: A cone-beam computed tomography (CBCT) study. *J Xray Sci Technol* 2020;28:271-83.
  23. McMullen C, Al Turkestani NN, Ruellas AC, Massaro C, Rego MV, Yatabe MS, *et al.* Three-dimensional evaluation of skeletal and dental effects of treatment with maxillary skeletal expansion. *Am J Orthod Dentofacial Orthop* 2021. Doi: 10.1016/j.ajodo.2020.12.026.

**How to cite this article:** Ngan P, Song J, Xiang J, He H, Martin CA, Weaver B. Changes in the nasal and pharyngeal airway volume with miniscrew-assisted rapid palatal expansion appliances. *APOS Trends Orthod* 2022;12:262-70.