

Original Article

Tomographic mapping of buccal shelf area for optimum placement of bone screws: A three-dimensional cone-beam computed tomography evaluation

Neeraj Eknath Kolge¹, Vivek J. Patni¹, Sheetal S. Potnis²

Department of Orthodontics and Dentofacial Orthopaedics, ¹Mahatma Gandhi Missions Dental College and Hospital, Navi Mumbai, ²Sinhgad Dental College and Hospital, Pune, Maharashtra, India.



***Corresponding author:**

Neeraj Eknath Kolge,
Department of Orthodontics
and Dentofacial Orthopaedics,
Mahatma Gandhi Missions
Dental College and Hospital,
Navi Mumbai 410209,
Maharashtra, India.

neerajkolge1@gmail.com

Received : 13 March 19


Accepted : 10 June 19

Published : 31 December 19

DOI

10.25259/APOS_20_2019

Quick Response Code:



ABSTRACT

Introduction: Buccal shelf bone screws have become increasingly popular as a preferred method of skeletal anchorage in the mandibular arch. Anatomic variations and clinical experience suggest that width and slope of the bone at buccal shelf vary in different population groups, with some individual variations.

Aims and Objectives: The objective of this study was to evaluate angulation of the bone screw of mandibular buccal shelf area, total bone width, thickness of the cortical bone, and proximity to neurovascular structures.

Materials and Methods: Cone-beam computed tomography scans were used to obtain measurements of the buccal shelf region of 35 patients (18 females, 17 males; mean age, 23.6 years). Measurements were taken at three locations (L1, L2, and L3) and total bone width was measured at two levels from the cemento-enamel junction (CEJ, H1 and H2). Bone screws were virtually placed and their proximity evaluated from digitally traced inferior alveolar neurovascular bundle.

Results: Permissible angulation for placement of buccal shelf bone screw considering the safety distance from the root and avoiding excessive buccal projection to minimize cheek irritation was found to be 74.48 (SD \pm 4.26). Total bone width was maximum at the distobuccal cusp of mandibular second molar (L3H2; 6.40 \pm 1.35) when measured at the level of 8 mm from the CEJ. Bone screws were well within the safety range from causing any iatrogenic damage to the inferior alveolar neurovascular bundle at all the three aforementioned locations.

Conclusion: Thus, area buccal to the mandibular second molar region seems to be the most favorable site for placement of buccal shelf bone screws in Indian patients.

Keywords: Buccal shelf area, Bone screws, Class III correction, Cone-beam computed tomography evaluation

INTRODUCTION

Primary factor to be considered in placing miniscrews is the presence of sufficient bone at the insertion site. Thickness and quality of the bone play a vital role in long-term success of mini implants.^[1,2]

A good cortical bone thickness helps in greater stability due to its higher modulus of elasticity, increased resistance to deformation, and higher load-bearing capacity in clinical situations than trabecular bone.^[3] Hence, determining the thickness of the cortical bone, in turn, can help us in reckoning the stability and success rate of bone screws.

This is an open-access article distributed under the terms of the Creative Commons Attribution-Non Commercial-Share Alike 4.0 License, which allows others to remix, tweak, and build upon the work non-commercially, as long as the author is credited and the new creations are licensed under the identical terms.

©2019 Published by Scientific Scholar on behalf of APOS Trends in Orthodontics

Isolating the ideal placement site for a mini implant or bone screw is planned taking into consideration many local anatomic factors and also biomechanics to be implemented.^[4] The more significant factors for placement of buccal shelf bone screw are total bone width, thickness of cortical bone, and proximity to the nerve bundle.

Mandibular buccal shelf is a widely used insertion site for bone screws and has a higher success rate as compared to interradicular miniscrews.^[5] The recommended sites for insertion are adjacent to the first molar, between first and second molars, and adjacent to the second molars.^[6,7] This wide range of recommendations can be due to lack of studies, investigating this particular area, or due to strong local anatomic variations.

AIMS AND OBJECTIVES

Primary objective

- To evaluate a safety angulation for placement of buccal shelf bone screws.

Secondary objectives

- To evaluate thickness of cortical bone of mandibular buccal shelf area at probable insertion sites.
- To evaluate the proximity of buccal shelf bone screw to the inferior alveolar neurovascular bundle.
- To evaluate the total bone width (buccolingual width) of mandibular buccal shelf area at probable insertion sites.

MATERIALS AND METHODS

Cone-Beam Computed Tomography (CBCT) scans of untreated orthodontic patients (18 females, 17 males; mean age, 23.6 years) consisted the sample of the study. Subjects comprised of patients who had CBCT prescribed as a part of their initial records, no CBCT scans being taken for research purpose only.

Inclusion criteria include patients with no craniofacial pathology or developmental deformity and with a full complement of teeth with completely erupted mandibular second molars.

All CBCT images were taken with a low-dose scanner, Romexis (Planmeca, Helsinki, Finland), using 2 mA, 120 kV (p), and voxel size of 0.37 mm. Images were analyzed using Romexis Viewer (Planmeca, Helsinki, Finland). Three locations were chosen to make the measurements. They were as follows:

- L1 (Level 1): Buccal to the distobuccal cusp of mandibular first molar
- L2 (Level 2): Buccal to the mesiobuccal cusp of mandibular second molar
- L3 (Level 3): Buccal to the distobuccal cusp of mandibular second molar.

Total bone width was measured as the amount of bone in buccolingual direction from the root of mandibular molars to most buccal point of the alveolar bone. It was measured parallel to the occlusal plane [Figure 1]. Measurements were done at three aforementioned (L1, L2, and L3) locations at two levels as follows:

H1 (Height 1): 4 mm from the cementoenamel junction (CEJ)

H2 (Height 2): 8 mm from the CEJ.

Thus, total bone width was assessed at six sites: buccal to the distobuccal cusp of mandibular first molar (L1H1 and L1H2), buccal to the mesiobuccal cusp of mandibular second molar (L2H1 and L2H2), and buccal to the mesiobuccal cusp of the mandibular second molar (L3H1 and L3H2).

Thickness of the cortical bone was measured from the midpoint of the osseous ledge buccal to the mandibular first and second molars (buccal shelf). It was measured parallel to the contour of the buccal root surfaces in a vertical direction [Figure 2]. After proper orientation, thickness of the cortical bone was assessed at three locations (L1, L2, and L3) on each side.

The inferior alveolar nerve was digitally traced using a tracing tool in the software (Romexis Viewer, Helsinki, Finland) [Figure 3]. Bone screw (2 mm × 12 mm, FavAnchor™ Skeletal Anchorage System, India) [Figure 4] was virtually placed at the aforementioned locations. Proximity of the screw to the inferior alveolar nerve was recorded at locations L1, L2, and L3.

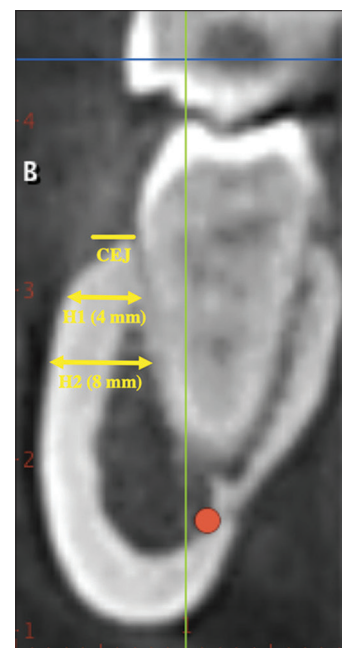


Figure 1: Coronal slice at L3 showing total bone width at H1 and H2.

Permissive clinical limit for angulation of bone screw was evaluated. This was done by constructing a line passing through the buccal and lingual distal cusp tips of the mandibular second molar (Line 1) [Figure 5a]. A 2 mm safety margin was left 5 mm from the CEJ and 4 mm from the most prominent buccal surface (to accommodate the width of buccal tube) [Figure 5b]. A line was constructed joining these two points (Line 2) [Figure 5c]. Angulation between Line 1 and 2 was measured [Figure 5d] to give us the lower limit for placement of bone screw [Figure 5e].

Statistical analysis

The statistical software IBM SPSS statistics 20.0 (IBM Corporation, Armonk, NY, USA) was used for the analyses of the data, and Microsoft Word and Excel were used to generate graphs, tables, etc. A prior power calculation suggested that a minimum sample size of 24 participants would be required.

A paired Student’s *t*-test was used for additional preliminary data analysis to test for differences between the left and right sides. No statistically significant differences were found, so the data were pooled. Reliability of the measurement method was assessed by repeating all measurements twice, 1 month apart on each slice of CBCT.

Descriptive and inferential statistical analyses were carried out in the present study. Results on continuous measurements were presented on mean ± SD. The level of significance was fixed at *P* = 0.05 and any value *P* ≤ 0.05 was considered to be statistically significant.

Analysis of variance (ANOVA) was used to find the significance of study parameters between the groups (intergroup analysis). Further *post hoc* analysis was carried out if the values of the ANOVA test were significant.

RESULTS

Total bone width was thinnest at the distobuccal cusp of mandibular first molar when measured at the level of 4 mm from the CEJ (L1H1; 2.83 ± 0.71) and was thickest at the distobuccal cusp of mandibular second molar (L3H2; 6.40 ± 1.35) when measured at the level of 8 mm from the CEJ [Table 1].

Thickness of cortical bone was least at distobuccal cusp of mandibular first molar (L1; 3.17 ± 1.07) and the most at distobuccal cusp of mandibular second molar

(L3; 4.30 ± 1.19). This confirms good stability of the bone screw at any of the insertion sites [Table 2].

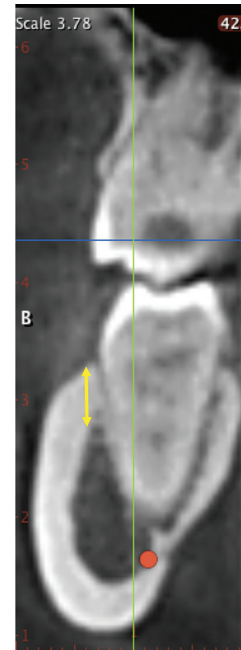


Figure 2: Coronal slice at L3 showing thickness of cortical bone.

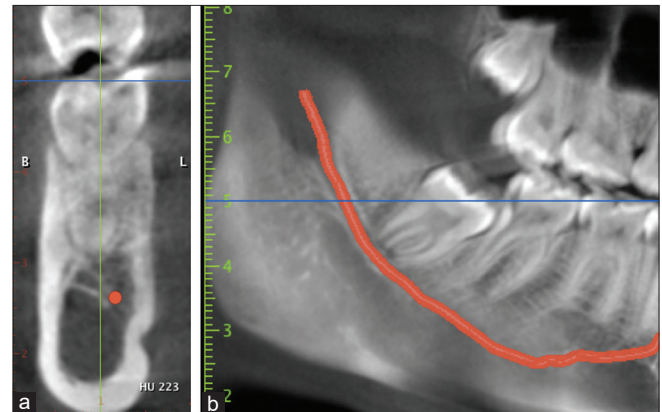


Figure 3: Three-dimensional reconstruction of traced nerve (a) Coronal slice (b) Sagittal slice.



Figure 4: Buccal Shelf Bone Screw (Fav B, FavAnchor™ SAS, India; 2 mm × 12 mm).

Table 1: Total bone width.

| | Total bone width | | | P value |
|----|------------------|------------|------------|---------|
| | L1 | L2 | L3 | |
| H1 | 2.835±0.70 | 3.390±1.10 | 4.267±1.21 | <0.001 |
| H2 | 4.292±0.99 | 5.211±1.36 | 6.408±1.34 | <0.001 |

Table 2: Thickness of cortical bone and proximity to inferior alveolar nerve.

| | Location of insertion | | | P value |
|--------------------------------------|-----------------------|------------|------------|---------|
| | L1 | L2 | L3 | |
| Thickness of cortical bone | 3.17±1.07 | 3.51±1.09 | 4.30±1.19 | <0.001 |
| Proximity to inferior alveolar nerve | 7.316±2.00 | 7.503±1.93 | 7.220±1.98 | <0.001 |

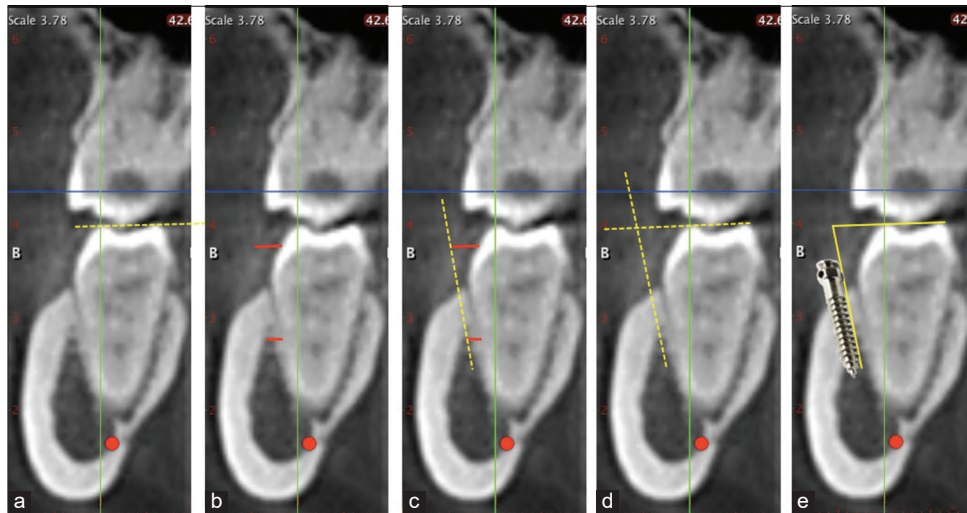


Figure 5: (a-e) Clinical guideline for determination of permissible angulation.

Proximity to inferior alveolar nerve was most at distobuccal cusp of mandibular second molar (L3; 7.22 ± 2.00) and most at mesiobuccal cusp of mandibular second molar (L2; 7.50 ± 1.95). Thus, the implant tip was well within the safety range from causing any iatrogenic damage to the inferior alveolar nerve at all the locations [Table 2].

Permissible angulation for placement of buccal shelf bone screw was determined at the distal cusp of mandibular second molar (L3). It was found to be 74.48 ± 4.26 .

DISCUSSION

Local anatomy and biomechanics (direct or indirect anchorage) are vital in strategic selection of implant placement site. Local anatomy varies from individual to individual though certain insertion sites show reproducible and reliable patterns.

Several studies use CBCT in the assessment of bone quality and quantity to determine the most favorable sites for implant placement and for evaluation of structures at risk.^[7,8] It may be advantageous to image at smaller fields of view, as cortical bone thickness is usually small, thus reducing voxel size and impact of partial volume effect.^[8] As we relied on CBCT scans of existing patients, they were all imaged at a larger field of view.

Our study suggested that there are regions of mandibular buccal shelf in the Indian population, which are superior




Figure 6: Pattern of buccal shelf bone.

to other regions. A pattern [Figure 6] was seen with buccal shelf bone width increasing at more distal and lower levels (maximum being at L3H2 [distal cusp of permanent second mandibular molar 8 mm cervical to the CEJ]).

It was observed that buccal to the distal half of first molar (L1), the buccolingual bone width was thinner, mean values

(2.83 ± 0.71) of which signify that those are incompetent sites for placement of bone screws as the diameter of buccal shelf bone screws available are in range of 2 mm, and a sufficient bone surrounding the bone screw is necessary for stability of the same. Hence, we highly recommend individual 3D imaging and clinically, digital palpation if one intends to place bone screws in this area.

In contrast, buccal shelf bone width at the mandibular second molar exhibited a stable pattern of adequate bone width and thus can be considered a reliable insertion site. Most favorable width is buccal to the distal half of the second molar (L3).

Placement torque is directly correlated to the thickness of the cortical bone^[9] which, in turn, is an important factor in achieving sufficient primary stability. Areas with markedly thick cortical bone will give an excellent primary stability but will result in excessive compression of the bone, leading to delayed failure. In such cases, pre-drilling^[10] is usually recommended. In contrast, areas with thin cortical bone will not provide sufficient primary stability and lead to early failure.

Mandibular buccal bone thickness increases toward the distal aspect; similar findings were seen in our study. However, anatomic extremes can be present in any patient population for that matter. Going by the mean value, it can be said that the most favorable overall anatomic relationship for a buccal shelf bone screw placement in Indian patients is buccal to the distobuccal cusp of mandibular second molar (L3).

Clinical accessibility of this site (L3) with a straight driver is good in most of the patients; a contra-angled insertion instrument can be used in those with limited mouth opening. However, though mean values are a good first step for locating favorable sites, it should be done in cognizance with individual diagnosis and treatment planning.

Evaluation of the relationship of inferior alveolar nerve to the miniscrew showed that its closest proximity was buccal to distal half of second permanent molar ([L3] 7.22 ± 2.00) though sufficient safe distance was present at all three locations (L1, L2, and L3).

CONCLUSION

Thus, the mandibular buccal shelf is a suitable site for orthodontic miniscrews. Area buccal to the mandibular second molar region seems to be the most favorable site for placement of bone screws taking into consideration the reliability, stability, and safety of the procedure.

Area buccal to the first molar seems to be unsuitable, as our study reported with reduced values for bone width in this

area. Still, insertion in this area can be performed for an individual after assessment by 3D imaging or at least digital palpation that the patient has adequate bone.

Declaration of patient consent

Patient's consent not obtained as patients identity is not disclosed or compromised.

Financial support and sponsorship

Nil.

Conflicts of interest

There are no conflicts of interest.

REFERENCES

1. Poggio PM, Incorvati C, Velo S, Carano A. "Safe zones": A guide for miniscrew positioning in the maxillary and mandibular arch. *Angle Orthod* 2006;76:191-7.
2. Kim HJ, Yun HS, Park HD, Kim DH, Park YC. Soft-tissue and cortical-bone thickness at orthodontic implant sites. *Am J Orthod Dentofacial Orthop* 2006;130:177-82.
3. Holmes DC, Loftus JT. Influence of bone quality on stress distribution for endosseous implants. *J Oral Implantol* 1997;23:104-11.
4. Kang S, Lee SJ, Ahn SJ, Heo MS, Kim TW. Bone thickness of the palate for orthodontic mini-implant anchorage in adults. *Am J Orthod Dentofacial Orthop* 2007;131:S74-81.
5. Chang C, Liu SS, Roberts WE. Primary failure rate for 1680 extra-alveolar mandibular buccal shelf mini-screws placed in movable mucosa or attached gingiva. *Angle Orthod* 2015;85:905-10.
6. Baumgaertel S, Hans MG. Buccal cortical bone thickness for mini-implant placement. *Am J Orthod Dentofacial Orthop* 2009;136:230-5.
7. Chang C, Huang C, Roberts WE. 3D cortical bone anatomy of the mandibular buccal shelf: A CBCT study to define sites for extra-alveolar bone screws to treat Class III malocclusion. *Int J Orthod Implantol* 2016;41:74-82.
8. Baumgaertel S. Quantitative investigation of palatal bone depth and cortical bone thickness for mini-implant placement in adults. *Am J Orthod Dentofacial Orthop* 2009;136:104-8.
9. Wilmes B, Rademacher C, Olthoff G, Drescher D. Parameters affecting primary stability of orthodontic mini-implants. *J Orofac Orthop* 2006;67:162-74.
10. Baumgaertel S. Pre-drilling of the implant site: Is it necessary for orthodontic mini-implants? *Am J Orthod Dentofacial Orthop* 2010;137:825-9.

How to cite this article: Kolge NE, Patni VJ, Potnis SS. Tomographic mapping of Buccal Shelf area for optimum placement of bone screws: A three-dimensional cone-beam computed tomography evaluation. *APOS Trends Orthod* 2019;9(4):241-5.