


Experts Corner

Interdisciplinary treatment in the digital era

Kelvin WenChung Chang

Department of Orthodontics, National Taiwan University Hospital, Taipei, Taiwan.



***Corresponding author:**


Kelvin WenChung Chang
Department of Orthodontics,
National Taiwan University
Hospital, Taipei, Taiwan.

kelvinwchang@gmail.com

Received: 18 July 2022
Accepted: 20 July 2022
Epub Ahead of Print: 03 August 2022
Published: 05 August 2022

DOI
10.25259/APOS_126_2022

Quick Response Code:



ABSTRACT

In the digital era today, there are various new technologies could be applied to improve our collaboration and achieve a satisfied treatment outcome. While taking advantage of CAD/CAM technology, the traditional workflow can be simplified, altered, or reversed. Interdisciplinary treatment in the digital era is full of imagination and creativity!

Keywords: Interdisciplinary treatment, Virtual model setup, CAD/CAM, 3D Printing, Digital Orthodontics

INTRODUCTION

To achieve successful teamwork, comprehensive communication between specialties is key. In the digital era today, various new technologies could be applied to improve our collaboration and achieve a satisfactory treatment outcome. With the assistance of digital images, we can see those we cannot see before. With the virtual model setup, we can foresee the possible treatment outcome. Hence, it will be easier to reach a consensus among all members before we start the complicated treatment. With computer-aided design and manufacturing (CAD/CAM) technology, we can transfer our design from the computer to clinical practice. With interdisciplinary treatment combined with new technologies, all the team members can take advantage of digital imaging and CAD/CAM technology to enhance our traditional workflow more accurately and efficiently.

THE ERA OF DIGITAL DENTISTRY

With the assistance of new technologies, all the data can be acquired in a digital format. The patients' photos can be captured with a digital camera in two dimensions or three dimensions. The traditional dental plaster models can be replaced with digital models from intraoral scanners or desktop scanners. Besides the two-dimensional radiographs, we can realize the crown, root, and bone relations from computerized tomography.^[1,2]

Another popular technology in dentistry is the CAD/CAM application. In the aspect of a CAD application, there are plenty of software packages that are customized for specific dental needs, such as restorative dentistry or dental implantology. In the orthodontic field, the software packages usually provide the function of model analysis, virtual orthodontic setup, and digital indirect bonding planning.^[3-5] Following the completion of the previous design, the virtual model can be exported and becomes a physical model or imported to another software for a specific orthodontic appliance design. In the aspect of CAM application, subtractive manufacturing, such as CNC precision milling machines, has been well developed in the application of dental restoration for decades.^[6] In the orthodontic field, additive manufacturing (3D printing technology) becomes popular in recent years.^[7] In addition to the improvement of the 3D

This is an open-access article distributed under the terms of the Creative Commons Attribution-Non Commercial-Share Alike 4.0 License, which allows others to remix, transform, and build upon the work non-commercially, as long as the author is credited and the new creations are licensed under the identical terms.

©2022 Published by Scientific Scholar on behalf of APOS Trends in Orthodontics

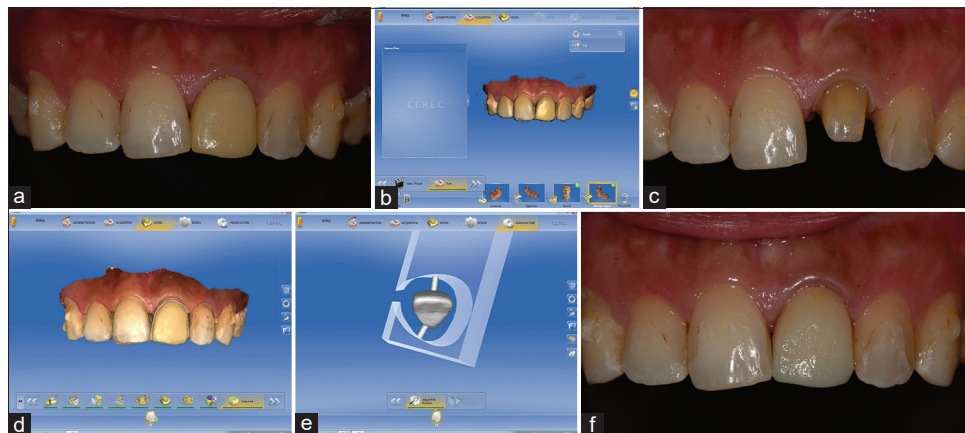

Figure 1: Operation procedures (Designed on Sirona CEREC 4.6.1). (a) Initial photo. Discoloration of the temporary crown. (b) Scan and save the present shape. (c) Scan the tooth abutment. (d) “Bio-Copy” mode to transfer the previous shape to the new design. (e) Milling process. (f) A new provisional crown. The shade was changed, but the shape was not.

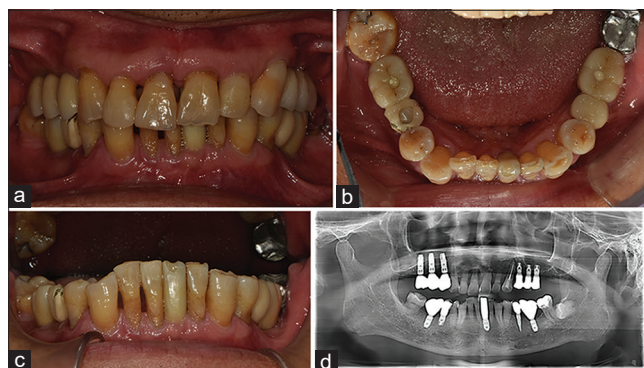


Figure 2: Initial records. (a-c) Intraoral photos. (d) Panoramic radiograph. Ten dental implants noted, including one lower incisor implant.

printing technology, there are various materials developed to fit the specific needs of different appliances in orthodontics.

For the interdisciplinary treatment, Dr. Vincent G. Kokich established comprehensive guidelines for us to follow.^[8] There are: (1) Generate realistic treatment objectives, (2) create the vision, (3) identify who will correct periodontal defects, (4) position teeth to facilitate ideal restorative dentistry, and (5) consider implants to facilitate difficult tooth movement. In the digital era, with the assistance of digital imaging and CAD/CAM technology, we can improve or modify some of the guidelines from traditional workflows to digital ones. For Point 2, now, we can create the vision with a virtual model setup. In the digital mode, we can generate different treatment options on the software easily instead of reproducing the second copy of the plaster model. With the integration of computed tomography image with the oral scan, this virtual model setup can reveal the root conditions covered by bone. It will make the simulation closer to the ideal and practical situation at the same time. For Point 4, the prosthodontist

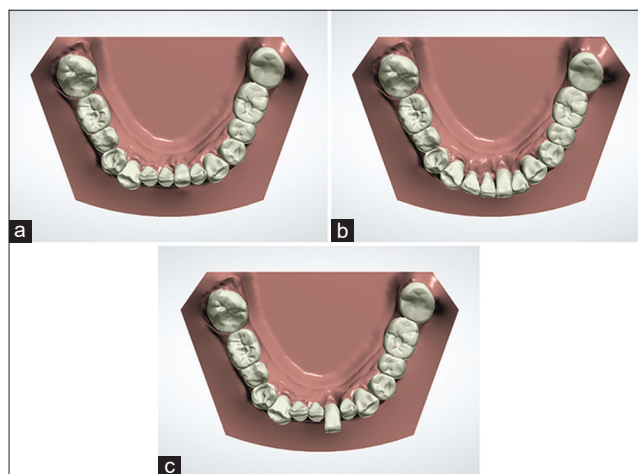


Figure 3: Orthodontic diagnostic setup (Designed on 3Shape OrthoAnalyzer). (a) Initial model. The six front teeth were segmented for the preparation of virtual setup. (b) Setup model. The six front teeth were moved forward and well aligned. (c) The left central incisor was left in the planned position and the other teeth were moved back to their initial sites.

and orthodontist can communicate with each other through the simulation and realize the specific needs of different professions. For Point 5, after the virtual orthodontic tooth movement is planned, the surgeon can place the implants in the ideal position before the completion of orthodontic treatment. Meanwhile, the surgical guide fabricated with the digital workflow provides convenience with high accuracy.^[9]

PROVISIONAL CROWN

For adult orthodontic patients, the dental prosthesis which is ill-fitted or in the wrong shape should be replaced with provisional crowns before the orthodontic treatment

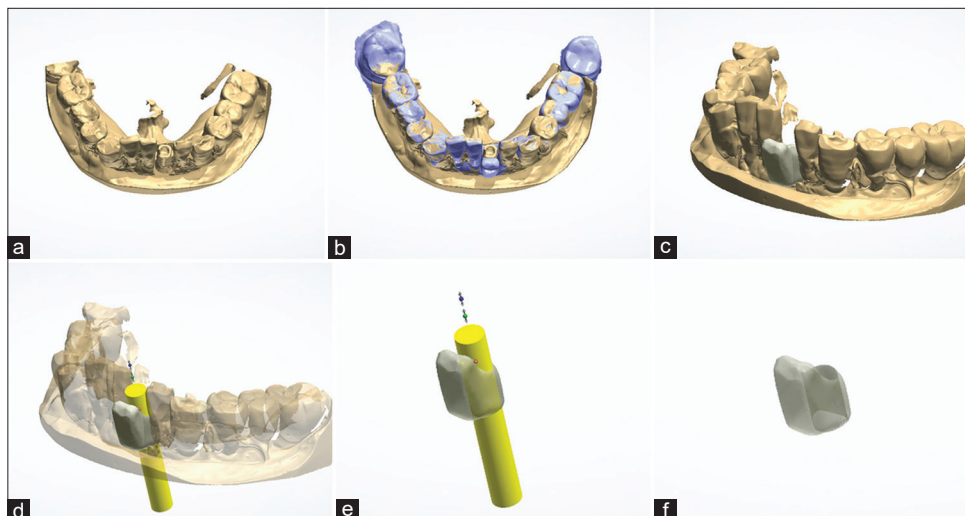

Figure 4: CAD procedure of provisional crown (Designed on 3Shape Dental System). (a) The scan model of 31 implant impression. (b) Superimposition of the scan model and the planned model. (c) The planned final crown position of tooth 31 was transferred accurately to the 31 implant fixture on the scan model. (d-f) Designing the implant supported provisional crown.

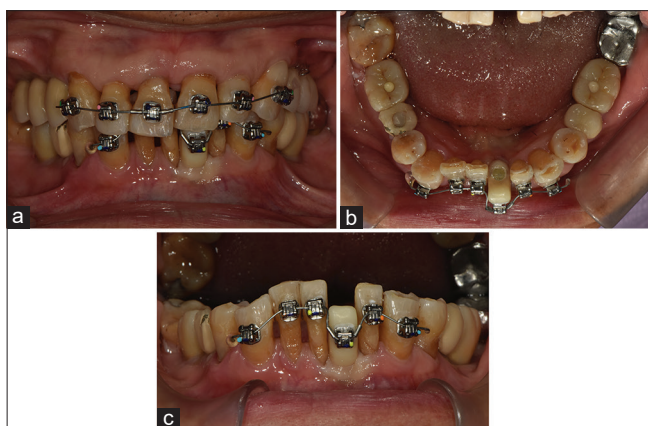


Figure 5: Placement of provisional crown and orthodontic appliances. (a) Frontal view. Localized orthodontic treatment was performed because those implants that supported posterior prostheses were not planned to be changed. (b) Lower occlusal view. The implant-supported provisional crown was an absolute anchorage for the lower incisor's proclination. (c) Frontal view of the lower dentition. The vertical height of the provisional crown was determined by the orthodontic simulation.

started. With the assistance of CAD/CAM technology, the provisional crown is designed on computer software and the morphology is modified according to the original tooth axis. Then, it can be fabricated by milling or 3D printing.

In the digital workflow, controlling the morphology of the provisional crown becomes flexible and easy. If the present morphology of the crown would be maintained, we can scan and save the original shape of the crown. During the design process, we can take advantage of the copy mode to duplicate the original shape to the new design. By this

method, the new prosthesis can be identical to the old one. Moreover, this design process is even easier than building a new one from zero.

Provisional crown replacement without changing the shape

Case 1

This 23-year-old female patient complained of the darkening of her temporary crown in the upper left central incisor during her Invisalign treatment. In order not to interrupt her following aligner treatment, the morphology and size of this newly replaced provisional crown cannot be changed. With the assistance of CAD/CAM technology, this digital workflow is simple and fast [Figure 1].

Integration of virtual orthodontic setup into provisional crown design

Case 2

This 65-year-old patient was referred by the prosthodontist to correct his anterior crowding and deep overbite. Besides multiple posterior implants, the lower left central incisor was an implant-supported crown as well [Figure 2]. Usually, we may bypass the unmovable crown (like an ankylosed tooth or dental implant) if the tooth position is not favorable for the orthodontic tooth movement. We solve this obstacle at the end of orthodontic treatment. With the assistance of orthodontic simulation [Figure 3], the realistic and possible treatment outcome can be seen before we start. Therefore, the traditional treatment sequence could be reversed. The implant crown can be replaced before the orthodontic

treatment. The provisional crown can be designed and placed in the final position. Particularly, this “pioneer” is an absolute anchorage for those teeth that are still on the “start line” [Figures 4 and 5].

DENTAL IMPLANT

Usually, we place the dental implant after the orthodontic treatment is complete or almost complete. However, in some mutilated dentitions with multiple missing posterior teeth, the timing of dental implant placement becomes crucial. If we can place the dental implant as early as possible, such as in the early stage of orthodontic treatment or even before the orthodontic treatment, this early implant prosthesis can

provide stable posterior support, improve chewing efficiency, and be an absolute anchorage to assist orthodontic tooth movement.

Integration of virtual orthodontic setup into dental implant design

Case 3

This 28-year-old female patient complained of poor chewing efficiency on her right side. Mobility of tooth 48 was noted when it was the anchorage for tooth 44 and 45 retractions. The lower dental midline deviated to left 3 mm [Figure 6]. The orthodontic treatment plan was (1) correction of

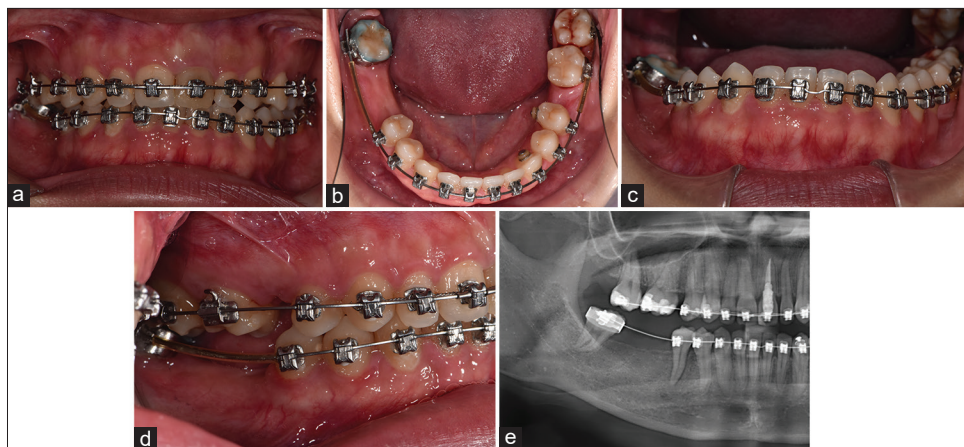


Figure 6: Records taken before 46 implant placements. (a-d) Intraoral photos. (e) Panoramic radiograph.

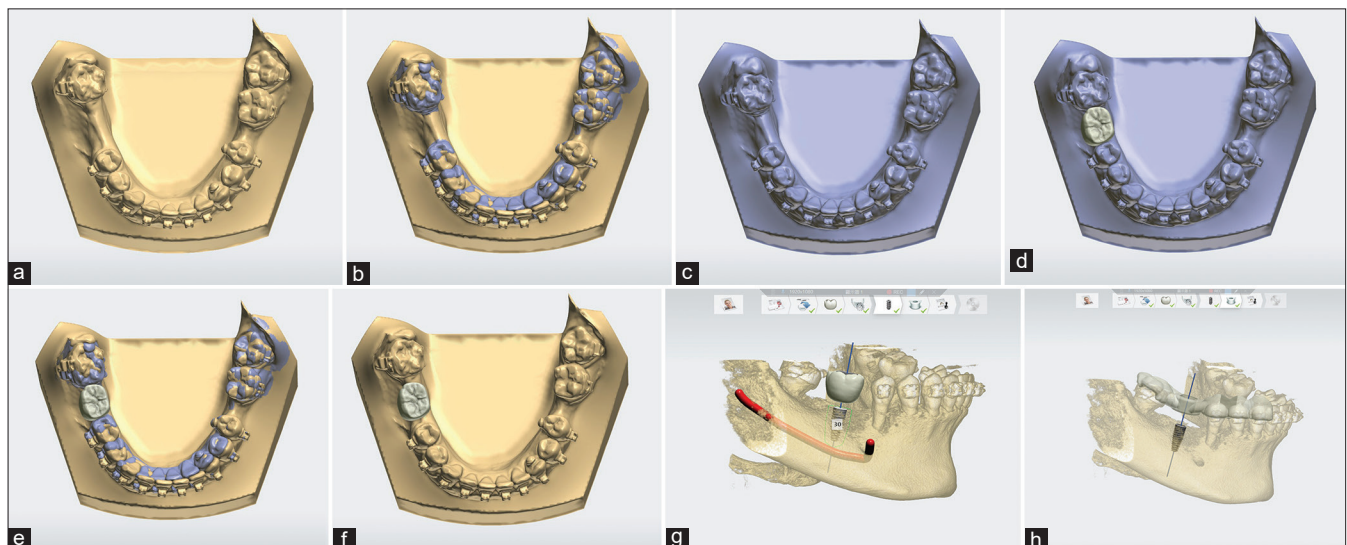


Figure 7: Workflow of 46 implant design (Designed on 3Shape Implant Studio). (a) Import lower surface scan. Original model exported from orthodontic software (b) Superimposition of models. (c) Import lower pre-preparation scan. Orthodontic setup model exported from orthodontic software. (d) Anatomy design. The implant crown was designed on the orthodontic setup/final model. (e) Superimposition of models. (f) Anatomy design. The implant crown design was back to the original/present model. (g) Scan alignment with computed tomography and implant planning. (h) Surgical guide design.

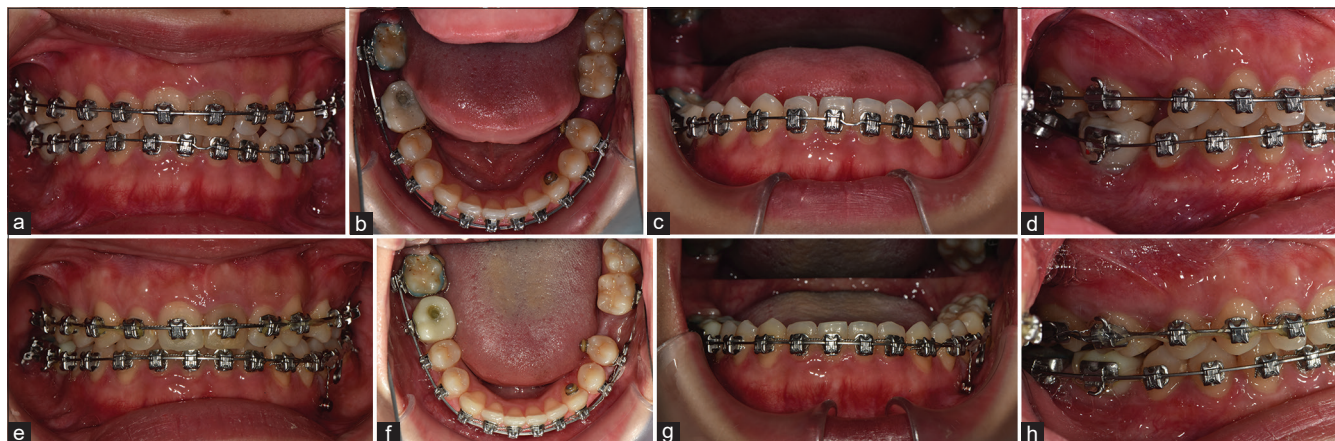


Figure 8: Treatment progress photos. (a-d) Placement of 46 provisional crowns and tubes. This implant-supported temporary crown was the anchorage for 48 protraction, premolars retraction, and incisors intrusion. (e-h) Treatment goals achieved. Lower midline was corrected. The third molar was protracted. Lower occlusal cant was improved.

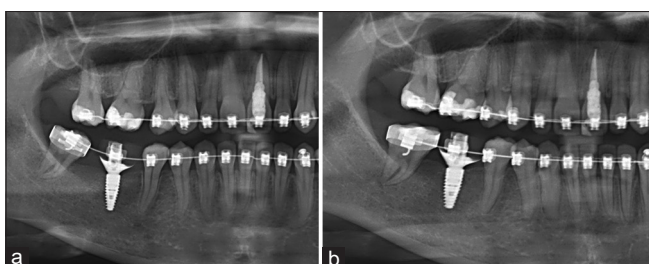


Figure 9: Panoramic radiograph. (a) After 3 months of the dental implant insertion, a good osteointegration around the fixture was obtained. The provisional crown was loaded thereafter. (b) The lower right premolars were retracted and the lower right third molar was protracted with good periodontal health.

the lower dental midline, (2) closure of 47 space by 48 protraction, and (3) preservation of 46 space for the implant. With the assistance of orthodontic simulation, the unfinished orthodontic tooth movement can be accomplished on the software. Then, this final position can be exported and integrated into the implant design. The implant position was determined by the final position from the orthodontic setup model. The surgical guide was determined by the present tooth position to fit the real clinical situation [Figure 7]. With this early implant, the insufficient vertical support on the right side can be increased immediately. The remaining orthodontic tooth movement can be accomplished through this absolute anchorage [Figures 8 and 9]. The patient herself was satisfied with the improvement in chewing efficiency.

CONCLUSION

In digital dentistry, each specialty has developed its digital workflows. Usually, they are operated on specific and packaged software. The software operation interface is designed in a fixed procedure to guide the users step by step. It is simple and

convenient for the application of one single purpose. There are plenty of application software provided by the dental suppliers, such as aligner design software, the crown and bridge design software, and the dental implant design software, respectively customized for orthodontists, restorative dentists, and oral surgeons. However, this is not convenient when treating complicated cases! To provide multidisciplinary solutions for adult orthodontic patients, restorative dentistry and dental implant might be included in the comprehensive treatment plan. While taking the digital workflow in the interdisciplinary treatment, the virtual orthodontic setup is the bridge to connect with the other specialties. Through this integration, the vision of the treatment can be created and the complicated multidisciplinary treatment can be improved by reduced treatment time, greater patient comfort, better accuracy, and higher predictability. Interdisciplinary treatment in the digital era is full of imagination and creativity!

Declaration of patient consent

The authors certify that they have obtained all appropriate patient consent.

Financial support and sponsorship

Nil.

Conflicts of interest

There are no conflicts of interest.

REFERENCES

1. Vandenberghe B. The crucial role of imaging in digital dentistry. *Dent Mater* 2020;36:581-91.
2. Vandenberghe B. The digital patient imaging science in

- dentistry. *J Dent* 2018;74 Suppl 1:S21-6.
3. Francisco I, Ribeiro MP, Marques F, Travassos R, Nunes C, Pereira F, *et al.* Application of three-dimensional digital technology in orthodontics: The state of the art. *Biomimetics* 2022;7:23.
 4. Vaid NR. Up in the air: Orthodontic technology unplugged! *APOS Trends Orthod* 2017;7:1-5.
 5. Christensen LR. Digital workflows in contemporary orthodontics. *APOS Trends Orthod* 2017;7:12-8.
 6. Sulaiman TA. Materials in digital dentistry a review. *J Esthet Restor Dent* 2020;32:171-81.
 7. Groth C, Kravitz ND, Shirck JM. Incorporating three-dimensional printing in orthodontics. *J Clin Orthod* 2018;52:28-33.
 8. Kokich VG. Adult orthodontics in the 21st century: Guidelines for achieving successful results. *World J Orthod* 2005;6:14-23.
 9. Scherer MD. Presurgical implant-site assessment and restoratively driven digital planning. *Dent Clin North Am* 2014;58:561-95.

How to cite this article: Chang KW. Interdisciplinary treatment in the digital era. *APOS Trends Orthod* 2022;12:71-6.