



Original Article

## Comparison between orthodontist, general dentist, and layperson in the perception of pink esthetics on smile: A cross-sectional study

Nivedita Sharma<sup>1</sup>, Sridhar Kannan<sup>2</sup>, Nitin Arora<sup>1</sup>, Ashish Kumar Singh<sup>1</sup>, Abhita Malhotra<sup>1</sup>, Panchali Batra<sup>3</sup>

<sup>1</sup>Department of Orthodontics and Dentofacial Orthopedics, Manav Rachna Dental College, Faridabad, Haryana, India, <sup>2</sup>Department of Orthodontics and Dentofacial Orthopedics, Sudha Rustagi College of Dental Sciences and Research, Faridabad, Haryana, India, <sup>3</sup>Department of Orthodontics, Jamia Millia Islamia University, New Delhi, India.



**\*Corresponding author:**


Panchali Batra,  
Department of Orthodontics,  
Jamia Millia Islamia University,  
New Delhi, India.

[panchali.batra@gmail.com](mailto:panchali.batra@gmail.com)

Received: 12 January 2022  
Accepted: 26 January 2022  
Epub Ahead of Print: 29 April 2022  
Published: 16 September 2022

DOI  
10.25259/APOS\_9\_2022

Quick Response Code:



### ABSTRACT

**Objectives:** Smile designing has become an essential part of dental training and a beautiful smile not only adds to the esthetics of the face but also conveys emotions and augments the self-esteem of an individual. A beautiful smile is achieved by well-balanced pink and white esthetics. This study was designed to evaluate the difference in perceptions of orthodontists, general dentists, and laypersons to alterations in gingival characteristics on smile.

**Material and Methods:** Smile images were modified intentionally to obtain the desired variations in gingival features such as color and contour of free gingival margins, inflammation, pigmentation, gingival margins with or without recession, zenith, and interdental papilla. A total of 51 images were rated by orthodontists, general dentists, and laypersons using Q sort methodology.

**Results:** Variations in the position of free gingival margin with recession was most negatively ranked gingival factor by orthodontists, general dentists, and laypersons followed by variations in the position of interdental papilla. Position of free gingival margin without a recession, color changes due to pigmentation, and inflammation were moderately ranked. Control images and altered gingival zenith images were most positively ranked. Bilateral changes were perceived more readily compared to unilateral in factors such as a black triangle, zenith position, pigmentation, inflammation, and recession.

**Conclusion:** Orthodontists seem to be less tolerant in their evaluations in comparison to general dentists and laypersons. The findings of this study point toward a crucial fact that smile designing should focus on parameters that are perceived readily by the public in general.

**Keywords:** Smile perception, Gingival alterations, q sort, Laypersons, General dentists, Orthodontists, Pink esthetics

### INTRODUCTION

The mouth and eyes work in conjunction for effective communication. A beautiful smile not only adds to the esthetics of the face but also conveys emotions and participates in the self-esteem of an individual.<sup>[1,2]</sup> This is the reason that smile designing has become an essential part of dental training and needs the expertise of an orthodontist, periodontist, prosthodontist, endodontist, and at times maxillofacial or plastic surgeons. Both hard- and soft-tissue factors must be taken into consideration while designing a beautiful smile.<sup>[3-9]</sup> Esthetic preferences to a particular component of a smile may vary and be influenced not only by ethnological and racial

This is an open-access article distributed under the terms of the Creative Commons Attribution-Non Commercial-Share Alike 4.0 License, which allows others to remix, transform, and build upon the work non-commercially, as long as the author is credited and the new creations are licensed under the identical terms.  
©2022 Published by Scientific Scholar on behalf of APOS Trends in Orthodontics

differences but also by factors such as age, sex, education status, economic status, and geographical location.<sup>[10-12]</sup>

Many studies have evaluated how alterations in hard-tissue factors affect smile esthetics and whether there is a difference in the perception of orthodontists, general dentists, and laypersons to these alterations;<sup>[13-17]</sup> However, very few studies have focused on the gingival factors and the impact of altered gingival esthetics.<sup>[18-21]</sup> To the best of our knowledge, only one study has evaluated the impact of various gingival characteristics alterations on smile esthetics as perceived by laypersons,<sup>[9]</sup> but the perception of general dentists and orthodontists to these altered gingival characteristics still needs to be evaluated. It is important to know the difference in perception among the three groups, and how the level of training can influence the perception. While designing a pleasing smile, a balance should be struck, keeping in mind the perceptions of orthodontists, general dentists, and laypersons. The purpose of this study was to evaluate the difference in perceptions of orthodontists, general dentists, and laypersons to alterations in gingival characteristics and to evaluate the extent to which the three groups of evaluators overlook these changes. We also aimed to rank the gingival characteristics that are most negatively and most positively marked by the three groups of evaluators.

## MATERIAL AND METHODS

Institutional ethical clearance (MRDC/IEC/2017/01) was obtained from the university before commencing the survey and written informed consent was taken from all the evaluators. The study was conducted over 5 months, and various dental colleges/hospitals of the region were visited for the collection of data.

### Model selection and image manipulation

A close-up frontal smile of a 25-year-old female with no history of orthodontic or restorative treatment was selected for the study [Figure 1]. The smiling photograph was chosen as it was pleasing, fulfilled to a large extent, the previously mentioned characteristics of a balanced smile,<sup>[22]</sup> and the gingival factors to be evaluated were visible during her social smile. The smile photograph was cropped in Adobe PhotoshopCS2 so that only the lips, the tip of the nose, and the mentolabial sulcus were visible to reduce any distractions. The photograph was then compressed so that the measurements made clinically and on printed photographs were similar, taking maxillary central incisor as the reference point. The smile image was then modified intentionally to obtain the desired variations in gingival features [Supplemental File, Factors 1-7]. Forty-nine modifications were produced and two photographs of an original smile [Figure 1] were added to check for the reproducibility of the results. Thus, a total of

51 images were produced [Figures 2-8]. These final images which were digital files were then professionally printed in the size of 3.5 × 5 inches.

### Selecting the evaluators

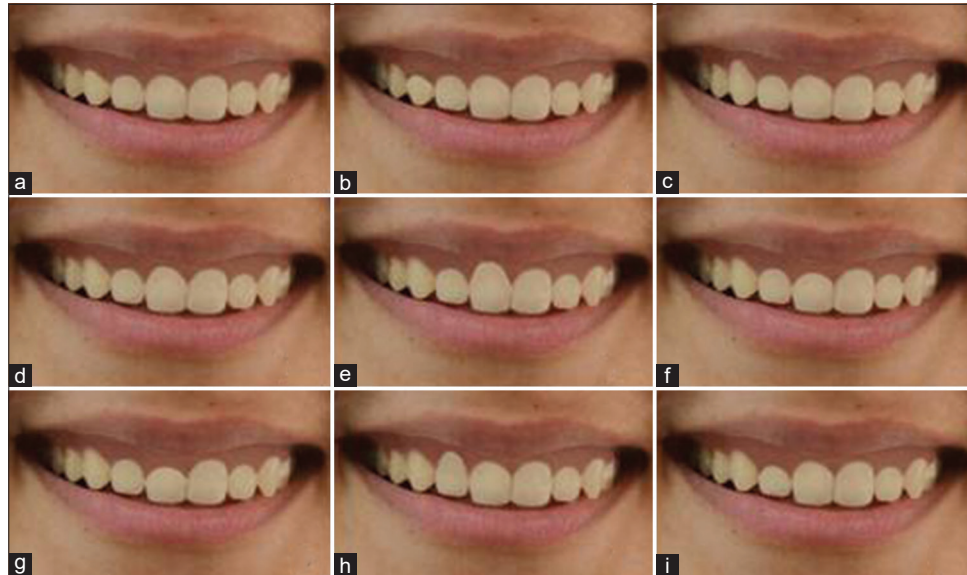
A total of 150 evaluators performed the study (70 men and 80 women). The evaluators consisted of 50 orthodontists, 50 general dentists, and 50 laypersons. A sample size of 50 each was taken because, by a Q Sort method, participants' viewpoints can be shown effectively even with a smaller participant group.<sup>[23]</sup> The laypersons consisted of patients visiting the dental OPD of the institute and students enrolled in various courses in the university. The evaluators had at least intermediate-level qualifications and a complete or an incomplete college degree. It was assured that none of the evaluators in this group had any previous dental affiliation to reduce bias. The general dentists and orthodontists were faculty members visiting various dental colleges of the region and with a minimum of 5 years of experience. General dentists were graduates in dentistry who had not pursued their postgraduation in any specialty of dentistry. The participants' ages were between 22 and 50 years. Basic information such as ethnicity, education, and socioeconomic status of the evaluator was also gathered.

### Q-sort protocol

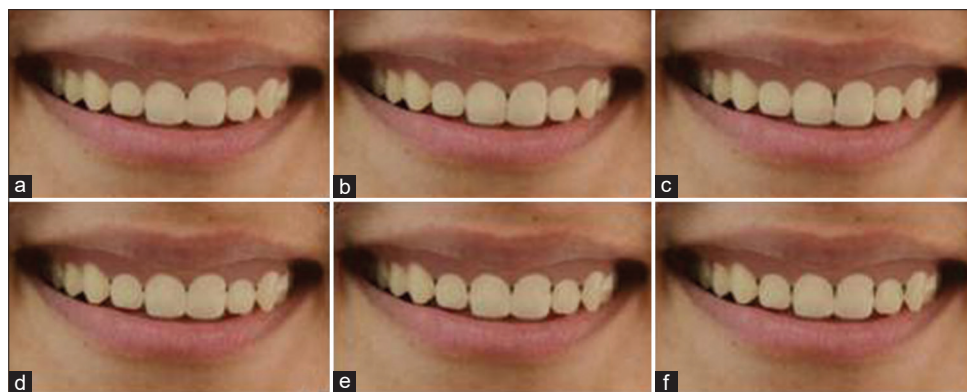
All the evaluators were briefed about the survey without unveiling the changes that had been done in the images and were asked to evaluate the photographs using a forced Q-sort technique whereby the evaluators are forced to put a defined number of photographs in each column.<sup>[23]</sup> An 11-point scale where ranking values ranged from -5 to +5, where -5 denoted the least attractive photograph and +5 denoted the highly attractive photograph was used [Figure 9]. The methodology as described previously was used.<sup>[9]</sup> The average time taken by evaluators to complete the survey was approximately 20 minutes.

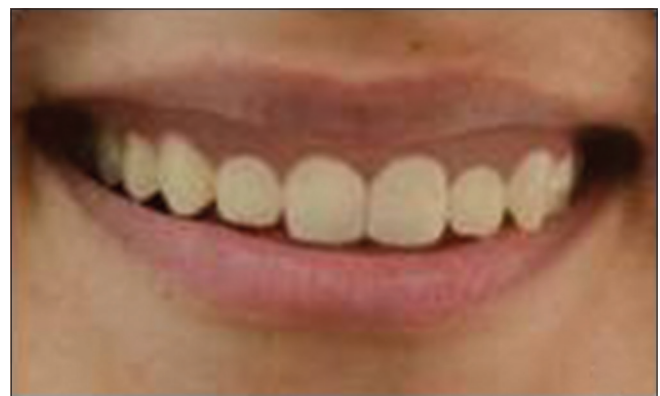

Figure 1: (ct) Control image.



**Figure 2:** Variations in the position of free gingival margin without recession. (a) Unilateral reduction of Free Gingival Margin of canine up to the level of lateral incisor, (b) Unilateral reduction of Free Gingival Margin of canine below the level of lateral incisor, (c) Unilateral increase in the Free Gingival Margin level of canine from the central incisor, (d) Unilateral increase in the Free Gingival Margin level of the central incisor by 1 mm from canine, (e) Unilateral increase in the Free Gingival Margin level of the central incisor by 2 mm from canine, (f) Unilateral reduction of Free Gingival Margin of the central incisor up to the level of lateral incisor, (g) Unilateral reduction of Free Gingival Margin of the central incisor below the level of lateral incisor, (h) Unilateral increase in the Free Gingival Margin of lateral incisor above the level of canine and central incisor, (i) Unilateral reduction of Free Gingival Margin of lateral incisor by 2 mm below the level of canine.

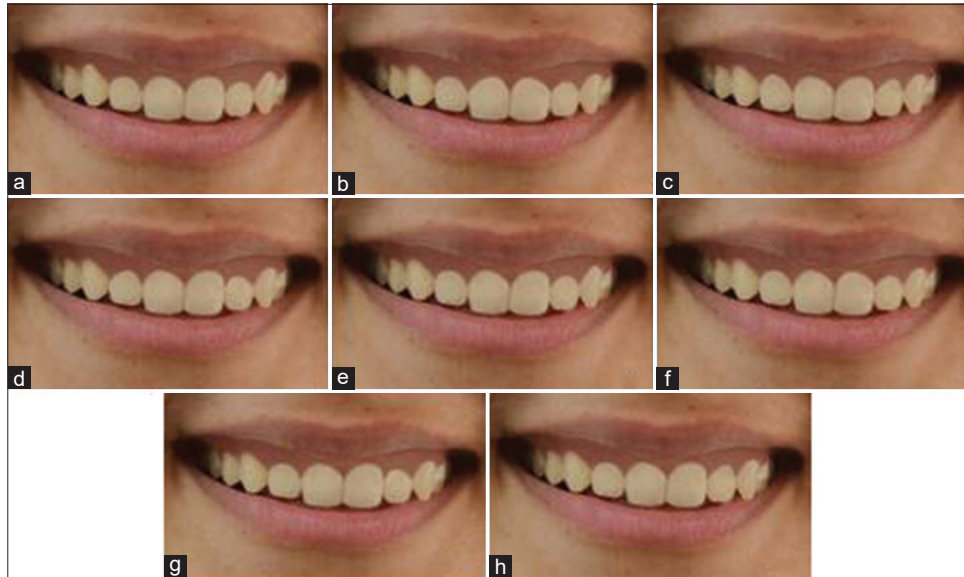


**Figure 3:** Variations in the positions of interdental papilla. (a) Reduction in interdental papilla between maxillary central incisors by 1 mm, (b) Reduction in interdental papilla between maxillary central incisors by 2 mm, (c) Reduction in interdental papilla between maxillary central incisors by 3 mm, (d) Reduction in interdental papilla between all maxillary anteriors by 1 mm, (e) Reduction in interdental papilla between all maxillary anteriors by 2 mm, (f) Reduction in interdental papilla between all maxillary anteriors by 3 mm.

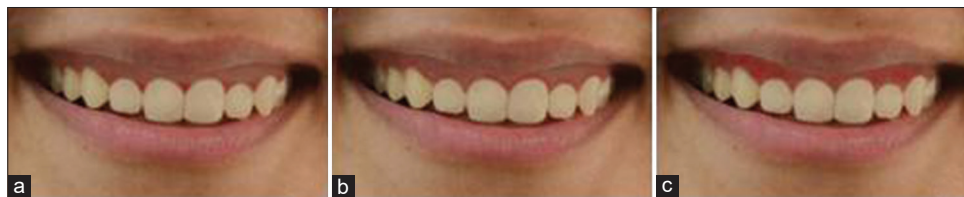### Statistical tests and analysis

Descriptive analysis was presented in terms of the frequency distribution of traits such as mean-mode and standard deviation calculation to analyze the most-liked image by a maximum number of subjects (Mode), ordering of characteristics in the increasing order of their attractiveness appeal (Mean). Standard deviation was used to understand variance in responses. An independent sample *t*-test was

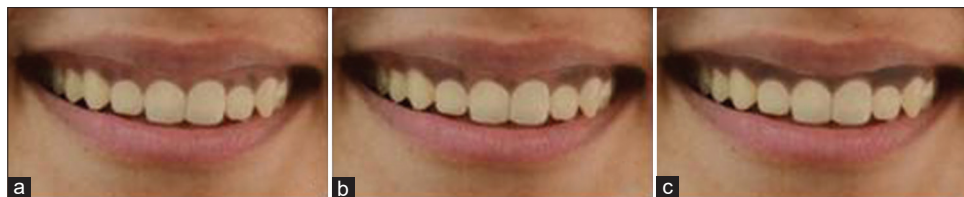
used for intergroup comparison [Table 1] to compare all factors with the control group (Factor 8) and to compare each of the consecutive factors in the ranking table. To analyze whether there is a statistically significant difference in mean responses across factors by three groups (orthodontists, general dentists, and laypersons), Kruskal–Wallis test was performed. All statistical tests were done at a 5% level of significance. The data was analyzed using statistical software SPSS 25.0 (Statistical Package for the Social Sciences).



**Figure 4:** Variations in the zenith position. (a) Bilateral mesial shift of canine zenith, (b) Bilateral mesial shift of the central incisor zenith, (c) Bilateral distal shift of lateral incisor zenith, (d) Bilateral mesial shift of lateral incisor zenith, (e) Unilateral mesial shift of canine zenith, (f) Unilateral mesial shift of the central incisor zenith, (g) Unilateral mesial shift of lateral incisor zenith, (h) Unilateral distal shift of lateral incisor zenith.



**Figure 5:** Color changes due to varying degrees of gingival inflammation. (a) Papillary gingivitis, (b) Marginal gingivitis, (c) Generalized gingivitis.



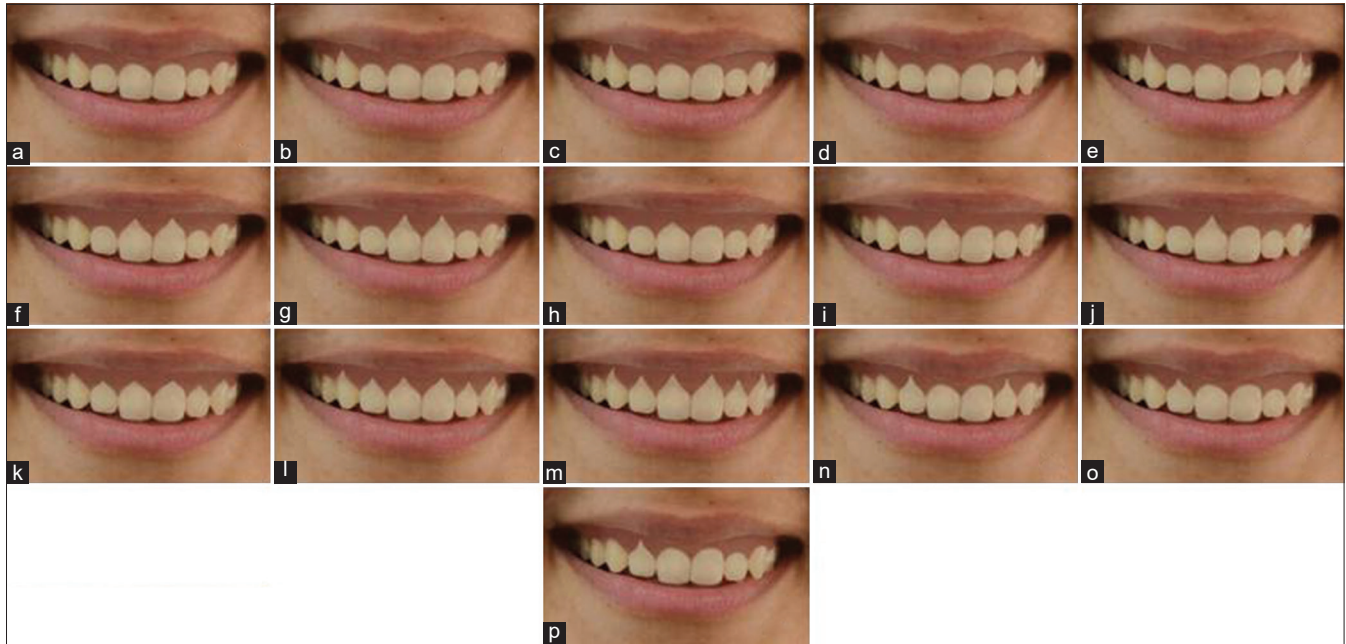**Figure 6:** Color changes due to varying degrees of gingival pigmentation. (a) Patchy pigmentation, (b) Pigmentation in bands, (c) Generalized pigmentation.

## RESULTS

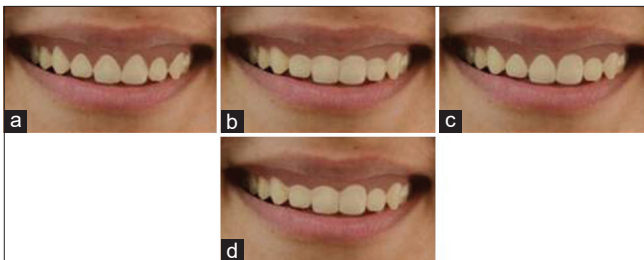
Table 1 refers to the ranking of the seven factors and the control group or the intergroup comparison. The factors were rated in decreasing order of attractiveness as follows: Control images, variations in the zenith position, varying contours of the gingiva, variations in the position of free gingival margin without recession, color changes due to varying degrees of gingival pigmentation, color changes due to varying degrees of gingival inflammation, variations in the position of interdental papilla, and variations in the position of free gingival margin with recession. *P*-values to

compare all factors with the control group [Figure 1] and to compare each of the consecutive factors in the ranking table is also presented in Table 1. A highly statistically significant difference was found in the means of all factors when compared with the control group except for Factor 3 (variations in the zenith position) which means, Factor 3 was rated as highly as the control image.

Table 2 describes the most attractive and least attractive variations in a group or the intragroup rating. Factor 1 was variations in the position of free gingival margin without recession [Figure 2]. Laypersons considered a unilateral



**Figure 7:** Variations in the positions of free gingival margin with recession. (a) Unilateral recession of canine by 1 mm, (b) Unilateral recession of canine by 2 mm, (c) Unilateral recession of canine by 3 mm, (d) Bilateral recession of canine by 2 mm, (e) Bilateral recession of canine by 3 mm, (f) Bilateral recession of central incisor by 2 mm, (g) Bilateral recession of central incisor by 3 mm, (h) Unilateral recession of central incisor by 1 mm, (i) Unilateral recession of central incisor by 2 mm, (j) Unilateral recession of central incisor by 3 mm, (k) Recession in all maxillary anteriors by 1 mm, (l) Recession in all maxillary anteriors by 2 mm, (m) Recession in all maxillary anteriors by 3 mm, (n) Bilateral recession in lateral incisor by 3 mm, (o) Unilateral recession in lateral incisor by 2 mm, (p) Unilateral recession in lateral incisor by 3 mm.



**Figure 8:** Varying contours of the gingiva. (a) Bilaterally accentuated gingival contour, (b) Bilaterally denuded gingival contour, (c) Unilaterally accentuated gingival contour, (d) Unilaterally denuded gingival contour.

increase in the Free Gingival Margin of the central incisor by 1 mm from the canine (2D) to be most attractive. General dentists and orthodontists both considered image unilateral reduction of Free Gingival Margin of canine up to the level of the lateral incisor (2A) to be most attractive. The image with unilateral reduction of Free Gingival Margin of the central incisor below the level of the lateral incisor (2G) was rated least attractive by orthodontists, general dentists, and laypersons.

The second factor was variation in the position of the interdental papilla [Figure 3]. Laypersons considered a reduction in interdental papilla between maxillary central

incisors by 2 mm (3B) to be attractive whereas general dentists and orthodontists considered a reduction in interdental papilla between maxillary central incisors by 1 mm (3A) to be attractive. Furthermore, for laypersons and general dentists' reduction in interdental papilla between all maxillary anteriors by 2 mm (3E) was ranked least attractive, and for orthodontists, the least attractive image was a reduction in interdental papilla between all maxillary anteriors by 3 mm (3F). The third factor was the variations in the zenith position [Figure 4]. Laypersons and orthodontists considered image (4H) unilateral distal shift of lateral incisor zenith to be most attractive whereas general dentists considered image (4G) unilateral mesial shift of lateral incisor zenith to be attractive. Orthodontists, general dentists, and laypersons considered image (4B) bilateral mesial shift of the central incisor zenith to be least attractive. The fourth factor was color changes due to varying degrees of gingival inflammation [Figure 5]. Orthodontists, general dentists, and laypersons considered image (5B) marginal gingivitis to be most attractive. Furthermore, laypersons and general dentists considered image (5A) papillary gingivitis to be least attractive whereas orthodontists considered image (5C) generalized gingivitis to be least attractive.

The fifth factor was color changes due to varying degrees of gingival pigmentation [Figure 6]. Orthodontists, general

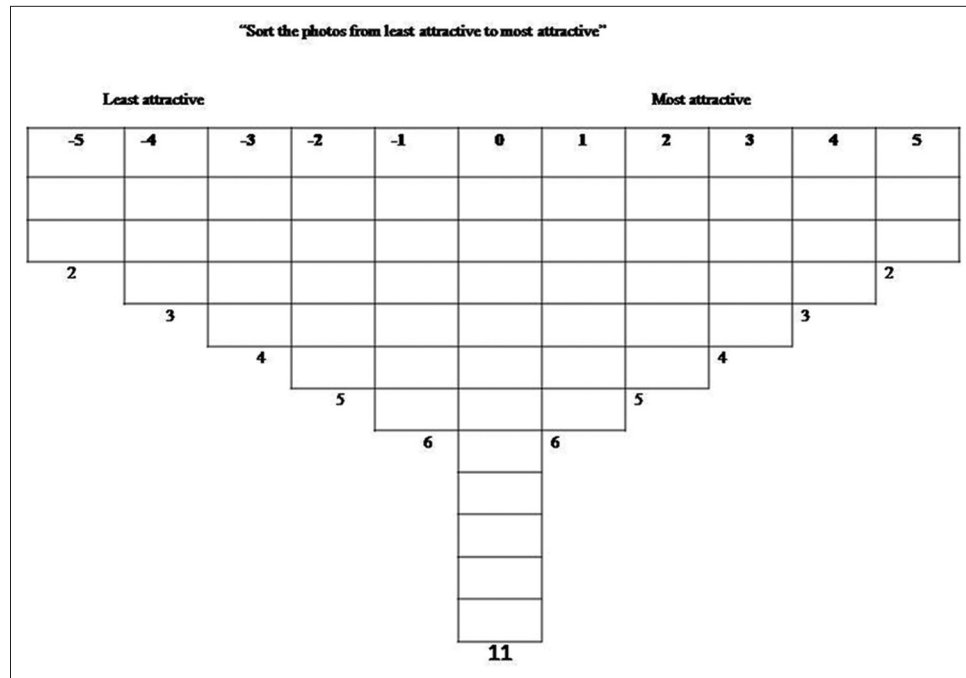


Figure 9: Example of the Q sort configuration used.

**Table 1: Intergroup comparison.**

Factors	Name	Mean	Standard Deviation	Ranking According to Mean	P-value (comparing all factors with control image)	P-value (consecutive factor comparison)
ct	Control images	2.2	1.72	1	1	0.72 (Factor 8~Factor 3)
3	Variations in the zenith position	2.13	1.78	2	0.72	0.00** (Factor 3≠Factor 7)
7	Varying contours of gingival	1.16	1.59	3	0.00**	0.64 (Factor 7~Factor 1)
1	Variations in the position of free gingival margin without recession	1.07	1.81	4	0.00**	0.00** (Factor 1≠Factor 5)
5	Color changes due to varying degrees of gingival pigmentation	-0.19	2.26	5	0.00**	0.09 (Factor 5~Factor 4)
4	Color Changes due to varying degrees of gingival inflammation	-0.6	1.93	6	0.00**	0.00** (Factor 4≠Factor 2)
2	Variations in the position of interdental papilla	-1.26	2.05	7	0.00**	0.055 (Factor 2~Factor 6)
6	Variations in the position of free gingival margin with recession	-1.71	2.01	8	0.00**	

Mean response ranking based on statistical significance: 8~3 > 7~1 > 5~4 > 2~6. A~B denotes that there is no significant difference statistically between mean response of factors A and B A≠B denotes that there is a significant difference between mean response of factors A & B \*\* in P<0.01, hence, highly statistically significant at 1% level of significance

dentists, and laypersons considered image (6A) patchy pigmentation to be most attractive. Laypersons considered image (6B) pigmentation in bands to be unattractive and general dentists and orthodontists considered image (6C) generalized pigmentation to be unattractive. The sixth factor was variations in the position of free gingival margin with recession [Figure 7]. Orthodontists, general dentists, and laypersons all considered image (7A) unilateral recession of canine by 1 mm to be most attractive and image (7M)

recession in all maxillary anterior by 3 mm to be least attractive. The seventh factor was varying contours of the gingiva [Figure 8]. Laypersons and general dentists considered image (8A) bilaterally accentuated gingival contour to be most attractive whereas orthodontists considered image (8B) bilaterally denuded gingival contour to be most attractive. Furthermore, general dentists considered image (8B) bilaterally denuded gingival contour to be least attractive, orthodontists considered image unilaterally

**Table 2:** Intragroup comparison.

Factor	Laypersons		General dentists		Orthodontists		P-value
	Most attractive	Least attractive	Most attractive	Least attractive	Most attractive	Least attractive	
ct	Control (ct) 2.26 ± 1.6		Control (ct) 2.30 ± 1.91		Control (ct) 2.05 ± 1.64		0.50
3	Figure 4h 2.94 ± 1.68	Figure 4b 1.32 ± 1.58	Figure 4g 2.56 ± 1.85	Figure 4b 1.2 ± 1.76	Figure 4h 3.12 ± 1.67	Figure 4b 1.54 ± 1.69	0.59
7	Figure 8a 1.82 ± 1.6	Figure 8d 0.96 ± 1.94	Figure 8a 1.7 ± 1.98	Figure 8b 0.68 ± 1.28	Figure 8b 1.46 ± 1.39	Figure 8c 0.64 ± 1.19	0.08
1	Figure 2d 2.08 ± 1.78	Figure 2g -0.26 ± 1.44	Figure 2a 2.12 ± 1.79	Figure 2g 0.22 ± 1.3	Figure 2a 2.8 ± 1.63	Figure 2g -0.64 ± 1.38	0.28
5	Figure 6a -0.46 ± 1.91	Figure 6b -1.56 ± 2.24	Figure 6a -0.02 ± 1.96	Figure 6c -0.94 ± 2.12	Figure 6a 1.74 ± 1.74	Figure 6c 0.4 ± 2.26	0.00**
4	Figure 5b -0.19 ± 2.15	Figure 5a -1.16 ± 1.76	Figure 5b -0.46 ± 2.14	Figure 5a -0.8 ± 1.68	Figure 5b 0.34 ± 2.12	Figure 5c -0.46 ± 1.58	0.00**
2	Figure 3b 0.12 ± 2.04	Figure 3e -2.62 ± 1.83	Figure 3a 0.48 ± 1.39	Figure 3e -2.58 ± 1.93	Figure 3a 0.14 ± 1.26	Figure 3f -2.58 ± 1.7	0.85
6	Figure 7a 1.2 ± 2.02	Figure 7m -2.58 ± 1.82	Figure 7a 1.62 ± 1.85	Figure 7m -3.26 ± 2.02	Figure 7a 1.46 ± 2.14	Figure 7m -4.3 ± 1.26	0.00**

\*\*P<0.01, hence, highly statistically significant at 1% level of significance

accentuated gingival contour (8C) to be least attractive, and laypersons considered image (8D) unilaterally denuded gingival contour to be least attractive. The last factor was the control group [Figure 1] and both control photographs were rated positively by all three groups. Kruskal–Wallis test was performed to understand if the response distribution was same across the three groups. Based on P-values in Table 2, no statistically significant difference in mean response was found across three groups for Factors 8 (control image), 3 (Variations in the zenith position), 7 (Varying contours of gingiva), 1 (Variations in the position of free gingival margin without recession), and 2 (Variations in the positions of interdental papilla). However, a statistically significant difference in mean response was found across three groups for Factor 4 (Color changes due to varying degrees of gingival inflammation), 5 (Color changes due to varying degrees of gingival pigmentation), and 6 (Variations in the positions of free gingival margin with the recession), which could be attributed mainly due to the orthodontist group.

## DISCUSSION

This study aimed to evaluate the difference in perception of a trained eye versus an untrained eye and whether the level of training made any difference in the perceptions. It is important to evaluate this as it would enable the smile architects to design smiles keeping in mind the threshold levels of acceptance of various groups.

The two most commonly used ranking methodologies to analyze and compare the esthetic perceptions are the VAS and Q-sort.<sup>[24-27]</sup> Both methods have merits and demerits of their

own. In VAS participants rank individual photographs and they cannot return to the previous photograph and change the rank order if they wish to, whereas, in Q-methodology, all the photographs are present in front of the participant.<sup>[25]</sup> The Q sort has been presented with slightly increased values than VAS according to some studies.<sup>[24,25]</sup> Hence, Q sort was used in this study. The first thing that was analyzed in this study was, which altered gingival characteristic was most and least noticeable by orthodontists, general dentists, and laypersons [Table 1]. The results indicate that change in color either due to inflammation or pigmentation or due to black triangles was perceived most negatively by all the three groups as in the study conducted by Batra *et al.*<sup>[9]</sup> Although in our study, a gingival recession was ranked most negatively, possibly due to more trained subjects evaluating the images.

The second aim was to assess the extent to which alterations within each factor can go unnoticed. For variations in the free gingival margin without recession, changes in the central area were more readily perceived by all three groups. The bilateral presence of the black triangle was easily detectable in comparison to the black triangle present unilaterally. The results also point towards the fact that the level of training also influences the perceptions as orthodontists could detect even minor changes. The previous studies have shown that the black triangle was noticeable at 3 mm by dentists and laypersons and at 2 mm by orthodontists, periodontists, and prosthodontists.<sup>[13,28]</sup> A study done by Gehrke *et al.* contradicts this result as according to them, black triangles of even 1 mm were detectable by laypersons.<sup>[19]</sup>

In the zenith group, unilateral changes went unnoticed by all the three groups in comparison to bilateral. The changes in

the position of the zenith in lateral incisors and canines were unnoticed in comparison to alterations in the central incisors. This could be because of the distal positioning of canines and thus their reduced visibility as compared to the central incisors.

For those factors that affected the color such as inflammation and pigmentation of the gingiva, it was found that the color changes that were perceived readily like localized change in color due to inflammation or generalized pigmentation ranked more unesthetic. Variations in the position of free gingival margin with recession were found to be least attractive and most negatively ranked by all the three evaluators. The results indicate that unilateral or bilateral recession of gingiva is noticed only when it reaches 3 mm and canines because they are distally positioned that their recession goes unnoticed by all three evaluator groups. Similar results were found by Musskopf *et al.*<sup>[20]</sup> who claimed that a generalized recession is more unesthetic in comparison to a localized recession. The other studies which show similar results are by Gehrke *et al.*,<sup>[19]</sup> Kokich *et al.*,<sup>[13]</sup> and Batra *et al.*<sup>[9]</sup> Thus, recession in interdental papilla or free gingival margin was more negatively perceived when it was generalized as compared to localized changes.

Coming over to the last factor, varying contours of the gingiva, the results showed that for laypersons and general dentists, both accentuated gingival contours bilaterally (8A) were found to be most attractive and for orthodontists, denuded gingival contour bilaterally (8B) was found to be most attractive. The results show that the changes done bilaterally remain unnoticed to trained as well as an untrained eye in comparison to changes done unilaterally.

This study has reinforced the importance of pink esthetics in smile design. The gingival factors were found to be as important as dental factors in perceiving the esthetics of a smile by different specialties and laypersons, as were found in the study done by Kau *et al.*<sup>[29,30]</sup> The main challenges faced in the study were that there were 51 images, and it was difficult for the evaluators to judge each photograph individually, especially by laypersons. Cross-checking at the end of each Q sort was very important before the evaluator left to ensure that the desired number of photos were placed in each column. Another important observation was that orthodontists took less time and were more confident while doing Q-sort. Orthodontists seem to be less tolerant in their evaluations in comparison to general dentists and laypersons. These differences in perception should be kept in mind while formulating a treatment plan and designing a balanced smile.

## CONCLUSION

In the present study, the three groups rated the gingival recession as the least attractive factor followed by a black

triangle and changes in color due to inflammation and pigmentation. Alterations in gingival scalloping and changes in location of free gingival margin without recession were ranked moderately. Gingival zenith and control group images were most positively ranked. Bilateral changes were perceived more readily compared to unilateral in factors such as a black triangle, zenith position, pigmentation, inflammation, and recession. Modifications on distal teeth like canines went unnoticed due to their reduced visibility. The findings of this study point towards the crucial fact that smile design should focus on factors that are perceived readily by the public in general.

## Acknowledgments

I would like to acknowledge Mrs. Khyati Sharma [B.Sc (Statistics Hons.) and Masters in Statistics] for doing all the statistical analysis of the study as without her sincere efforts and dedication this study would not have been possible.

## Declaration of patient consent

Patient's consent not required as there are no patients in this study.

## Financial support and sponsorship

Nil.

## Conflicts of interest

There are no conflicts of interest.

## REFERENCES

1. Guth É, Bacon W. Smile in self-representation and self-esteem. *Orthod Fr* 2010;81:323-9.
2. Henson ST, Lindauer SJ, Gardner WG, Shroff B, Tufekci E, Best AM. Influence of dental esthetics on social perceptions of adolescents judged by peers. *Am J Orthod Dentofacial Orthop* 2011;140:389-95.
3. Sarver DM. Enameloplasty and esthetic finishing in orthodontics-identification and treatment of microesthetic features in orthodontics part 1. *J Esthet Restor Dent* 2011;23:296-302.
4. Davis NC. Smile design. *Dent Clin North Am* 2007;51:299-318.
5. Sarver DM. The importance of incisor positioning in the esthetic smile: The smile arc. *Am J Orthod Dentofacial Orthop* 2001;120:98-111.
6. Morley J, Eubank J. Macroesthetic elements of smile design. *J Am Dent Assoc* 2001;132:39-45.
7. Sarver DM. Principles of cosmetic dentistry in orthodontics: Part 1. Shape and proportionality of anterior teeth. *Am J Orthod Dentofacial Orthop* 2004;126:749-53.
8. Bhuvaneshwaran M. Principles of smile design. *J Conserv Dent*



- 2010;13:225-32.
9. Batra P, Daing A, Azam I, Miglani R, Bhardwaj A. Impact of altered gingival characteristics on smile esthetics: Laypersons' perspectives by Q sort methodology. *Am J Orthod Dentofacial Orthop* 2018;154:82-90.
  10. Sriphadungporn C, Chamnannidiadha N. Perception of smile esthetics by laypeople of different ages. *Prog Orthod* 2017;18:8.
  11. Geron S, Atalia W. Influence of sex on the perception of oral and smile esthetics with different gingival display and incisal plane inclination. *Angle Orthod* 2005;75:778-84.
  12. Sadrhaghghi AH, Zarghami A, Sadrhaghghi S, Mohammadi A, Eskandarinezhad M. Esthetic preferences of laypersons of different cultures and races with regard to smile attractiveness. *Indian J Dent Res* 2017;28:156-61.
  13. Kokich VO, Kokich VG, Kiyak HA. Perceptions of dental professionals and laypersons to altered dental esthetics: Asymmetric and symmetric situations. *Am J Orthod Dentofacial Orthop* 2006;130:141-51.
  14. Springer NC, Chang C, Fields HW, Beck FM, Firestone AR, Rosenstiel S, *et al.* Smile esthetics from the layperson's perspective. *Am J Orthod Dentofacial Orthop* 2011;139:e91-101.
  15. Simões D, de Brito GM, Cangussu MC, Machado AW. Does the vertical position of maxillary central incisor or sinmen influence smile esthetics perception? *Am J Orthod Dentofacial Orthop* 2019;156:485-92.
  16. Anderson KM, Behrents RG, McKinney T, Buschang PH. Tooth shape preferences in an esthetic smile. *Am J Orthod Dentofacial Orthop* 2005;128:458-65.
  17. Al Taki A, Khalesi M, Shagmani M, Yahia I, Al Kaddah F. Perceptions of altered smile esthetics: A comparative evaluation in orthodontists, dentists, and laypersons. *Int J Dent* 2016;2016:7815274.
  18. Ponnaiyan D, Jegadeesan V, Perumal G, Anusha A. Correlating skin color with gingival pigmentation patterns in South Indians a cross-sectional study. *Oral Health Dent Manag* 2014;13:132-6.
  19. Gehrke P, Strohecker A, Dhom G. Influence of interdental papilla length and interproximal contact point on the perception of esthetics in symmetric and asymmetric situations. *J Dent Implantol* 2010;3:230-46.
  20. Musskopf ML, Rocha JM, Rosing CK. Perception of smile esthetics varies between patients and dental professionals when recession defects are present. *Braz Dent J* 2013;24:385-90.
  21. Rocha JM, Ramazini C, Rosing CK. Analysis of gingival margin esthetic clinical conditions by dental students. *Acta Odontol Latinoam* 2010;24:279-82.
  22. Garber DA, Salama MA. The aesthetic smile: Diagnosis and treatment. *Periodontol* 2000 1996;11:18-28.
  23. Watts S, Stenner P. Doing Q methodology: Theory, method, and interpretation. *Qual Res Psychol* 2005;2:67-91.
  24. Oliveira PL, Motta AF, Guerra CJ, Mucha JN. Comparison of two scales for evaluation of smile and dental attractiveness. *Dental Press J Orthod* 2015;20:42-8.
  25. Schabel BJ, McNamara JA Jr., Franchi L, Baccetti T. Q-sort assessment vs visual analog scale in the evaluation of smile esthetics. *Am J Orthod Dentofacial Orthop* 2009;135:S61-71.
  26. Havens DC, McNamara JA Jr., Sigler LM, Baccetti T. The role of the posed smile in overall facial esthetics. *Angle Orthod* 2010;80:322-8.
  27. Stephenson W. *The Study of Behavior: Q-Technique and its Methodology*. Chicago: University of Chicago Press; 1953.
  28. Kokich VO Jr., Kiyak HA, Shapiro PA. Comparing the perception of dentists and lay people to altered dental esthetics. *J Esthet Dent* 1999;11:311-24.
  29. Kau CH, Christou T, Xie RB, Abou-Saleh T. Rating of smile attractiveness of patients finished to the American Board of Orthodontics Standards. *J Orofacial Orthop* 2020;81:239-48.
  30. Soh J, Wang ZD, Zhang WB, Kau CH. Smile attractiveness evaluation of patients selected for a U.S.-based board certification examination. *Eur J Dent* 2021;15:630-8.

**How to cite this article:** Sharma N, Kannan S, Arora N, Singh AK, Malhotra A, Batra P. Comparison between orthodontist, general dentist, and layperson in the perception of pink esthetics on smile: A cross-sectional study. *APOS Trends Orthod* 2022;12:176-86.

## SUPPLEMENT

### Various Modifications Done on Ideal Smile

#### 1. Variations in the position of free gingival margin without a recession

Nomenclature	Unilateral
Figure 2a	Unilateral reduction of Free Gingival Margin of canine up to the level of lateral incisor
Figure 2b	Unilateral reduction of Free Gingival Margin of canine below the level of lateral incisor
Figure 2c	Unilateral increase in the Free Gingival Margin level of canine from the central incisor
Figure 2d	Unilateral increase in the Free Gingival Margin level of the central incisor by 1 mm from canine
Figure 2e	Unilateral increase in the Free Gingival Margin level of the central incisor by 2 mm from canine
Figure 2f	Unilateral reduction of Free Gingival Margin of the central incisor up to the level of lateral incisor
Figure 2g	Unilateral reduction of Free Gingival Margin of the central incisor below the level of lateral incisor
Figure 2h	Unilateral increase in the Free Gingival Margin of lateral incisor above the level of canine and central incisor
Figure 2i	Unilateral reduction of Free Gingival Margin of lateral incisor by 2 mm below the level of canine

#### 2. Variations in the positions of interdental papilla

Nomenclature	
Figure 3a	Reduction in interdental papilla between maxillary central incisors by 1 mm
Figure 3b	Reduction in interdental papilla between maxillary central incisors by 2 mm
Figure 3c	Reduction in interdental papilla between maxillary central incisors by 3 mm.
Figure 3d	Reduction in interdental papilla between all maxillary anteriors by 1 mm
Figure 3e	Reduction in interdental papilla between all maxillary anteriors by 2 mm
Figure 3f	Reduction in interdental papilla between all maxillary anteriors by 3 mm

3. Variations in the zenith position

Nomenclature	Unilateral	Bilateral	Nomenclature
Figure 4e	Unilateral mesial shift of canine zenith	Bilateral mesial shift of canine zenith	Figure 4a
Figure 4f	Unilateral mesial shift of the central incisor zenith	Bilateral mesial shift of the central incisor zenith	Figure 4b
Figure 4g	Unilateral mesial shift of lateral incisor zenith	Bilateral distal shift of lateral incisor zenith	Figure 4c
Figure 4h	Unilateral distal shift of lateral incisor zenith	Bilateral mesial shift of lateral incisor zenith	Figure 4d

4. Color changes due to varying degrees of gingival inflammation

Nomenclature	
Figure 5a	Papillary gingivitis
Figure 5b	Marginal gingivitis
Figure 5c	Generalized gingivitis

5. Color changes due to varying degrees of gingival pigmentation

Nomenclature	
Figure 6a	Patchy pigmentation
Figure 6b	Pigmentation in bands
Figure 6c	Generalized pigmentation

6. Variations in the positions of free gingival margin with a recession

Nomenclature	Unilateral	Bilateral	Nomenclature
Figure 7a	Unilateral recession of canine by 1 mm	Bilateral recession of canine by 2 mm	Figure 7d
Figure 7b	Unilateral recession of canine by 2 mm	Bilateral recession of canine by 3 mm	Figure 7e
Figure 7c	Unilateral recession of canine by 3 mm	Bilateral recession of central incisor by 2 mm	Figure 7f
Figure 7h	Unilateral recession of central incisor by 1 mm	Bilateral recession of central incisor by 3 mm	Figure 7g
Figure 7i	Unilateral recession of central incisor by 2 mm	Bilateral recession in lateral incisor by 3 mm	Figure 7n
Figure 7j	Unilateral recession of central incisor by 3 mm	Recession in all maxillary anteriors by 1 mm	Figure 7k
Figure 7o	Unilateral recession in lateral incisor by 2 mm	Recession in all maxillary anteriors by 2 mm	Figure 7l
Figure 7p	Unilateral recession in lateral incisor by 3 mm	Recession in all maxillary anteriors by 3 mm	Figure 7m

7. Varying contours of gingiva

Nomenclature	Unilateral	Bilateral	Nomenclature
Figure 8c	Accentuated gingival contour	Accentuated gingival contour	Figure 8a
Figure 8d	Denuded gingival contour	Denuded gingival contour	Figure 8b