

## Case Report

# Closure of first molar extraction spaces and correction of Class II malocclusion using anterior bite turbo and Class II elastics: A case report

Nguyen Viet Anh<sup>1</sup>, Vo Truong Nhu Ngoc<sup>2</sup>, Tong Minh Son<sup>2</sup>

<sup>1</sup>Private Practice, Viet Anh Orthodontic Clinic, Nam Tu Liem, <sup>2</sup>Department of Odonto Stomatology, School of Dentistry, Hanoi Medical University, Dong Da, Hanoi, Vietnam.



### \*Corresponding author:

Nguyen Viet Anh,  
Private Practice, Viet Anh  
Orthodontic Clinic, Nam Tu  
Liem, Hanoi, Vietnam.


bsvietanhniengrang@gmail.com

Received: 06 March 2023  
Accepted: 16 April 2023  
EPub Ahead of Print: 12 May 2023  
Published: 05 March 2025

### DOI

10.25259/APOS\_54\_2023

### Quick Response Code:



## ABSTRACT

At present, orthodontists are treating more adult patients with missing or hopeless first molars as these teeth have the highest incidence of decay in permanent dentition. This case report presented the closure of extraction spaces of four first molars in a patient with Class II malocclusion. High torque self-ligating brackets were used combined with anterior bite turbo and Class II elastics. According to the case report, the combination of anterior bite turbo and Class II elastics may have the possibility to correct bite deepening during space closure and allow further upper incisor retraction and Class II correction.

**Keywords:** Anterior bite plane, Class II elastics, Molar extraction space closure, Self-ligating brackets, High torque brackets

## INTRODUCTION

At present, orthodontists are treating more adult patients with missing or hopeless first molars as these teeth have the highest incidence of decay in permanent dentition.<sup>[1]</sup> Due to the long span of space closure, some mechanics should be applied to avoid tipping adjacent teeth into extraction space.<sup>[2]</sup>

In extraction cases with Class II malocclusion, Class II elastics could be used to reinforce anchorage in the upper arch and mesialize mandibular molars.<sup>[3]</sup> Anterior bite turbo could be used in combination with Class II elastics to eliminate deep bite and reposition the mandible anteriorly.<sup>[4,5]</sup>

This case report presented the closure of extraction spaces of four first molars in a patient with Class II malocclusion using high torque self-ligating brackets, anterior bite turbo, and Class II elastics.

## CASE REPORT

A 21-year-old female patient presented to our clinic with chief complaints of missing first molars and lip protrusion. Extraorally, she had a convex profile with retruded mandible, and a left deviated chin. No sign of temporomandibular joint disorder was detected [Figure 1]. Intraorally, the patient had a Class II canine relationship with missing mandibular first molars and maxillary left first molar.

This is an open-access article distributed under the terms of the Creative Commons Attribution-Non Commercial-Share Alike 4.0 License, which allows others to remix, transform, and build upon the work non-commercially, as long as the author is credited and the new creations are licensed under the identical terms.

©2025 Published by Scientific Scholar on behalf of APOS Trends in Orthodontics

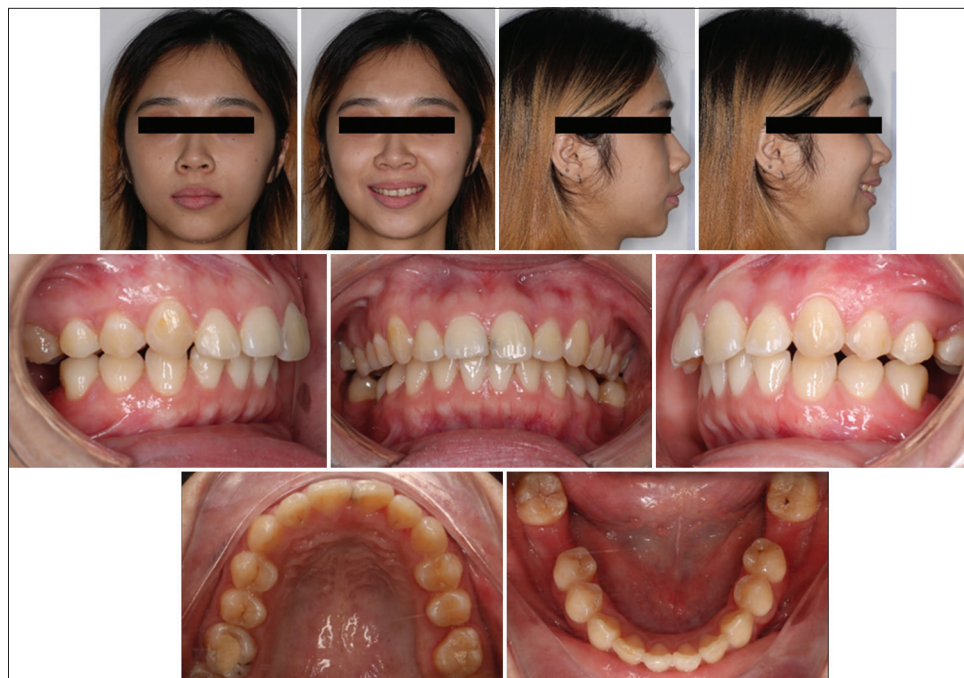

Figure 1: Pre-treatment facial and intraoral photographs.

Her maxillary right first molar had a large carious lesion. The lower dental midline deviated 1 mm to the right side.

The lateral cephalometric analysis revealed a skeletal Class II relationship (A point, nasion, B point [ANB], 6.5°) with a retruded mandible (sella nasion point B, 72.7°) and increased anterior lower facial height (Frankfort mandibular plane angle [FMA], 30.3°) [Table 1]. The upper incisors had a normal inclination (U1-SN, 99.2°), and the lower incisors were slightly proclined (Lower central incisor [L1]-mandibular plane [MP], 96.0°). Lip protrusion was confirmed (E-line/UL, 2.7 mm; E-line/LL, 3.2 mm). The panoramic radiograph showed the absence of the maxillary left first molar and mandibular first molars, the mesial tipping of the maxillary left second molar, and a large restoration approximating the pulp chamber on the maxillary right first molar [Figure 2].

### Treatment objectives

The treatment objectives include the closure of first molar extraction spaces, retraction of upper and lower incisors to improve lip protrusion without lingual tipping of upper incisors, achievement of Class I canine and molar relationship on both sides, and correction of lower dental midline deviation.

### Treatment alternatives

According to the treatment objectives, extraction of the decayed maxillary right first molar and closure of all first molar extraction spaces with skeletal anchorage on the

Table 1: Cephalometric measurements.

	Pretreatment	Posttreatment
Skeletal		
SNA (°)	79.2	79.1
SNB (°)	72.7	72.4
ANB (°)	6.5	6.7
FMA (°)	30.3	30.6
Dental		
U1-SN (°)	99.2	85.8
U1-NA (°)	20.0	6.8
U1-NA (mm)	4.0	0.7
L1-MP (°)	96.0	97.2
L1-NB (°)	32.1	31.6
L1-NB (mm)	8.8	7.2
U1-L1 (°)	121.4	134.8
Soft tissue		
E-line/UL (mm)	2.7	1.4
E-line/LL (mm)	3.2	0.9

ANB: A point, nasion, B point, FMA: Frankfort mandibular plane angle, L1: Lower central incisor, LL: Lower lip, MP: Mandibular plane, NA: Nasion point A, NB: Nasion point B, SNA: Sella nasion point A, SNB: Sella nasion point B, U1: Upper central incisor, UL: Upper lip

upper arch was the first option.<sup>[6]</sup> The second option was also extracting the maxillary right first molar and space closure with the use of Class II elastics. The patient refused mini-screw placement and was afraid of lingual tipping of upper

incisors so the second option was chosen as Class II elastics would facilitate the mesial movement of mandibular second and third molars.

**Treatment progress**

The treatment was initiated by bonding all teeth except maxillary right and mandibular third molars with 0.022 × 0.028-inch passive self-ligating high torque brackets (SmartLine, Medico, Korea) in which the torque values of upper central incisors, lateral incisors, and canines were 22°, 13°, and 7°, respectively. The archwire sequence was 0.016-inch, 0.016 × 0.022-inch, 0.019 × 0.025-inch

nickel-titanium and 0.019 × 0.025-inch stainless steel. After 5 months of treatment, the maxillary right first molar was extracted and space closure was initiated in combination with bilateral Class II elastics (3/16-inch, 3.5 Oz) [Figure 3].

After 3 months of space closure, the bite was deepened significantly, so bite turbos were bonded to maxillary central incisors at a distance of 2 mm from the incisal edge. Metal bite turbos were selected with a thickness of 2.5 mm and width of 4 mm, but composite bite turbos could also be used. V-bends were placed between second premolars and second molars to avoid tipping these teeth into the extraction space. Vertical elastics (3/16-inch, 3.5 Oz) were applied bilaterally combined with Class II elastics to close the lateral open bite and continue to correct the Class II dental relationship. When the remaining extraction spaces were minor, the remaining third molars were bonded to completely align into the dental arches [Figure 4]. The upper main archwire during the final space closure phase was 0.021 × 0.025-inch stainless steel to maximally control the torque of the upper incisors. The total active treatment time was 15 months in which the duration of Class II elastic and anterior bite turbo application was 9 months and 7 months, respectively.

**Treatment results**

The post-treatment records confirmed that all treatment objectives were achieved with improved facial profile and occlusion. All first molar extraction spaces were completely closed with solid molar and canine Class I relationships on both sides. Normal overbite and overjet were obtained with coincided dental midlines and the lip protrusion was improved [Figure 5].

The lateral cephalometric analysis showed a slightly increasing in the lower anterior facial height (FMA, 30.6°) and skeletal Class II relationship (ANB, 6.7°). The upper incisors were lingually tipped (U1-SN, 85.8°) and the lower incisors were slightly proclined (L1-MP, 97.2°). Both

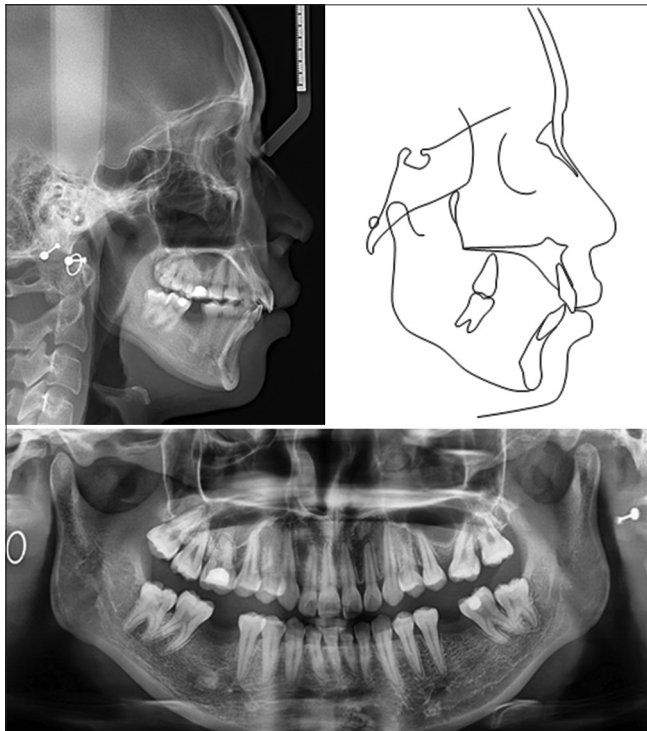


Figure 2: Pre-treatment radiographs and tracing.

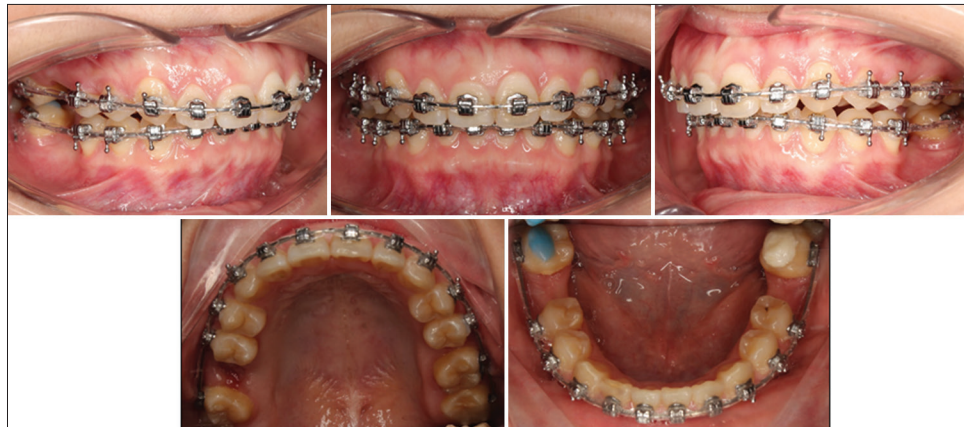
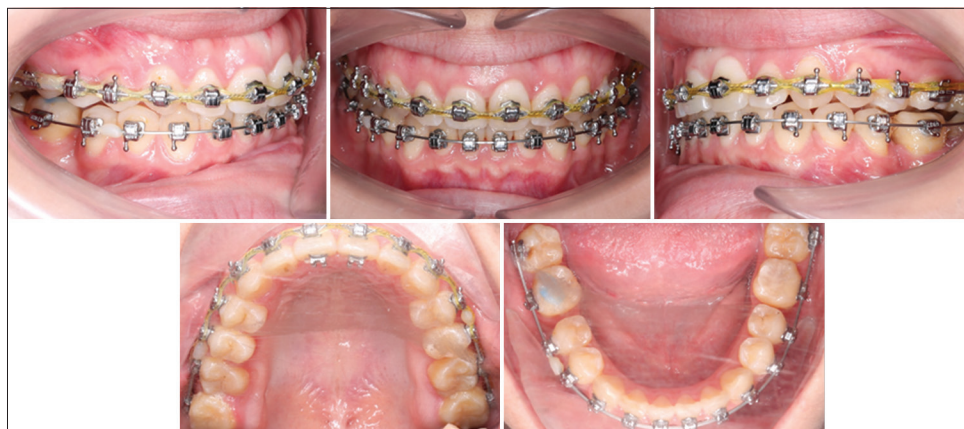
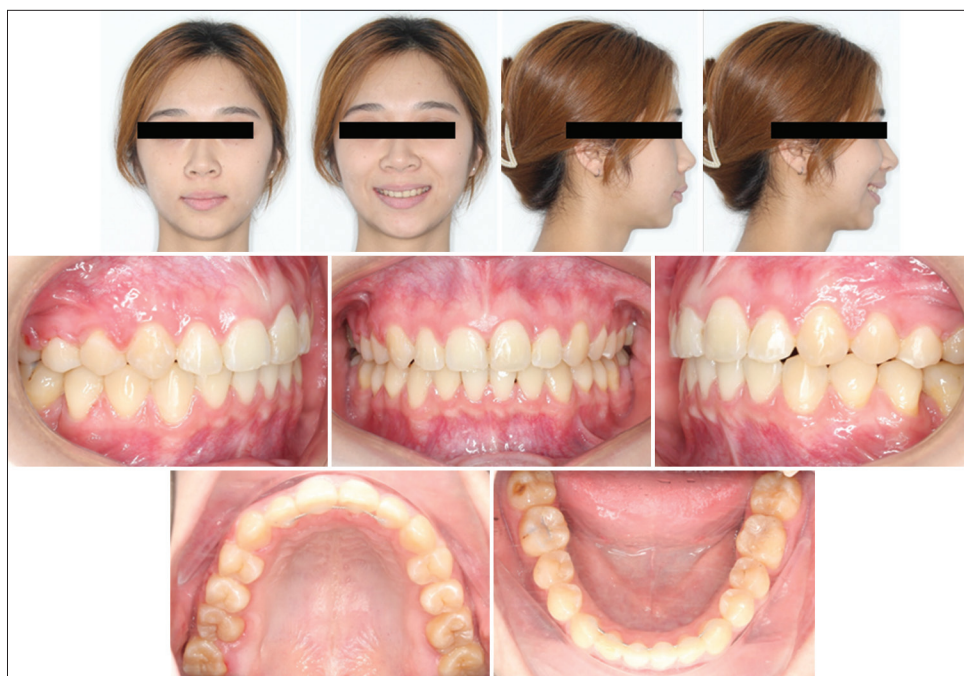Figure 3: Bite deepening during space closure.



**Figure 4:** Final space closure. Bite deepening and Class II relationship were almost corrected. All third molars were bonded.



**Figure 5:** Post-treatment facial and intraoral photographs.

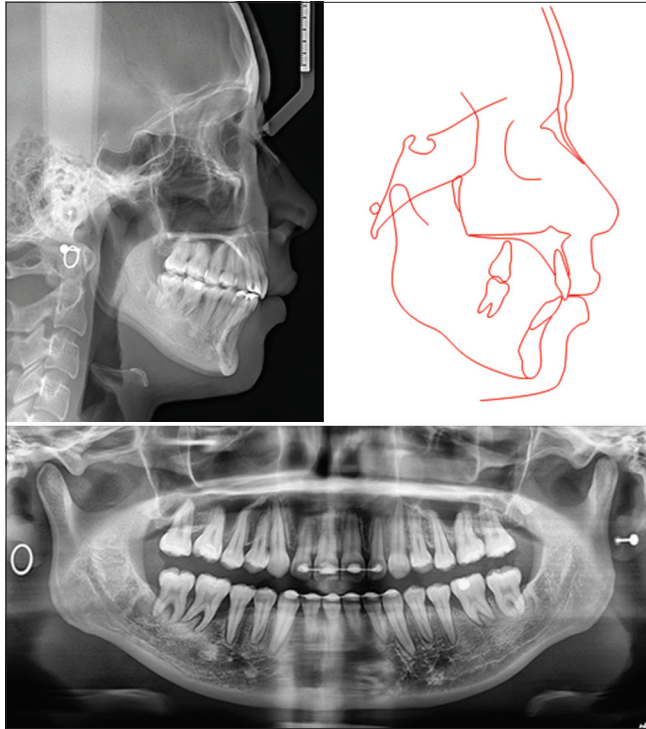
upper and lower lips were retracted (E-line/UL, 1.4 mm; E-line/Lower lip, 0.9 mm). The panoramic radiographs showed good root parallelism with the correction of the mesially tipped maxillary left first molar [Figure 6].

## DISCUSSION

By uprighting the mesially tipped maxillary left first molar, more space was available for incisor retraction and Class II correction. The uprighting was done by bonding the molar tube with a slightly negative tip and leveling it with stainless steel archwires. Initially, the third molars were not bonded as they were located too far distally causing difficulties in isolation and correct molar tube positioning. By waiting until

the first molar extraction spaces nearly closed and allowing the third molars to automatically drift mesially, more precise bonding could be done.<sup>[7]</sup>

Bite deepening during space closure is caused by the vertical bowing effect and may interfere with upper incisor retraction and Class II correction as occurred in this patient.<sup>[8,9]</sup> Therefore, bite turbos were bonded at a proper distance from the incisal edge in combination with Class II elastics to keep the mandible in an anterior position with normal overbite and overjet. The effect of this combination was similar to that of a fixed functional appliance. In the final month of treatment, Class II elastics were stopped to confirm the dental correction instead of mandible posture alteration. Furthermore, the cephalometric



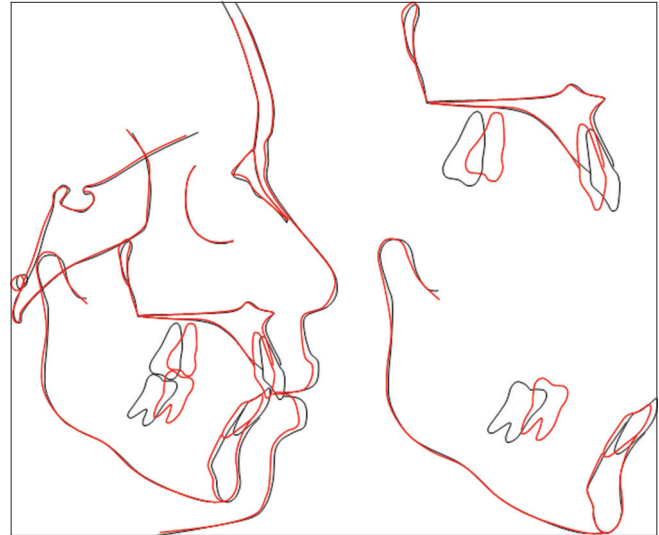
**Figure 6:** Post-treatment radiographs and tracing.

superimposition also showed the overjet correction achieved by lingual tipping of upper incisors and mesial movement of lower molars instead of positioning the mandible anteriorly.

In this case report, bite deepening was seen during the space closure stage then bite turbos were used as a corrective measure. Alternatively, anterior bite turbos could also be bonded at the initial stage of space closure as a preventive measure so the normal overjet would be maintained during the entire treatment progress.

The cephalometric analysis showed that the lower anterior facial height was slightly increased causing a minor worsening in the hyperdivergent facial pattern and skeletal Class II relationship. The cause of this problem was the prolonged use of intermaxillary elastics. Ideally, mini-screw anchorage should be used to intrude upper incisors instead of vertical elastics in the buccal segments, but it was refused by the patient. Furthermore, on the cephalometric superimposition, the upper incisors were not extruded and the upper molars were intruded [Figure 7]. The preservation of the upper incisors' vertical position might be explained by the biting force applying to the anterior bite turbos, and the intrusion of the upper molars could be caused by the clockwise rotation of the occlusal plane due to Class II elastics.<sup>[10]</sup>

High torque brackets were used combined with an almost full-size archwire in the upper arch to minimize the lingual tipping of the upper incisors during space closure as they already had normal pretreatment inclination. However,



**Figure 7:** Overall and regional cephalometric superimpositions: *black*, pretreatment; *red*, post-treatment.

a significant torque loss of upper incisors was observed posttreatment. On cephalometric superimposition, the movement of upper incisors was controlled tipping. This lingual tipping was acceptable as upper incisor roots would move lingually beyond the lingual cortical plate if the pure bodily movement was performed.<sup>[11]</sup>

## CONCLUSION

The combination of anterior bite turbo and Class II elastics may have the possibility to correct bite deepening during space closure and allow further upper incisor retraction and Class II correction.

**Ethical approval:** The Institutional Review Board approval is not required.

**Declaration of patient consent:** The authors certify that they have obtained all appropriate patient consent.

**Financial support and sponsorship:** Nil.

**Conflicts of interest:** There are no conflicts of interest.

**Use of artificial intelligence (AI)-assisted technology for manuscript preparation:** The authors confirm that there was no use of artificial intelligence (AI)-assisted technology for assisting in the writing or editing of the manuscript and no images were manipulated using AI.

## REFERENCES

1. Ratanasereprasert N, Weng CY, Yang SY, Chen YJ, Yao CC. Molar space closure: To do or not to do? *APOS Trends Orthod* 2021;12:61-8.
2. Ngoc VT, Phuong NT, Anh NV. Skeletal Class III malocclusion with lateral open bite and facial asymmetry treated with asymmetric lower molar extraction and lingual appliance:

- A case report. *Int J Environ Health Res* 2021;18:5381.
3. Martinelli F. Class II and anterior open bite malocclusion treated with mini-implants, intermaxillary elastics, speech therapy, and retained with a night-wear palatal crib wraparound. *APOS Trends Orthod* 2023;13:123-32.
  4. Ciavarella D, Laurenziello M, Guida L, Montaruli G, Gallo C, Tepedino M, *et al.* Dentoskeletal modifications in Class II deep bite malocclusion treatment with anterior bite plane functional appliance. *J Clin Exp Dent* 2017;9:e1029-34.
  5. Dixit S, Gupta G, Sharma P, Gupta S. Efficacy of anterior bite plane in Class II deep bite case-a case report. *Dent J Adv Stud* 2016;4:201-3.
  6. Anh NV, Tra NT, Hanh NT. Lingual orthodontic treatment of a skeletal Class II patient with miniscrew-assisted absolute anchorage in maxillary arch and total distalization in mandibular arch: A case report. *Orthod Waves* 2021;80:97-106.
  7. Baik UB. Molar protraction and uprighting (2<sup>nd</sup> molar protraction in the 1<sup>st</sup> molar missing site and uprighting an impacted 3<sup>rd</sup> molar). *APOS Trends Orthod* 2018;8:57-63.
  8. Lin LY, Chang CH, Roberts WE. Bimaxillary protrusion and gummy smile treated with clear aligners: Closing premolar extraction spaces with bone screw anchorage. *APOS Trends Orthod* 2020;10:120-31.
  9. Mascarenhas R, Revankar AV, Mathew JM, Chatra L, Husain A, Shenoy S. Effect of intrusive and retraction forces in labial and lingual orthodontics: A finite element study. *APOS Trends Orthod* 2014;4:36-9.
  10. Zimmer B, Nischwitz D. Therapeutic changes in the occlusal plane inclination using intermaxillary elastics. *J Orofac Orthop* 2012;73:377-86.
  11. Nguyen VA, Nguyen TT, Nguyen TT. Management of an adult patient with missing one mandibular incisor, severe overjet, and midline discrepancy with asymmetric extraction, lingual appliance, and skeletal anchorage: A case report. *J World Fed Orthod* 2020;9:86-94.

**How to cite this article:** Anh N, Ngoc V, Son T. Closure of first molar extraction spaces and correction of Class II malocclusion using anterior bite turbo and Class II elastics: A case report. *APOS Trends Orthod.* 2025;15:102-7. doi: 10.25259/APOS\_54\_2023