

## Case Report

# Management of an adult patient with severe crowding using lingual appliances and mini-screw anchorage: A case report

Tong Minh Son<sup>1</sup>, Vo Truong Nhu Ngoc<sup>1</sup>, Nguyen Viet Anh<sup>2</sup>

<sup>1</sup>Department of Odonto Stomatology, School of Dentistry, Hanoi Medical University, Dong Da, Hanoi, <sup>2</sup>Private Practice, Viet Anh Orthodontic Clinic, Nam Tu Liem, Hanoi, Vietnam.



### \*Corresponding author:

Nguyen Viet Anh,  
Private Practice, Viet Anh  
Orthodontic Clinic, Nam Tu  
Liem, Hanoi, Vietnam.

bsvietanhniengrang@gmail.com

Received: 28 February 2023

Accepted: 10 April 2023


Epub Ahead of Print: 12 May 2023

Published: 06 August 2024

### DOI

10.25259/APOS\_46\_2023

### Quick Response Code:



## ABSTRACT

At present, more adult patients seek orthodontic treatment so orthodontists are more likely to face periodontal patients and esthetic appliance demand increases. This case report presents the management of an adult patient with mild periodontitis and severe crowding using lingual appliances and mini-screw anchorage. Interproximal stripping was performed to create space and correct the triangular tooth shape and gingival black triangles. Four mini-screws were implanted in the palatal alveolar bone and mandibular buccal shelf to distalize the entire upper and lower arch. According to the case report, interproximal stripping in combination with mini-screw-assisted entire arch distalization and lingual appliances may be an effective space-creation approach in patients treated with non-extraction way.

**Keywords:** Lingual orthodontics, Lingual appliances, Mini-screw anchorage, Interproximal stripping, Temporary anchorage devices

## INTRODUCTION

At present, orthodontists are more likely to face periodontal patients because more adult patients seek orthodontic treatment.<sup>[1]</sup> Orthodontic force may accelerate periodontal disease if the periodontal inflammation is not well controlled and proper oral hygiene is not established.<sup>[2]</sup> However, adequate orthodontic treatment has been shown to improve periodontal status by improving oral hygiene, relieving occlusal trauma, and stabilizing dentition.<sup>[3]</sup>

Lingual appliances are the treatment of choice for many adult patients which have more esthetic demand during orthodontic treatment.<sup>[4]</sup> Lingual orthodontics has some biomechanical differences from labial orthodontics.<sup>[5]</sup> Skeletal anchorage could be used in combination with lingual brackets to distalize the entire arch in non-extraction treatment.<sup>[6]</sup>

This case report presents the management of an adult patient with chronic periodontitis and severe crowding using lingual appliances and mini-screw anchorage.

## CASE REPORT

A 27-year-old female patient presented to our office with the chief complaint of anterior crowding. She strongly desired an invisible orthodontic appliance because she was a live streamer.

This is an open-access article distributed under the terms of the Creative Commons Attribution-Non Commercial-Share Alike 4.0 License, which allows others to remix, transform, and build upon the work non-commercially, as long as the author is credited and the new creations are licensed under the identical terms.

©2024 Published by Scientific Scholar on behalf of APOS Trends in Orthodontics

Extraorally, she had a convex profile with an acute nasolabial angle and her chin deviated to the left side. No sign of temporomandibular joint disorder was revealed [Figure 1].

On intraoral examination, the patient had a Class I dental relationship on the left and an end-on Class II dental relationship on the right. Her lower dental midline deviated 3.5 mm to the left side. The arch length discrepancies were 8.3 mm and 6.8 mm in the upper and lower arch, respectively. Due to the severe crowding, both upper central incisors had carious lesions. The upper incisors' periodontal pocket depths were increased [Table 1].

The lateral cephalometric analysis showed a skeletal Class II relationship (A point, nasion, B point [ANB],  $6.0^\circ$ ) with a retruded mandible (Sella nasion point B,  $70.6^\circ$ ) and hyperdivergent facial pattern (Frankfort mandibular plane angle [FMA],  $38.2^\circ$ ) [Table 2]. The upper incisors were retroclined (Upper central incisor-Sella nasion [U1-SN],  $93.3^\circ$ ) and the lower incisor was slightly proclined (Lower central incisor-Mandibular plane [L1-MP],  $94.0^\circ$ ). The upper and lower lips were protrusive (E-line/upper lip [UL], 1.4 mm; E-line/lower lip [LL], 3.6 mm). The panoramic radiograph confirmed the reduced alveolar bone height of the upper incisors [Figure 2].

### Treatment objectives

The periodontal treatment objectives were to eliminate inflammation, reduce periodontal pocket depth, and maintain alveolar bone level. The orthodontic treatment objectives included leveling and alignment of both dental

arches, improving the axial inclination of upper and lower incisors, achievement of Class I canine and molar relationship on both sides, correction of lower dental midline deviation, reducing lower facial height, and retraction of upper and lower lips for a more harmonious profile.

### Treatment alternatives

Due to the severe crowding and lip protrusion, four bicuspid extraction treatment was the first option. The second option was a non-extraction treatment plan (except third molars) with two-arch distalization using mini-screw anchorage and interproximal stripping to create enough space for tooth alignment. The patient desired a treatment option with less tooth extraction so the second option was chosen. The post-treatment records showed improved smile esthetics and occlusion. According to the case report, interproximal stripping in combination with mini-screw-assisted entire arch distalization and lingual appliances may be an effective space-creation approach in periodontally compromised patients treated with non-extraction way.

### Treatment progress

First, the patient was referred to a periodontist for periodontal pocket curettage and proper oral hygiene was emphasized throughout the entire orthodontic treatment process. After confirming the stability of the periodontal status, the upper arch was bonded with  $0.018 \times 0.025$ -inch lingual appliances (ADB, Medico, Korea) and the lower arch was bonded with

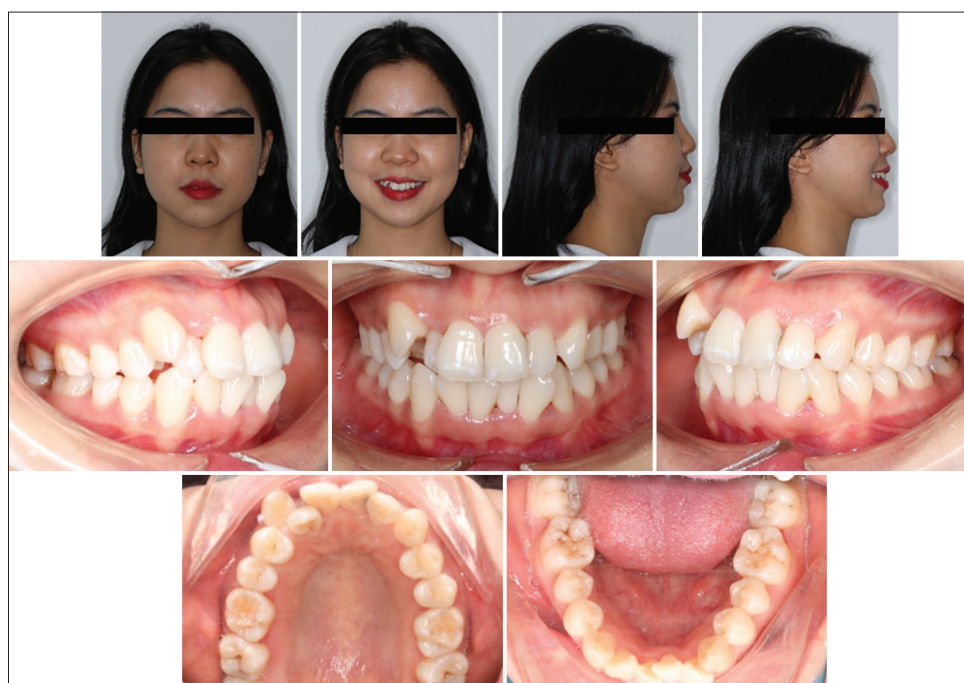

Figure 1: Pre-treatment facial and intraoral photographs.

**Table 1:** Initial, post-surgery, and post-treatment periodontal probing depth.

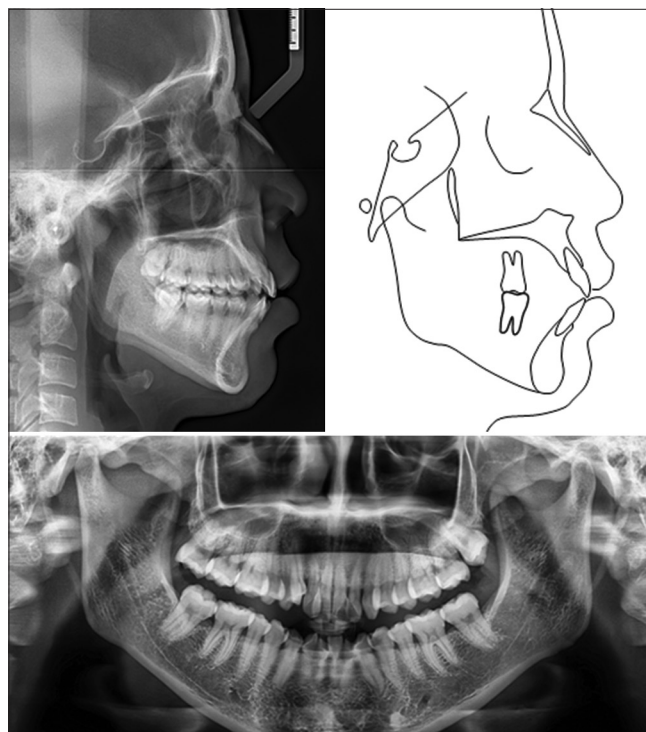
	Labial, lingual, mesial, and distal						
	11	12	13	14	15	16	17
Initial	3,3,5,4	3,4,4,4	3,4,5,4	3,2,3,3	3,3,3,3	3,3,4,5	3,4,5,4
Post-surgery	2,2,3,2	2,2,3,3	2,2,3,3	2,2,3,2	2,2,2,3	2,2,2,3	2,2,3,2
Post-treatment	2,2,3,2	2,2,2,3	2,2,2,3	2,2,3,3	2,3,2,3	2,2,3,3	2,2,3,3
	21	22	23	24	25	26	27
Initial	3,3,5,4	3,3,4,4	3,4,4,3	3,3,4,3	3,3,3,4	3,4,4,5	3,4,5,5
Post-surgery	2,2,3,2	2,3,3,2	2,2,2,3	2,2,3,3	2,3,2,3	2,2,2,3	2,2,3,2
Post-treatment	2,2,2,3	2,2,3,2	2,2,3,3	2,2,2,3	2,2,2,3	2,2,3,3	2,2,3,2
	31	32	33	34	35	36	37
Initial	2,3,3,3	3,4,3,3	3,4,4,3	3,4,4,4	3,4,3,4	3,3,4,4	2,3,4,4
Post-surgery	2,2,2,2	2,2,3,2	2,2,2,3	2,2,3,2	2,2,3,3	2,2,3,3	2,3,3,2
Post-treatment	2,2,2,2	2,2,3,2	2,2,3,3	2,2,3,2	2,2,3,3	2,2,3,2	3,2,3,2
	41	42	43	44	45	46	47
Initial	2,2,3,3	2,2,3,3	2,3,4,3	2,4,2,3	2,3,4,2	2,4,2,3	2,2,4,4
Post-surgery	2,2,2,3	2,2,2,2	2,2,3,3	2,2,2,3	2,2,2,3	2,3,2,3	2,3,3,3
Post-treatment	2,2,2,3	2,2,3,3	2,2,2,3	2,2,3,2	2,2,3,3	2,3,3,3	2,3,3,3

**Table 2:** Cephalometric measurements.

	Pre-treatment	Post-treatment
Skeletal		
SNA (°)	76.6	76.7
SNB (°)	70.6	71.9
ANB (°)	6.0	4.8
FMA (°)	38.2	37.4
Dental		
U1-SN (°)	93.3	96.1
U1-NA (°)	16.6	19.3
U1-NA (mm)	2.9	4.0
L1-MP (°)	94.0	89.1
L1-NB (°)	34.3	30.2
L1-NB (mm)	9.4	8.4
U1-L1 (°)	123.0	125.6
Soft tissue		
E-line/UL (mm)	1.4	0.5
E-line/LL (mm)	3.6	2.0

ANB: A point, nasion, B point, FMA: Frankfort mandibular plane angle, L1: Lower central incisor, LL: Lower lip, MP: Mandibular plane, NA: Nasion point A, NB: Nasion point B, SNA: Sella nasion point A, SNB: Sella nasion point B, U1: Upper central incisor, UL: Upper lip

0.022 × 0.028-inch ceramic brackets (IceLine, Medico, Korea). In the initial alignment phase, nickel-titanium round archwires were used in combination with open coil springs to gain space for the maxillary right canine. After 1 month, four mini-screws (diameter, 2.0 mm; length 12 mm; Medico, Korea) were implanted in the palatal alveolar bone and mandibular buccal shelf to apply distalizing forces for space creation. In the lower arch, the forces were applied by power chains from mini-screws to lateral incisor brackets to correct rotation simultaneously. In the upper arch, the power chains were placed to the maxillary left first premolar and right canine brackets.



**Figure 2:** Pre-treatment radiographs and tracing.

After the leveling and alignment stage, upper and lower incisors were proclined despite buccal segment distalization and many black triangles resulted [Figure 3]. Interproximal stripping was performed on both arches from left to right first molars to retract proclined incisors and decrease black triangle size. Each interproximal contact was reduced by 0.5 mm of enamel so a total of 5.5 mm of space was created in each arch. When the main archwire reached 0.016 × 0.016-inch stainless steel in the upper arch, entire



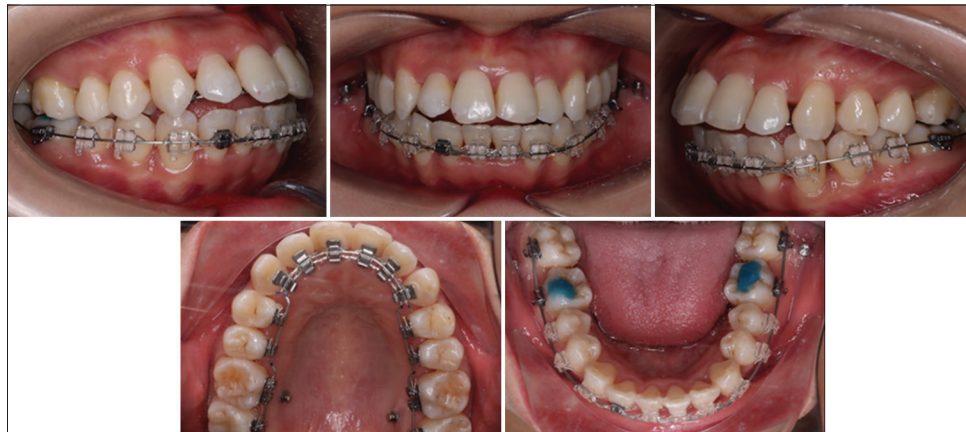arch distalization was initiated to further upright upper incisors. With the main archwire of 0.018 × 0.025-inch stainless steel in the lower arch, the distalizing force was only applied to the lower left quadrant to maintain dental Class I on the left side, allowing correction of dental Class II on the right side, and shift the lower dental midline to the left side. The total active treatment time was 14 months.

**Treatment results**

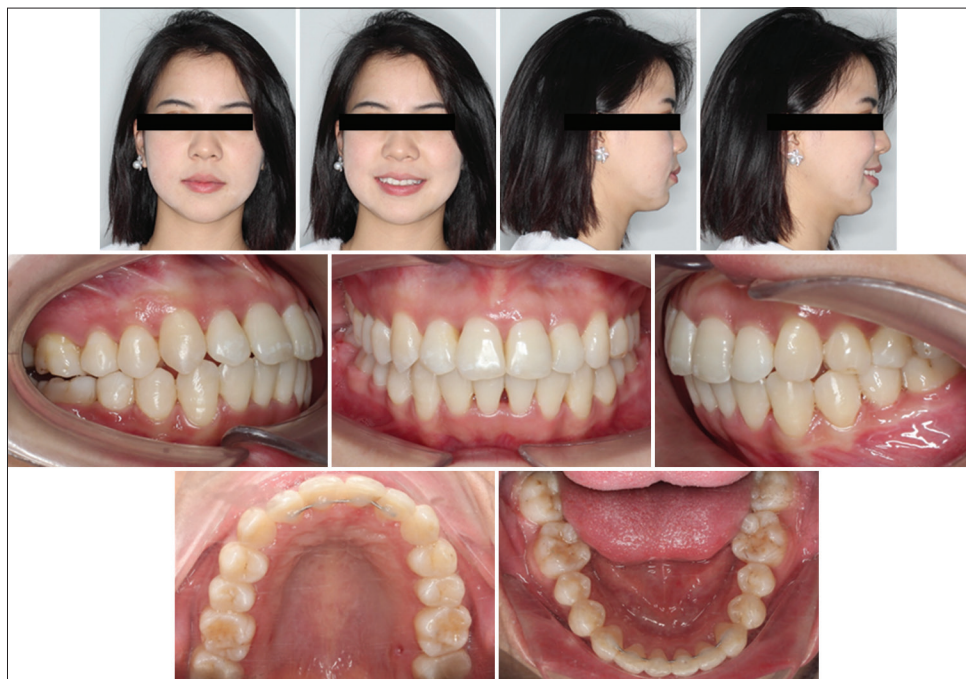The post-treatment records showed improved smile esthetics and occlusion [Figure 4]. Canine and molar Class I relationship was achieved on both sides with normal overbite

and overjet, the lower midline coincided with the upper and facial midline. The probing depth was reduced and gingival health was in a normal state.

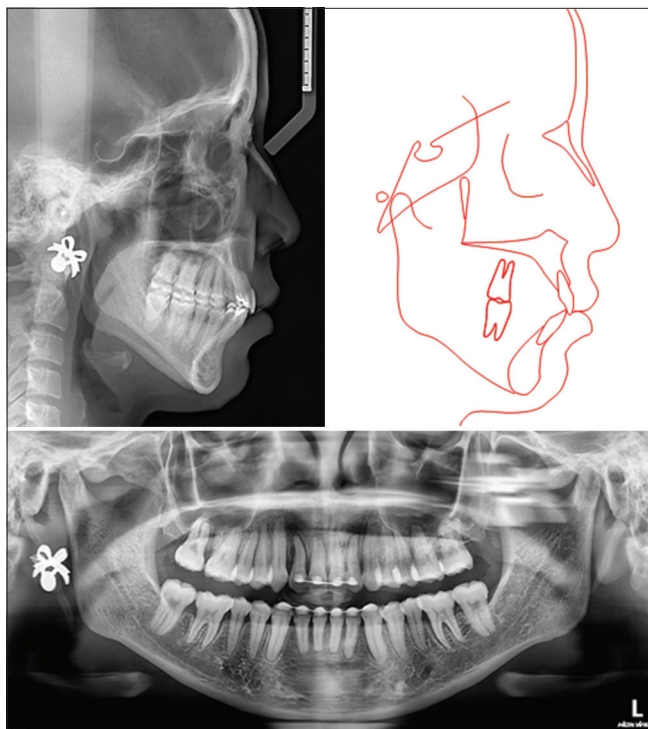
The panoramic radiograph showed adequate root parallelism without root resorption and the alveolar bone height was well maintained [Figure 5]. The cephalometric analysis confirmed the improvement of the skeletal Class II relationship (ANB, 4.8°) and hyperdivergent facial pattern (FMA, 37.4°). The retroclined upper incisors and proclined lower incisors were improved (U1-SN, 96.1°, L1-MP, 89.1°). On superimposition, the upper first molars were distalized by 2.1 mm and distally tipped by 4.8°, and the lower first molars were distalized by 1.8 mm and distally tipped by 2.1°



**Figure 3:** Proclining of upper and lower incisors after leveling and alignment stage. Four mini-screws had been inserted in the palatal alveolar bone and mandibular buccal shelf.



**Figure 4:** Post-treatment facial and intraoral photographs.



**Figure 5:** Post-treatment radiographs and tracing.

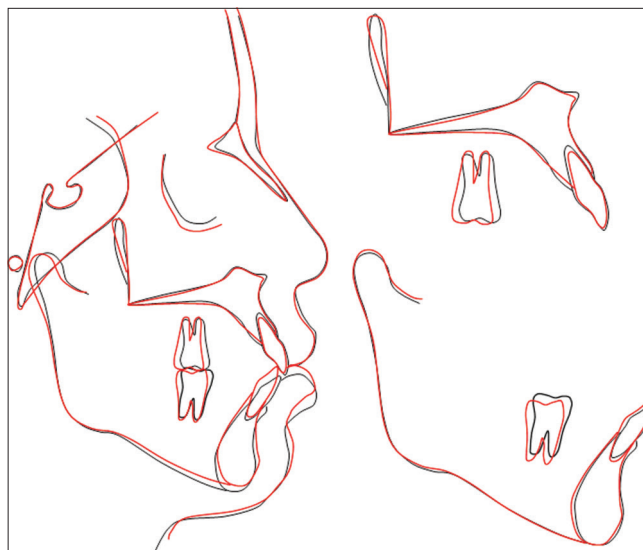[Figure 6]. The upper and lower lips were slightly retracted (E-line/UL, 0.5 mm; E-line/LL, 2.0 mm).

## DISCUSSION

In patients with reduced periodontal attachment, a non-extraction orthodontic treatment plan may benefit from less inflammation reaction due to less total treatment time and a shorter distance of tooth movement compared to an extraction one. Orthodontic extraction may also cause further attachment loss which is unfavorable in these patients.<sup>[7]</sup> However, adequate space creation needs to be performed to avoid moving teeth beyond the alveolar bone housing. Interproximal stripping in combination with mini-screw assisted total arch distalization could be an effective space creation approach in non-extraction cases.<sup>[8]</sup>

Interproximal stripping is recommended in cases of triangular-shaped teeth with multiple gingival black triangles like the patient in this case report.<sup>[9]</sup> Changing the interproximal contact points to interproximal contact areas could increase the stability of rotation correction.<sup>[10]</sup> Interproximal stripping should be performed after the alignment phase to improve access to interproximal areas.<sup>[11]</sup> After the procedure, the abraded enamel surface should be remineralized with topical fluoride to reduce sensitivity and caries incidence.

Lingual appliances have some biomechanical differences from labial brackets which are favorable in non-extraction cases.



**Figure 6:** Overall and regional cephalometric superimpositions: black - Pre-treatment, red - Post-treatment.

Intrusion force vectors applying to incisor lingual brackets pass lingually to the center of resistance of incisors resulting in less incisor proclination after leveling and alignment stage.<sup>[12]</sup> The bite plane effect of upper incisor lingual brackets also facilitates deep bite correction and applying uprighting force to upper and lower incisors. This patient would have benefited from these advantages if she had been treated with lingual brackets in the lower arch; however, the labial ceramic bracket was chosen because of reduced cost.

## CONCLUSION

Interproximal stripping in combination with mini-screw-assisted entire arch distalization and lingual appliances may be an effective space-creation approach in periodontally compromised patients treated with non-extraction way.

### Ethical approval

The Institutional Review Board approval is not required.

### Declaration of patient consent

The authors certify that they have obtained all appropriate patient consent.

### Financial support and sponsorship

Nil.

### Conflicts of interest

There are no conflicts of interest.

### Use of artificial intelligence (AI)-assisted technology for manuscript preparation

The authors confirm that there was no use of artificial intelligence (AI)-assisted technology for assisting in the writing or editing of the manuscript and no images were manipulated using AI.

### REFERENCES

1. Xie Y, Zhao Q, Tan Z, Yang S. Orthodontic treatment in a periodontal patient with pathologic migration of anterior teeth. *Am J Orthod Dentofacial Orthop* 2014;145:685-93.
2. Zaveri PK. Orthodontic management of a periodontally compromised dentition. *APOS Trends Orthod* 2016;6:31-8.
3. Tavares CA, Allgayer S, da Silva Calvete E, Polido WD. Orthodontic treatment for a patient with advanced periodontal disease: 11-year follow-up. *Am J Orthod Dentofacial Orthop* 2013;144:455-65.
4. Nguyen VA, Nguyen TT, Nguyen TT. Management of an adult patient with missing one mandibular incisor, severe overjet, and midline discrepancy with asymmetric extraction, lingual appliance, and skeletal anchorage: A case report. *J World Fed Orthod* 2020;9:86-94.
5. Ngoc VT, Phuong NT, Anh NV. Skeletal Class III malocclusion with lateral open bite and facial asymmetry treated with asymmetric lower molar extraction and lingual appliance: A case report. *Int J Environ Health Res Public Health* 2021;18:5381.
6. Anh NV, Ngoc VT, Ha TT. Severe overjet and deep overbite correction by en masse distalization using lingual appliances and mini-implant Anchorage: Two case reports. *Clin Investig Orthod* 2022;81:217-28.
7. Artun J, Osterberg SK. Periodontal status of teeth facing extraction sites long-term after orthodontic treatment. *J Periodontol* 1987;58:24-9.
8. Verma P, George AM. Efficacy of clear aligners in producing molar distalization: Systematic review. *APOS Trends Orthod* 2022;11:317-24.
9. Ziahosseini P, Hussain F, Millar BJ. Management of gingival black triangles. *Br Dent J* 2014;217:559-63.
10. Frindel C. Clear thinking about interproximal stripping. *J Dentofacial Anom Orthod* 2010;13:187-99.
11. Livas C, Jongsma AC, Ren Y. Enamel reduction techniques in orthodontics: A literature review. *Open Dent J* 2013;7:146-51.
12. Anh NV, Tra NT, Hanh NT. Lingual orthodontic treatment of a skeletal class II patient with miniscrew-assisted absolute anchorage in maxillary arch and total distalization in mandibular arch: A case report. *Orthod Waves* 2021;80:97-106.

**How to cite this article:** Son T, Ngoc V, Anh N. Management of an adult patient with severe crowding using lingual appliances and mini-screw anchorage: A case report. *APOS Trends Orthod.* 2024;14:191-6. doi: 10.25259/APOS\_46\_2023