



Case Report

Immediate retrieval of an accidentally ingested tube pre-welded molar band from stomach – A case report

J. Mohamed Iqbal¹, B. Balashanmugam¹, M. Keerthana¹

¹Department of Orthodontics and Dentofacial Orthopedics, Tamil Nadu Government Dental College and Hospital, Chennai, Tamil Nadu, India.



*Corresponding author:

J. Mohamed Iqbal,
Department of Orthodontics
and Dentofacial Orthopedics,
Tamil Nadu Government
Dental College and Hospital,
Chennai, Tamil Nadu, India.


mohamediqbalortho@gmail.com

Received: 03 March 2023
Accepted: 11 June 2023
Epub Ahead of Print: 07 July 2023
Published: 06 August 2024

DOI
10.25259/APOS_50_2023

Video available online at:
https://doi.org/10.25259/APOS_50_2023

Quick Response Code:



ABSTRACT

Accidental ingestion or aspiration of dental foreign bodies is a life-threatening medical emergency. Orthodontic materials such as brackets, bands, wire segments, and appliances are the second most common of foreign bodies to be ingested. Immediate retrieval from the stomach before the object passes the duodenal sweep is recommended. This article reports a case of retrieval of accidentally ingested tube pre-welded molar band within 45 min of ingestion, using endoscopy.

Keywords: Orthodontic foreign body, Accidental ingestion, Immediate retrieval, Endoscopy

INTRODUCTION

Dental foreign body ingestion is a rare but life-threatening medical emergency. These objects are either aspirated or ingested.^[1] Ingestion is shown to be more prevalent than aspiration.^[2] Orthodontic materials in the form of wire segments, brackets, and molar bands are the second most common of dental foreign bodies to be ingested.^[3] Majority of ingested smooth dental foreign bodies that have passed the duodenal sweep pass through the gastrointestinal (GI) tract uneventfully while materials with rough surfaces and projections pose risk of obstruction, impaction, or fatal perforation.^[4] Patient anxiety and possible malpractice litigation are other possible concerns. We report a case of accidental ingestion of a tube pre-welded molar band at the time of luting. The foreign body with a projecting hook was located in the stomach within an hour and was retrieved using endoscopy.

CASE REPORT

A 14-year-old male patient reported to the outpatient clinic for his orthodontic treatment with fixed appliance mechanotherapy. During the try in of a tube pre-welded molar band in the lower left mandibular first permanent molar, the band dropped into the lingual vestibule and the patient accidentally swallowed it. The patient was positioned supine during the procedure. He was immediately made to turn to his side and a swift examination under bright light was done inside the oral cavity to rule out its presence there. The oral cavity was clear. The patient was asked to cough vigorously to evict the band from oropharynx. Following failure of this exercise, the patient and the parent were informed of the accident and its implication. They were apprised of the management protocol and taken for X-rays. Lateral and posteroanterior views of the X-ray [Figure 1] did not reveal the presence of the band. A computed tomography

This is an open-access article distributed under the terms of the Creative Commons Attribution-Non Commercial-Share Alike 4.0 License, which allows others to remix, transform, and build upon the work non-commercially, as long as the author is credited and the new creations are licensed under the identical terms.

©2024 Published by Scientific Scholar on behalf of APOS Trends in Orthodontics

was taken which revealed the band as a hyper dense field in the stomach [Figure 2]. The patient was taken for a gastroenterological consultation where an endoscopy was advised. The band was located and retrieved by endoscopy without complication [Figures 3 and 4] [Video 1].

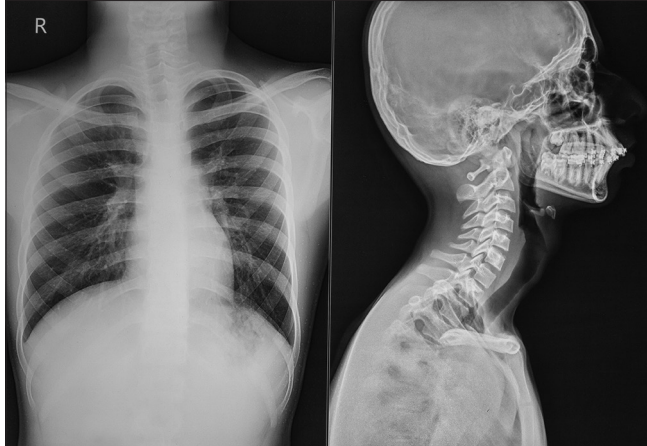


Figure 1: Posteroanterior view and lateral view of chest.

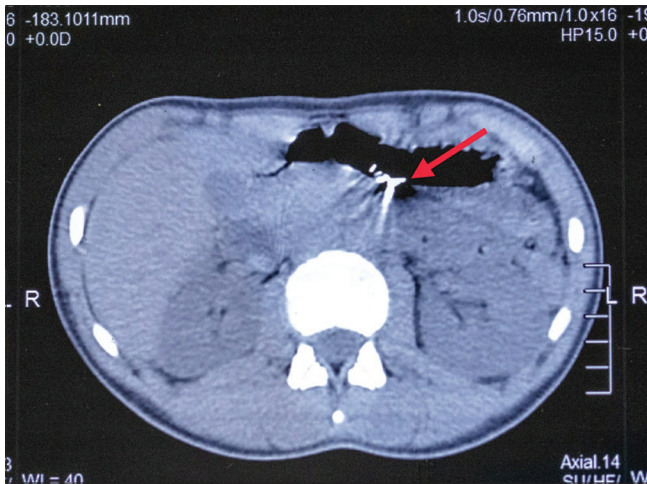


Figure 2: CT image showing band as a hyper dense field (red arrow).




Figure 3: Band location and retrieval by endoscopy.

DISCUSSION

Supine position of patient during orthodontic procedures, small size of objects, and salivary field of work have been attributed as factors that predispose orthodontic materials for accidental ingestion.^[5] About 92.5% of swallowed foreign bodies have been shown to enter the GI tract while 7.5% are aspirated into the tracheobronchial system.^[6] Cleft lip/palate patients with compromised velopharyngeal competency and patients with reduced laryngeal closure are at risk of aspiration compared to others.^[7] Ingested foreign bodies have a spectrum of sequelae. Majority of them that have passed the Duodenal sweep exit the GI tract asymptotically within 3 days of ingestion.^[8,9] However obstruction or impaction in cases of objects with projections as in this instance of a hook in the band can result in dysphagia, abdominal pain, abdominal distention, sepsis, and perforation which can be fatal.^[4] Early location and an immediate attempt to remove the object are the preferred protocol. In our case, immediate location and



Figure 4: Retrieved molar band.



Video 1: Endoscopy video.

referral resulted in an uneventful resolution of the crisis that would have otherwise resulted in patient anxiety which is an important ethical and medicolegal concern.

Recommended precautions

A cautious clinical protocol can effectively prevent this avoidable phenomenon of accidental ingestions. The following recommendations have been proposed as preventive measures.^[10]

1. Distractions during procedures such as mobile phones need to be avoided both by the patient as well as the auxiliaries
2. A textured glove is recommended for better grip
3. A high speed suction with pharyngeal tip should be at hand during intraoral procedures
4. Activation keys, molar bands, and palatal arches should always be secured with sterile threads or floss during activation, fit checks, and insertions, respectively
5. Gauze pads should be placed as barriers
6. Distal end cutters should be examined for cut ends after use and trapped tips removed before the next use
7. Safety holds of distal end cutters should be periodically checked and replaced in case of failure
8. Mini screws temporary anchorage devices (TADs) should be tied to the primary arch wire with ligatures
9. Review appointments for patients complaining loose components should not be delayed and necessary adjustments should be done forthwith
10. All intra oral appliances should be having a radio opaque component to help in radiographic visualization and they also need to be checked for sharp edges, margins, and failure margins.

CONCLUSION

Accidental ingestion of orthodontic materials is an avoidable medical emergency. Supine patient position, salivary field, and small size of objects make orthodontic materials prone for accidental ingestion. This however is not a justification for an accident. All necessary precautions should be taken to prevent such an occurrence. In the event that it occurs, early location and retrieval, particularly of materials with projections and rough surfaces, are the preferred management.

Ethical approval

The Institutional Review Board approval is not required.

Declaration of patient consent

The authors certify that they have obtained all appropriate patient consent.

Financial support and sponsorship

Nil.

Conflicts of interest

There are no conflicts of interest.

Use of artificial intelligence (AI)-assisted technology for manuscript preparation

The authors confirm that there was no use of artificial intelligence (AI)-assisted technology for assisting in the writing or editing of the manuscript and no images were manipulated using AI.

REFERENCES

1. Milton TM, Hearing SD, Ireland AJ. Ingested foreign bodies associated with orthodontic treatment: Report of three cases and review of ingestion/aspiration incident management. *Br Dent J* 2001;190:592-6.
2. Kurkciyan I, Frossard M, Kettenbach J, Meron G, Sterz F, Roggla M, *et al.* Conservative management of foreign bodies in the gastrointestinal tract. *Z Gastroenterol* 1996;34:173-7.
3. Tiwana KK, Morton T, Tiwana PS. Aspiration and ingestion in dental practice: A 10-year institutional review. *J Am Dent Assoc* 2004;135:1287-91.
4. Cockerill FR 3rd, Wilson WR, Van Scoy RE. Travelling tooth picks. *Mayo Clin Proc* 1983;58:613-6.
5. Kharbanda OP, Varshney P, Dutta U. Accidental swallowing of a gold cast crown during orthodontic tooth separation. *J Clin Pediatr Dent* 1995;19:289-92.
6. Webb WA, McDaniel L, Jones L. Foreign bodies of the Upper Gastrointestinal tract: Current management. *South Med J* 1984;77:1083-6.
7. Yadav RK, Yadav HK, Chandra A, Yadav S, Verma P, Shakya VK. Accidental aspiration/ingestion of foreign bodies in dentistry: A clinical and legal perspective. *Natl J Maxillofac Surg* 2015;6:144-51.
8. Christopher C, Thompson MD. Gastrointestinal foreign bodies. In: *Current Diagnosis and Treatment-Gastroenterology, Hepatology and Endoscopy*. 1st ed. New York: McGraw Hill Companies; 2009.
9. Kuo SC, Chen YL. Accidental swallowing of an endodontic file. *Int Endod J* 2008;41:617-22.
10. Mahto RK, Rana SS, Kharbanda OP. Accidental swallowing of a molar band. *Turk J Orthod* 2019;32:115-8.

How to cite this article: Mohamed Iqbal J, Balashanmugam B, Keerthana M. Immediate retrieval of an accidentally ingested tube welded molar band from stomach – A case report. *APOS Trends Orthod.* 2024;14:197-9. doi: 10.25259/APOS_50_2023