

# Evaluating condylar head morphology as it relates to the skeletal vertical facial dimension: A three-dimensional semi-automated landmark study

Curtis Contro,  
Arthur J. Miller<sup>1</sup>,  
David Hatcher<sup>1,2</sup>,  
Snehlata Oberoi<sup>3</sup>

Private Practice, Palo Alto and  
Cupertino, CA, <sup>1</sup>Division of  
Orthodontics, Department of  
Orofacial Sciences, School of  
Dentistry, University of California,  
<sup>2</sup>DDI Imaging Center, Sacramento,  
California, <sup>3</sup>Division of Craniofacial  
Anomalies, Department of Orofacial  
Sciences, School of Dentistry,  
University of California,  
San Francisco, California, USA

## Abstract

**Introduction:** Condylar growth direction and rotation affect the occlusion, especially in the vertical dimension. The first objective of this study was to evaluate the reliability of a novel three-dimensional semi-automated landmark computer software on mapping the head of the mandibular condyle using cone-beam computed tomography (CBCT). The second objective was to evaluate qualitatively how condylar morphology differs three-dimensionally according to skeletal vertical pattern and mandibular morphology in healthy adults using CBCT. **Materials and Methods:** A total of 242 (169 females and 73 males) participants were eligible for the study. Participants were selected at random from the 242 to create three groups of 10 participants based on their MP-SN<sup>o</sup> and assigned to a brachyfacial group, dolichofacial group, and mesofacial group. The thirty participants were also divided by mandibular symphyseal morphology according to the chin angle (Id-Pg-MP<sup>o</sup>). Each subject's condyles were landmarked using Stratovan's Checkpoint software. A Procrustes analysis was then used to generate an average condylar shape for each of the six groups from which to evaluate shape differences. **Results:** Checkpoint proved to be a reliable method of placing landmarks on the condyle with a low coefficient of variation of 1.81% (standard deviation/mean). Qualitative analysis of the Procrustes averages revealed brachyfacial average showed a moderate anterior lean from the sagittal, anterior convexity from the axial, and medial lean from the coronal views. The dolichofacial average showed a mild anterior lean from the sagittal, anterior concavity from the axial, and a symmetrical half-dome shape from the coronal. The obtuse chin angle group average displayed morphology similar to the brachyfacial average, whereas the acute chin angle group average displayed morphology similar to the dolichofacial average. **Conclusions:** Checkpoint is reliable software to landmark the temporomandibular joint. There are differences in average morphologies between all groups.

**Key words:** Condyle, cone beam computed tomography, temporomandibular joint, three-dimensional

## Access this article online

### Quick Response Code:



### Website:

www.apospublications.com

### DOI:

10.4103/2321-1407.190724

This is an open access article distributed under the terms of the Creative Commons Attribution-NonCommercial-ShareAlike 3.0 License, which allows others to remix, tweak, and build upon the work non-commercially, as long as the author is credited and the new creations are licensed under the identical terms.

For reprints contact: reprints@medknow.com

## Address for Correspondence:

Dr. Snehlata Oberoi, D3000, 707 Parnassus Avenue,  
San Francisco, CA 94143, USA.  
E-mail: sneha.oberoi@ucsf.edu

**How to cite this article:** Contro C, Miller AJ, Hatcher D, Oberoi S. Evaluating condylar head morphology as it relates to the skeletal vertical facial dimension: A three-dimensional semi-automated landmark study. APOS Trends Orthod 2016;6:238-45.

## INTRODUCTION

Orthodontics has traditionally borrowed much of its analysis of the human craniofacial complex from anthropometry. Many of the anatomical landmarks we use to describe a patient's lateral cephalogram were used in anthropology.<sup>[1]</sup> Since morphology plays an integral role in diagnosis and treatment, it is important to understand what makes the craniofacial complex of some individuals different from others.

With the advent and popularization of cone-beam computed tomography (CBCT), orthodontists today are seeing clearer and more detailed images of the craniofacial complex in three dimensions than ever before.<sup>[2,3]</sup>

CBCT overcomes many of the shortcomings of CT which is expensive,<sup>[4]</sup> and magnetic resonance which is time-consuming.<sup>[5]</sup> Moreover, the information gained from a CBCT is far more accurate and reliable when evaluating the temporomandibular joint (TMJ) and mandible.<sup>[6]</sup> CBCT is the method of choice when evaluating condylar morphology.<sup>[5,7]</sup>

Kikuchi *et al.* used tomograms and lateral cephalograms to examine the relationship between craniofacial morphology and condylar position and joint morphology.<sup>[8]</sup> They found that the condyle was more likely to exhibit a posterior position in the glenoid fossa when the mandible exhibited a clockwise rotation, suggesting that the vertical dimension of the craniofacial complex shares an intimate relationship with TMJ morphology. While this study did use three-dimensional data, it used slices to make its evaluation, essentially converting three-dimensional data into two-dimensional data. This conversion detracts from the value of the morphological data as it confines it into discrete planes of space. Cevidanes *et al.* explored changes to the condyle after surgical manipulation of the maxilla and mandible using three-dimensional color mapping and thereby maintaining their data in its raw form for analysis. They found this method allowed for clear identification of the location, magnitude, and direction of mandibular displacement as a result of the treatment.<sup>[9]</sup> This method, however, gives a general idea of changes seen but fails to evaluate three-dimensional changes on a more descriptive scale. Schilling *et al.* saw the value of maintaining three-dimensional data in its raw form for analysis when they explored the reliability of three-dimensional registration and superimposition methods for the assessment of TMJ condylar morphology across participants and longitudinally.<sup>[10]</sup> They found landmark-based and voxel-based techniques to be reliable and useful to quantify subtle bony differences in the three-dimensional condylar morphology.

The mandibular condyle can be mapped in three dimensions by Checkpoint (Stratovan Corporation, Sacramento, CA, USA). This semi-automated three-dimensional analysis maps the head of the condyle to give an accurate three-dimensional representation. Placing landmarks in two-dimensional slices of three-dimensional data has been shown to be reliable, and a novel three-dimensional analysis to evaluate TMJ shape and space has been recently described.<sup>[11,12]</sup> It is the intention of this study to show that Checkpoint offers a predictable and reliable method for placing landmarks on three-dimensional surface data through the use of semi-automation.

While no two condyles may be exactly the same in shape and form, groups of them look similar. Being a main growth site for the mandible, which, in turn, can dictate the malocclusion that presents, it becomes highly important to establish norms for condylar shape. This variation in condylar shape is due to the fact that the mandibular condyle is a growth site for the mandible. Condylar growth is genetically determined in each patient. Direction of condylar growth has a direct impact on an individual's skeletal vertical pattern. Typically, people with a hypodivergent skeletal pattern have upward and forward growth of the condyle, whereas people with a hyperdivergent skeletal pattern have upward and backward growth of the condyle. It stands to reason that these types of growth patterns would lead to differences in the shape development of the condyle.

Skieller *et al.* showed this to be the case in their study of measurements which, when taken together, gave an 86% prognostic estimate of mandibular growth rotation. They placed metallic implants on 21 prepubescent children to observe mandibular growth rotation. They found that the majority of the prognostic ability depended on the following four cephalometric values: mandibular plane angle, intermolar angle, mandibular lower border curvature, and the mandibular symphysis inclination.<sup>[13]</sup>

Skieller *et al.*, found that a subject was more likely to exhibit a backward growth rotation of the mandible with a mandibular lower border that is straight and a symphysis characterized by proclination. Conversely, a subject was more likely to exhibit a forward growth rotation of the mandible when he or she exhibited a curved mandibular lower border and retroclination of the symphysis.<sup>[13]</sup>

The purpose of this present study is to evaluate three-dimensional differences in mandibular condylar morphology based on skeletal vertical patterns as well as specific two-dimensional mandibular morphological characteristics, using the Checkpoint landmark software. We hypothesize that condylar head morphology will vary

based on the skeletal vertical pattern (i.e., mandibular plane angle), as well as mandibular morphology, as recognized by symphyseal inclination.

The aims of this study are as follows:

1. To determine the reliability of the three-dimensional semi-automated landmark software, Checkpoint, within and between raters
2. To determine qualitative three-dimensional differences in condylar morphology in healthy adults seeking CBCT scans, based on skeletal vertical pattern
3. To determine differences in condylar morphology in healthy adults seeking CBCT scans, based on two-dimensional mandibular symphyseal inclination.

## MATERIALS AND METHODS

### Participants

An initial retrospective, convenience sample of 606 anonymous DICOM cone beam CT data was obtained from DDI Imaging Center in Sacramento, CA. All scans were taken using the i-CAT Cone Beam 3D Imaging System (Imaging Sciences International Inc., Hartfield, PA, USA) with the participants in an upright sitting position and with the patients' Frankfort horizontal plane parallel to the floor. The scanning settings for the CBCT machine were as follows: 120 kVP tube voltage, 18.45–47.74 mA tube current, and 20-second scan time. Of this sample, 423 were female and 183 were males, ranging in age from 18 to 90 years old. The initial sample was organized by the imaging center by decades of age as well as gender. No other demographic information was available on the participants. Using the following inclusion and exclusion criteria, a sample of 242 participants was compiled. This sample included 169 females and 73 males, which were considered eligible for the purpose of this study. The inclusion criteria for the study were adult patients of 18 years of age or older, scans that included the entire mandible as well as up to the cephalometric landmark nasion.

Exclusion criteria were radiographically visible condylar pathology past or present, radiographically visible mandibular asymmetry, postorthognathic surgery scans, participants with craniofacial anomalies, participants lacking posterior vertical dental stops, poor scan resolution, and scans not taken in maximum intensity projection.

### Cephalometrics

Each of the 242 CBCT scans was loaded into the Anatomage InVivo software (Anatomage, San Jose, CA, USA) to generate traditional lateral cephalograms from the three-dimensional data. The lateral cephalograms were

loaded into Dolphin Imaging (Dolphin, Chatsworth, CA, USA) and digitally traced. The following measurements were obtained on each subject's skeletal vertical pattern: MP-SN°, Ar-Go-Me°, as well as the ratio between posterior face height (S-Go) and anterior face height (N-Me). The following angle, under the Bjork II analysis in Dolphin Imaging software, was used to classify mandibular symphysis morphology: Id-Pg-MP°.

### Semi-automated three-dimensional condylar landmark placement

The computer software Checkpoint (Stratovan Corporation, Davis, CA, USA) was used to map the condylar head by two different investigators according to the methods seen in the recent study done by Ikeda. Scans were loaded, adjusted for proper contrast, and oriented into natural head position. Next, the scans were cropped to include the entire condylar head and full surface of the glenoid fossa. The cropped volumes were then adjusted for proper contrast and oriented through the medial and lateral poles in the axial plane. Next, the isosurface was adjusted for optimal condylar head and fossa surface representation. Then, the anchor points were placed on the medial and lateral poles as well as the posterior point described by Ikeda *et al.* From these equator points, the program extrapolated 119 additional points according to a patch density of 11 × 11. Each semi-automated landmark was then manually adjusted for accuracy.

A random number generator was used to determine which patients would be landmarked. Ten dolichofacial patients, ten mesofacial patients, and ten brachyfacial patients were obtained for landmark placement from the original sample of 242 participants. Fifteen additional participants were excluded from the study after their random selection due to incompatible scan resolution with the landmark software. Of these 30 participants, 27 were female and 3 were male. Fourteen of the thirty participants were between the ages of 18 and 30 at the time of scan. Eight were between the ages of 31 and 40 at the time of scan. Five were between the ages of 41 and 50 at the time of scan. One subject was between the age of 51 and 60 at the time of scan. Two participants were between the ages of 51 and 60 at the time of scan. Inter/intra-rater reliability testing was performed using five participants measured by two different investigators, at two different time points.

A qualitative analysis was done by dividing the sample into three different groups, based on MP-SN°. The brachyfacial group was defined as any measurement that was more than one standard deviation below the norm. The dolichofacial group was defined as any subject that was more than one standard deviation above the norm. The mesofacial

group was defined as everything in between the previously mentioned groups. The same was done to create the chin angle groups based on the Id-Pg-MP°. The obtuse chin angle group was participants with the chin angle more than one standard deviation above the norm. The acute chin angle group was created based on a chin angle that was more than one standard deviation below the norm. The normal chin angle group was all the participants between those two groups. A Procrustes analysis was used to generate a mean condylar shape for each of the six groups. These six groups were then compared qualitatively for differences in morphology.

## RESULTS

### Reliability testing

The interobserver reliability was compared between two judges over two-time points and demonstrated a low coefficient of variation of 1.81% (standard deviation/mean). The Bland–Altman indicated a mean difference of 0.344 mm on average measurements of 55.232 [Figures 1 and 2].

### Sample characteristics

For the dolichofacial patients, the mean mandibular plane angle was 41.6°. For the mesofacial patients, the mean mandibular plane angle was 32.7°. For the brachyfacial patients, the mean mandibular plane angle was 22.8°.

The gonial angle varied for each of the groups with a mean angle of 125.2°, 120°, and 114.8° for dolichofacial, mesofacial, and brachyfacial, respectively.

The mean posterior-anterior face height ratio for all landmarked participants was 66.9. This ratio also varied based on the subject group with a mean of 59.9, 66, and 74.7 for the dolichofacial, mesofacial, and brachyfacial groups, respectively.

The cephalometric measurement that did not vary between the groups was the chin angle. The mean angle for all the participants was 71.9, whereas it was 71.9°, 72°, and 71.8° for the dolichofacial, mesofacial, and brachyfacial groups, respectively.

When subject groups were formed on the basis of chin angle, mean mandibular plane angles varied minimally at 34°, 30.9°, and 34.3° for the acute chin angle, normal chin angle, and obtuse chin angle groups, respectively. The gonial angle showed a decreasing trend from 124.2°, 119.2°, and 117.2° for the acute chin angle, normal chin angle, and obtuse chin angle groups, respectively. Posterior-anterior face height ratio showed no such trend with the means being 65, 68.2, and 65.3 for the acute, normal, and obtuse chin angle groups, respectively.

### Procrustes averages of the vertical facial groups

A generalized Procrustes analysis was performed on each subject group, and the Procrustes averages of each were compared qualitatively from various views for differences in shape and morphology. Differences between right and left condyles were minimal. Subtle differences can be seen between the three vertical facial pattern groups. From a frontal view of the condylar heads, the dolichofacial group average shows a more uniform and symmetrical half-dome appearance than the other two group averages. The mesofacial group average is squatter in height than the other two groups. The brachyfacial group displays a lean of the apex of the half-dome toward the medial [Figure 3].

The lateral view also shows differences between the averages. All groups show a lean of the superior part of the condylar head toward the anterior. The mesofacial and brachyfacial groups display a more pronounced lean toward the anterior than the dolichofacial but no discernable difference from each other [Figure 4].

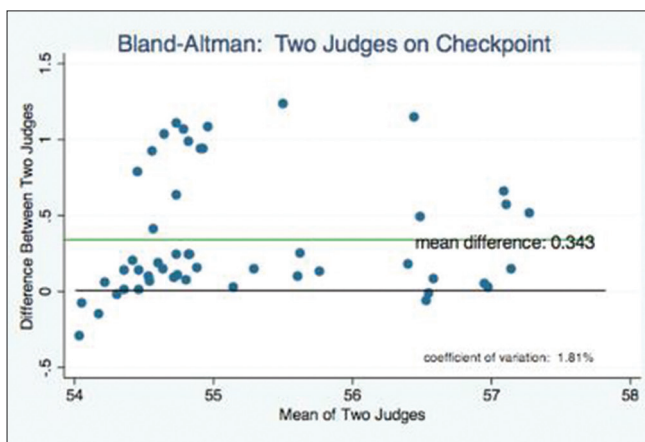


Figure 1: Bland–Altman of the two raters

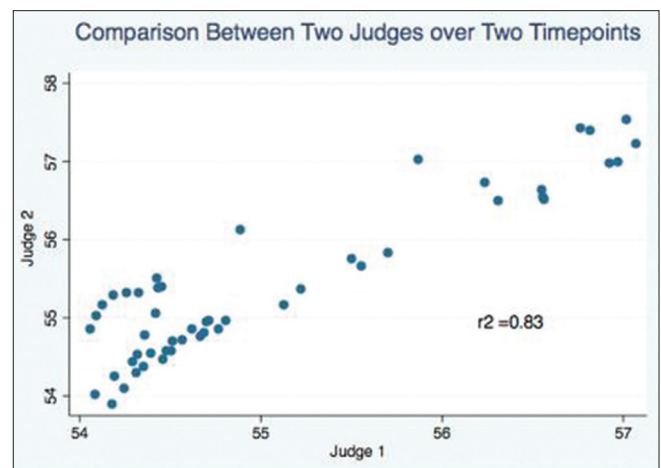


Figure 2: Correlation of the two raters



Differences between the Procrustes averages were noted from the superior view as well as, particularly on the anterior surface of the condylar head. The dolichofacial group showed a pronounced anterior concavity with anterior projections of the medial and lateral sides of the anterior surface. This concavity turns to a flat anterior surface as we look at the average shape of the mesofacial group. The brachyfacial group then shows a rounded, convex anterior surface with an overall oval shape, when viewed from the superior [Figure 5].

### Procrustes averages of the chin angle groups

From the frontal view, the acute and obtuse chin angle group averages show no obvious shape differences between their averages, but like the mesofacial group, the normal chin angle average is a mildly squatter half-dome than the acute and obtuse chin angle group averages [Figure 6].

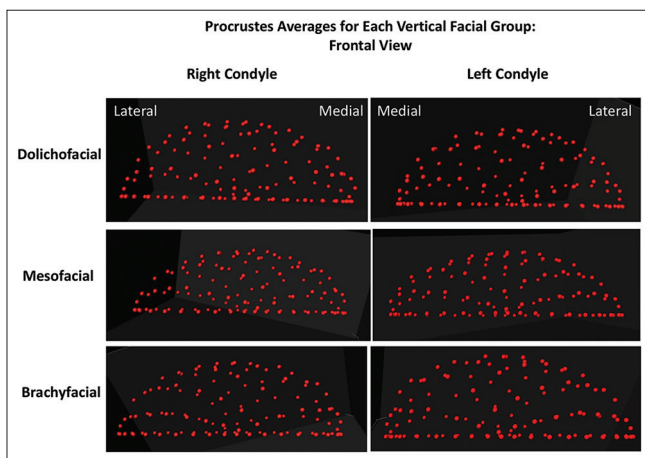
From the lateral view, the normal chin angle group average is squatter in height as well. In addition, all three groups

show an anterior lean of the apex of the half-dome of the condylar head with a more pronounced lean in the normal and obtuse chin angle group averages [Figure 7].

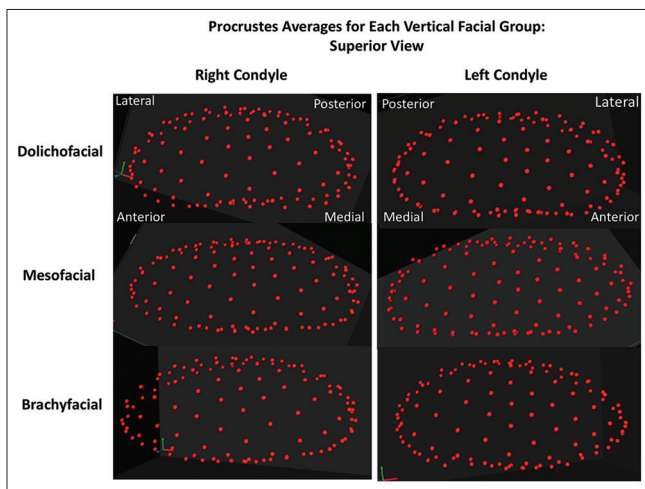
From the superior view, the acute chin angle group average shows morphology similar to the dolichofacial group average with a slight anterior concavity and medial and lateral anterior projections. The normal chin angle group average displays similar morphology to the brachyfacial group average with a rounded anterior surface and overall oval shape. The obtuse chin angle average shows morphology similar to the mesofacial group average with a flat anterior surface [Figure 8].

### Variation within sample groups

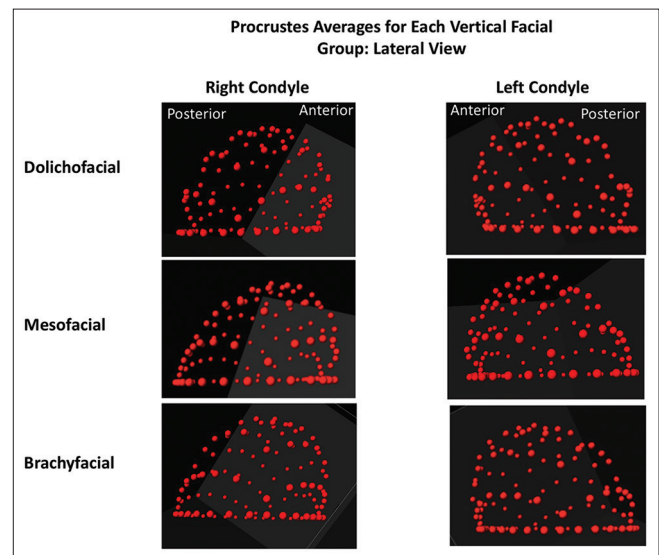
All six groups show much variation within the group with regard to the morphology of the condylar head. While the Procrustes average shape for the dolichofacial group



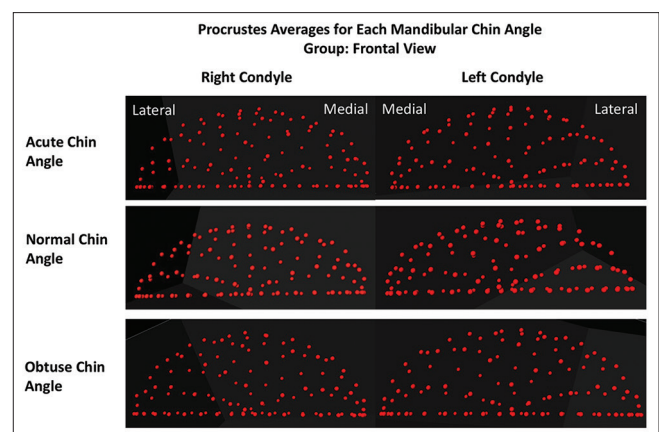
**Figure 3:** Comparison of skeletal vertical group Procrustes average morphologies, as seen from a frontal view of the condylar head



**Figure 5:** Comparison of skeletal vertical group Procrustes average morphologies, as seen from a superior view of the condylar head



**Figure 4:** Comparison of skeletal vertical group Procrustes average morphologies, as seen from a lateral view of the condylar head



**Figure 6:** Comparison of chin angle group Procrustes average morphologies, as seen from a frontal view of the condylar head

shows an anterior concavity from the superior view, the group contained individuals with no such concavity, as well as individuals with a more pronounced concavity than the average [Figure 9]. The mesofacial group shows similar variation with individuals showing a pronounced anterior concavity as well as an individual with an anterior convexity. One individual even shows a posterior lean of the apex when viewed from the lateral, differing greatly from the average [Figure 10]. The brachyfacial group also has individual variations in morphology, with participants displaying anterior concavity as well as anterior convexity [Figure 11].

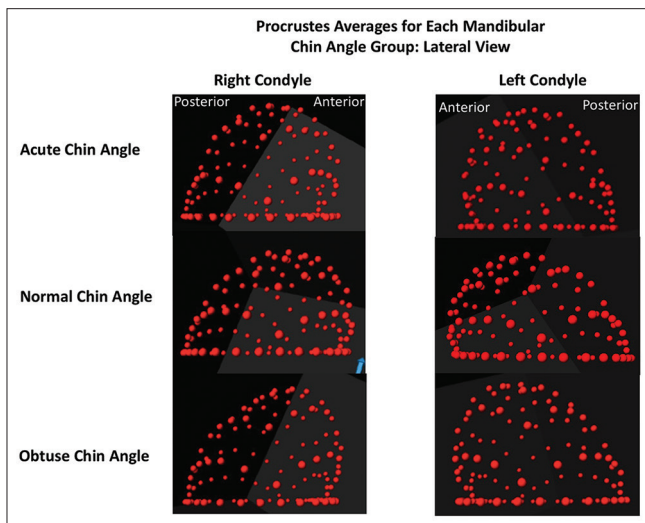
In the acute chin angle group, all participants displayed some degree of anterior concavity but notably varied in the amount of anterior lean that could be seen on a lateral view [Figure 12].

In the normal chin angle group, the amount of variation was dramatic with some participants exhibiting a pronounced anterior concavity and some exhibiting a pronounced anterior convexity. Similarly, the amount of anterior or posterior lean variation was dramatically different as well.

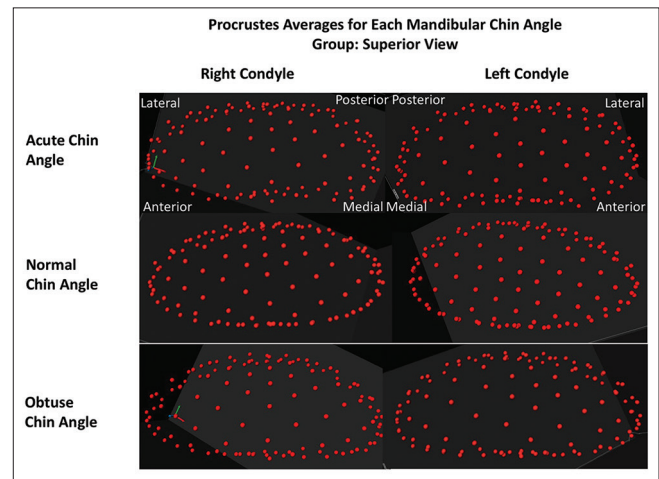
The obtuse chin angle group showed the same dramatic individual variation in the anterior surface [Figures 13 and 14].

## DISCUSSION

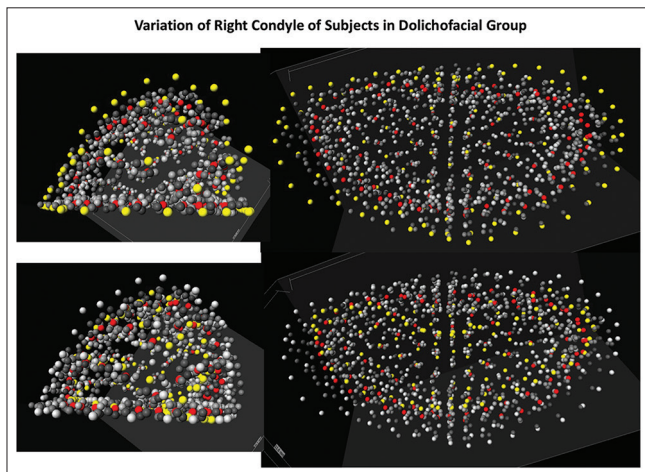
This multiple landmark method was found to be a reliable method of placing landmarks on the condylar head. The landmarks used by Ikeda *et al.* served as reliable anchor points that could be used to produce a reproducible equator at the height of the medial and lateral poles from which semi-automated landmarks could be extrapolated. Despite



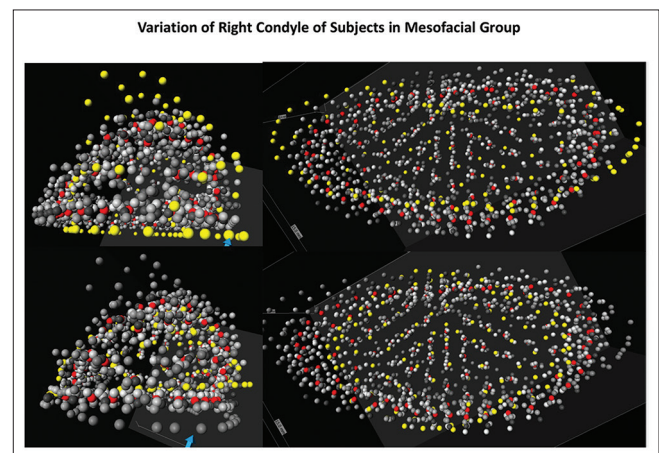
**Figure 7:** Comparison of chin angle group Procrustes average morphologies, as seen from a lateral view of the condylar head



**Figure 8:** Comparison of chin angle group Procrustes average morphologies, as seen from a superior view of the condylar head

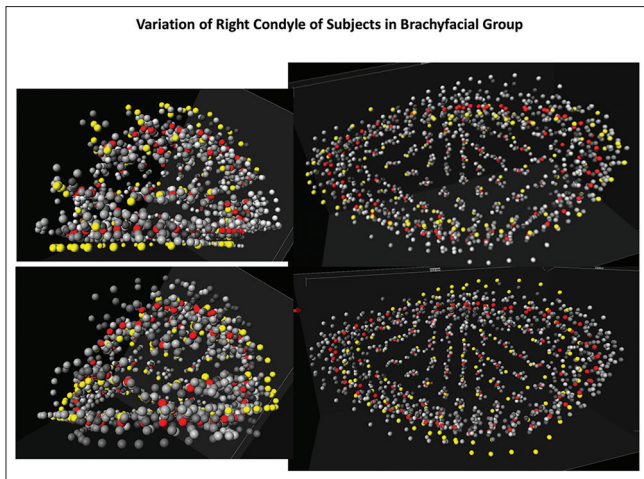


**Figure 9:** Lateral and inferior views of landmarks of the right condyle of two different participants both within the dolichofacial group. Top row shows first participant and bottom row shows second subject. Selected subject in yellow, Procrustes average for group in red, all other participants in gray




**Figure 10:** Lateral and inferior views of landmarks of the right condyle of two different participants both within the mesofacial group. Top row shows first subject and bottom row shows the second subject. Selected subject in yellow, Procrustes average for group in red, all other participants in gray






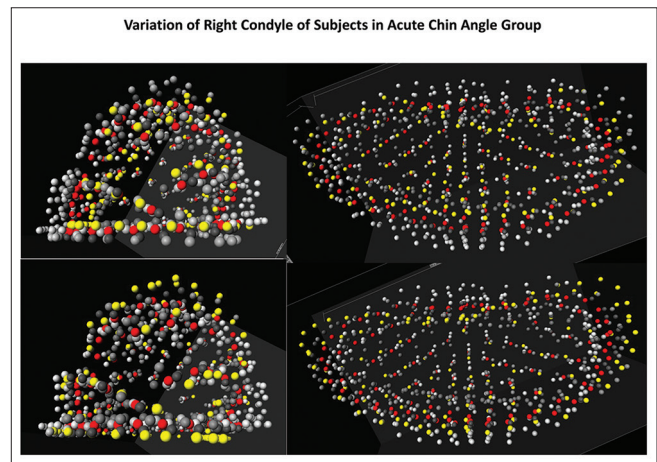
**Figure 11:** Lateral and inferior views of landmarks of the right condyle of two different participants both within the brachyfacial group. Top row shows first subject and bottom row shows the second subject. Selected subject in yellow, Procrustes average for group in red, all other participants in gray



**Figure 12:** Lateral and inferior views of landmarks of the right condyle of two different participants both within the acute chin angle group. Top row shows first subject and bottom row shows the second subject. Selected subject in yellow, Procrustes average for group in red, all other participants in gray



**Figure 13:** Lateral and inferior views of landmarks of the right condyle of two different participants both within the normal chin angle group. Top row shows first subject and bottom row shows second subject. Selected subject in yellow, Procrustes average for group in red, all other participants in gray



**Figure 14:** Lateral and inferior views of landmarks of the right condyle of two different participants both within the obtuse chin angle group. Top row shows first subject and bottom row shows second subject. Selected subject in yellow, Procrustes average for group in red, all other participants in gray

manipulations required for contrast and isosurface, the movement of the semi-landmarks to approximate the edge of condylar head cortication proved to be accurate within and between two different judges, and this study shows its reliability in three-dimensions.

### Skeletal vertical groups

While it was anticipated that the brachyfacial group would have a pronounced anterior lean of the condylar head, it was not anticipated that the lean would be so subtle between groups. All skeletal vertical groups exhibited a lean with only mild differences discernable between them.

More interesting is the differences seen between the skeletal vertical groups when viewing the Procrustes

averages from a superior view. The progressive change in morphology from one with an anterior concavity, as seen in the dolichofacial group, to one with an anterior convexity, as seen in the brachyfacial group, suggests that perhaps the anterior lean of the condylar head seen in traditional radiography of brachyfacial individuals is related to the lack of anterior growth at the lateral aspects of the condyle. It is also possible that the converse is true for dolichofacial individuals – the lack of an anterior lean could be reflective of deficient anterior growth of the center of the anterior surface of the condyle. In a recent study by Park *et al.*, it was found the hyperdivergent condyles were round from a superior view, whereas hypodivergent condyles were oval in shape.<sup>[14]</sup> The findings of their hypodivergent condyles are consistent with the findings of this study, but the findings of the hyperdivergent condyles are not consistent.

As for the differences seen between the group averages from the frontal view, the squatter appearance of the mesofacial group average when compared to the other two group averages can perhaps be explained by the high degree of variation that was seen in the mesofacial group. This group had outlier morphologies, which would affect the Procrustes average shape.

### Chin angle groups

The findings of the chin angle group averages were in many ways contrary to expectations. An acute chin angle, representing a forward leaning mandibular symphysis, is typically thought of as a brachyfacial characteristic. The Procrustes averages for this group, however, more closely resembled those of the dolichofacial Procrustes averages. In addition, an obtuse chin angle, representing a backward leaning mandibular symphysis, is typically thought of as a dolichofacial characteristic. The results are inconsistent with this, in that the Procrustes averages for this group most closely resembled those of the brachyfacial Procrustes averages.

### Limitations

The most significant limitation of this study is with the sample sizes of the six different groups. With larger sample sizes, Procrustes average shapes would likely be more distinct from one another and give the study more power.

The second limitation is the lack of a quantifiable difference between groups. All assessments are qualitative observations which lack objectivity. Future studies should employ numerical methods to compare morphologies such as principle component analysis.

## CONCLUSIONS

- Checkpoint has been shown to be reliable and predictable with good inter- and intra-rater correlation
- Discernable differences in morphology can be seen between dolichofacial, mesofacial, and brachyfacial condylar head averages
- When viewed from the lateral, only a subtle difference in the amount of anterior lean of the condylar head could be discerned
- When viewed from the superior, the anterior surface progresses from concave with dolichofacial individuals to convex with brachyfacial individuals
- The chin angle groups showed morphologies inconsistent with study expectations: Acute chin angle group averages most closely resembled dolichofacial

group averages, whereas obtuse chin angle group averages more closely resembled brachyfacial group averages

- Further research is needed with larger sample sizes and quantifiable differences between morphologies.

### Financial support and sponsorship

Nil.

### Conflicts of interest

There are no conflicts of interest.

## REFERENCES

1. Oberoi S, Nervina JM, Vargervik K. 3D imaging in diagnosis and treatment planning of craniofacial anomalies. In: Kapila SD, editor. Cone Beam Computed Tomography in Orthodontics: Indications, Insights, and Innovations. Ames, USA: John Wiley and Sons, Inc.; 2014.
2. Dalili Z, Khaki N, Kia SJ, Salamat F. Assessing joint space and condylar position in the people with normal function of temporomandibular joint with cone-beam computed tomography. *Dent Res J (Isfahan)* 2012;9:607-12.
3. Proffit WR. *Contemporary Orthodontics*. 5<sup>th</sup> ed. St. Louis: Mosby; 2013.
4. Barghan S, Merrill R, Tetradis S. Cone beam computed tomography imaging in the evaluation of the temporomandibular joint. *Tex Dent J* 2012;129:289-302.
5. Tsiklakis K, Syriopoulos K, Stamatakis HC. Radiographic examination of the temporomandibular joint using cone beam computed tomography. *Dentomaxillofac Radiol* 2004;33:196-201.
6. Hilgers ML, Scarfe WC, Scheetz JP, Farman AG. Accuracy of linear temporomandibular joint measurements with cone beam computed tomography and digital cephalometric radiography. *Am J Orthod Dentofacial Orthop* 2005;128:803-11.
7. Kau CH, Li JL, Li Q, Abou Kheir N. Update on cone beam technology and orthodontic analysis. *Dent Clin North Am* 2014;58:653-69.
8. Kikuchi K, Takeuchi S, Tanaka E, Shibaguchi T, Tanne K. Association between condylar position, joint morphology and craniofacial morphology in orthodontic patients without temporomandibular joint disorders. *J Oral Rehabil* 2003;30:1070-5.
9. Cevidanes LH, Bailey LJ, Tucker SF, Styner MA, Mol A, Phillips CL, *et al.* Three-dimensional cone-beam computed tomography for assessment of mandibular changes after orthognathic surgery. *Am J Orthod Dentofacial Orthop* 2007;131:44-50.
10. Schilling J, Gomes LC, Benavides E, Nguyen T, Paniagua B, Styner M, *et al.* Regional 3D superimposition to assess temporomandibular joint condylar morphology. *Dentomaxillofac Radiol* 2014;43:20130273.
11. Ikeda K, Kawamura A, Ikeda R. Prevalence of disc displacement of various severities among young preorthodontic population: A magnetic resonance imaging study. *J Prosthodont* 2014;23:397-401.
12. Ikeda R, Oberoi S, Wiley DF, Woodhouse C, Tallman M, Tun WW, *et al.* Novel 3-dimensional analysis to evaluate temporomandibular joint space and shape. *Am J Orthod Dentofacial Orthop* 2016;149:416-28.
13. Skjeller V, Björk A, Linde-Hansen T. Prediction of mandibular growth rotation evaluated from a longitudinal implant sample. *Am J Orthod* 1984;86:359-70.
14. Park IY, Kim JH, Park YH. Three-dimensional cone-beam computed tomography based comparison of condylar position and morphology according to the vertical skeletal pattern. *Korean J Orthod* 2015;45:66-73.