

Case Report

Correction of open bite with temporary anchorage device-supported intrusion

Joy Chang¹, Shivam Mehta², Po-Jung Chen², Madhur Upadhyay², Sumit Yadav²

¹Private Practice, CA, ²Department of Orthodontics, Division of Orthodontics, University of Connecticut Health Center, Farmington, CT, United States.



***Corresponding author:**


Sumit Yadav,
Department of Orthodontics,
University of Connecticut
Health Center, 263 Farmington
Avenue, MC1725, Farmington,
CT 06030, United States.

syadav@uchc.edu

Received : 29 July 19
Accepted : 29 August 19
Published : 31 December 19

DOI
10.25259/APOS_101_2019

Quick Response Code:



ABSTRACT

This case report describes the use of temporary anchorage device (TAD)-supported molar intrusion to correct anterior open bite and achieve overjet correction. A 13-year-old female presented with a Class II skeletal profile, with increased overjet and anterior open bite. She was treated with a combination of intrusion of the posterior teeth and extrusion of anterior teeth. The intrusion of maxillary posterior teeth was done with a palatal TAD and a transpalatal arch on the upper first molars to control the transverse dimension. The patient's mandibular plane angle was maintained with this treatment approach.

Keywords: Molar intrusion, Open bite, Temporary anchorage devices

INTRODUCTION

Management of anterior open bite could be addressed with surgical and non-surgical treatment approaches, with similar long-term stability of treatment outcomes.^[1] Surgical treatment involves combined orthodontic-orthognathic surgery and may involve one-jaw or two-jaw approaches. Non-surgical treatment includes use of occlusal adjustment, clear aligners, extrusion of anterior teeth, or intrusion of posterior teeth.^[2] Proper diagnosis and treatment planning are essential for selecting the best treatment method to achieve optimal facial esthetics along with restoring functional occlusion.

The treatment option selected for the patient depends on the esthetic and functional considerations. Treatment of anterior open bite by extrusion of the maxillary anterior teeth in a patient with good incisor show can lead to increased gingival display. Such cases can benefit from the intrusion of the posterior teeth to maintain the maxillary incisor position vertically. The challenge in treating anterior open bite is not only the correction of the open bite but also retention.^[3] Conventional treatment modalities used to correct anterior open bites include extractions, bite blocks, chin cup, multilooped wires, elastics, and magnets.^[3-8] There have been challenges with retention in such cases. The advent of temporary anchorage devices (TADs) has allowed for orthodontic movements previously thought to be very difficult or impossible.^[9] TAD-based intrusion of the posterior teeth in open bite cases has been found to be considerably stable.^[10] With the introduction of TADs, orthognathic surgery could be avoided for select anterior open bite cases.

This case report demonstrates a successful non-surgical orthodontic treatment with a combination of TAD-supported intrusion of posterior teeth and extrusion of anterior teeth in a patient with an anterior open bite.

This is an open-access article distributed under the terms of the Creative Commons Attribution-Non Commercial-Share Alike 4.0 License, which allows others to remix, tweak, and build upon the work non-commercially, as long as the author is credited and the new creations are licensed under the identical terms.

©2019 Published by Scientific Scholar on behalf of APOS Trends in Orthodontics

Diagnosis and treatment planning

A 13-year-old female patient reported to the orthodontic clinic at the University of Connecticut Health Center with a chief complaint of an anterior open bite and difficulty in incising food. She reported no contraindications to orthodontic treatment in her medical history and no history of TMJ disorder. No caries or pathologies were observed [Figure 1], and she had healthy periodontal tissues and good oral health.

Clinical examination [Figure 2] showed a convex soft tissue facial profile due to a retrognathic mandible. The patient had 100% incisor show on smile and 2 mm incisor show at rest. The maxillary dental midline was coincident with facial midline and mandibular midline was deviated 0.5 mm to

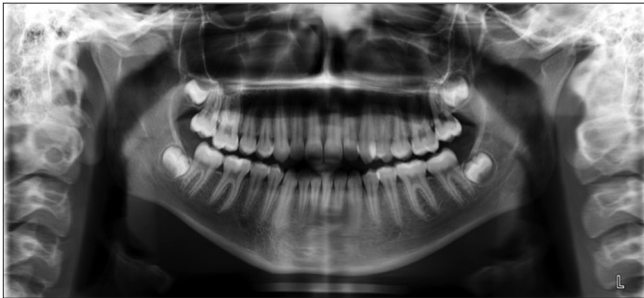


Figure 1: Pre-treatment panoramic radiograph.

the right of facial midline. Intraoral photographs and cast analysis show that the patient had Class I molar and end-on Class II canine relationship, with overjet of 6 mm. The patient had 2 mm anterior open bite, with two occlusal planes in the maxilla. The patient had mild maxillary and mandibular crowding. No posterior crossbites were present, and no functional shift or discrepancy between centric relation and centric occlusion was detected.

Lateral cephalometric analysis [Figure 3 and Table 1] showed a Class II skeletal pattern ($ANB = 5.8$) with a normal maxillary position ($SNA = 80.5$) and retrognathic mandibular position ($SNB = 74.7$). The patient had a normal upper incisor inclination ($U1-SN = 100$) and normal lower incisor inclination ($L1-MP = 90$). The patient presented with an anterior open bite with a hyperdivergent growth pattern ($FMA = 36$, $Y-axis = 64.5$), steep mandibular plane ($MP-SN = 45$), and decreased ramus height ($Ar-Go = 42.8$). The patient had a convex soft tissue profile, normal nasolabial angle (108.4), and protrusive upper lip and retrusive lower lip to E-plane ($UL-E-plane = 2.5$ mm, $LL-E-plane = 2.0$ mm) due to the retrognathic chin point.

The patient had good incisor show on smile and at rest. The patient needed improvement of facial convexity and overjet along with improvement or maintenance of the mandibular plane angle. Therefore, to achieve these treatment goals, the selected treatment plan for correction of the anterior open

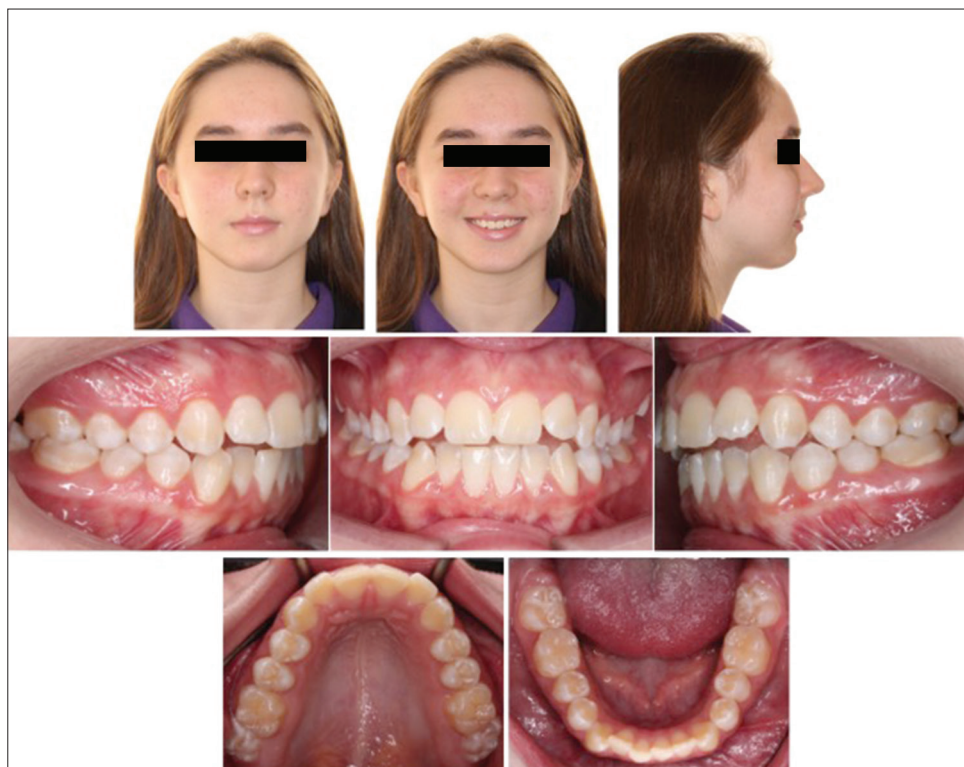

Figure 2: Pre-treatment facial and intraoral photographs.

bite was a combination of intrusion of the posterior teeth and extrusion of anterior teeth. The treatment was planned for segmental leveling and alignment of the upper arch, and continuous leveling and alignment of the mandibular arch. Intrusion of the posterior teeth was planned after alignment and leveling was complete, with the use of a transpalatal arch (TPA) to counter the transverse forces, to achieve the overjet correction, to improve the facial convexity, and to correct the anterior open bite with a combination of intrusion of posterior teeth and extrusion of anterior teeth.

Treatment progress

The patient was banded and bonded with pre-adjusted appliance, 0.022" MBT prescription. Segmental leveling and alignment of the maxillary arch (maxillary canine to the first molar was the posterior segments on the right and left side and maxillary right lateral incisor to maxillary left lateral incisor was the anterior segment) were achieved, along with continuous leveling and alignment of the mandibular arch. A TPA was placed to maintain the transverse width between the upper first molars during intrusion [Figure 4]. One palatal TAD (Lomas 2 × 7 mm) was placed in the mid-palate region at the level of the upper first molars, and elastic power chains were used to intrude the posterior teeth (upper premolars and molars). Once sufficient overbite was achieved, the TPA was removed and a continuous maxillary archwire was used. Progress panoramic radiograph was taken 12 months into treatment to evaluate and make adjustments to root positioning. Finishing bends were performed on a 0.017 × 0.025" beta-titanium archwires. Seating elastics were prescribed as needed during the finishing phase. On appliance removal, retention was achieved with a fixed upper 3-3 and lower 3-3 retainers, along with a maxillary Essix retainer.

Table 1: Cephalometric analysis.

Measurement	Norm	Pre-treatment	Post-treatment
SNA (°)	82.0±2.0	81	81
SNB (°)	80.0±2.0	75	76
ANB (°)	2.0±2.0	6	5
SN-MP (°)	32.0±5.0	46	45
FMA (°)	24.0±4.5	36	36
U1-SN (°)	102.0±5.5	100	104
U1-NA (mm)	4.3±2.7	4	4
L1-MP (°)	95.0±7	90	91
H-NB (mm)	4.0±1.8	6	7.5
Interincisal angle (°)	130.0±6.0	125	119
Upper lip to E-line (mm)	-6.0±2.0	-2.5	-3
Lower lip to E-line (mm)	-2.0±2.0	-2	-0.5

TREATMENT RESULTS

The final result showed that the patient had a satisfactory and pleasing esthetic outcome, with resolution of her chief complaint [Figure 5]. The patient has an improved soft tissue profile with improvement in chin projection along with maintenance of the mandibular plane angle and FMA during growth. The upper molar intrusion allowed for slight counterclockwise rotation of the mandible, thus advancing pogonion and advancing the lower incisor position to correct the overjet without changes to the mandibular plane angle [Figure 6]. The open bite was closed with 1.5 mm upper molar intrusion and 1.2 mm of upper incisor extrusion, which helped to achieve a good incisor show for the patient with 2 mm of gingival display on smile. The final result showed good alignment, with good seating and functional occlusion. The final panoramic X-ray [Figure 7] showed good root parallelism, without significant root shortening or development of other pathologies. The patient reports no development of signs or symptoms of TMJ disorder.

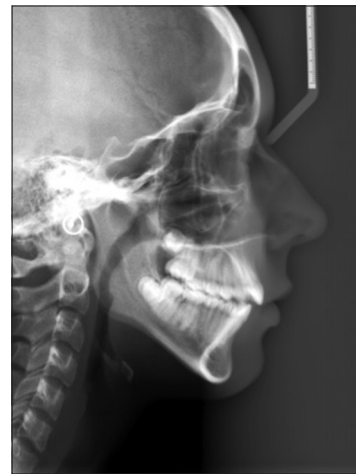

Figure 3: Pre-treatment lateral cephalometric radiograph.

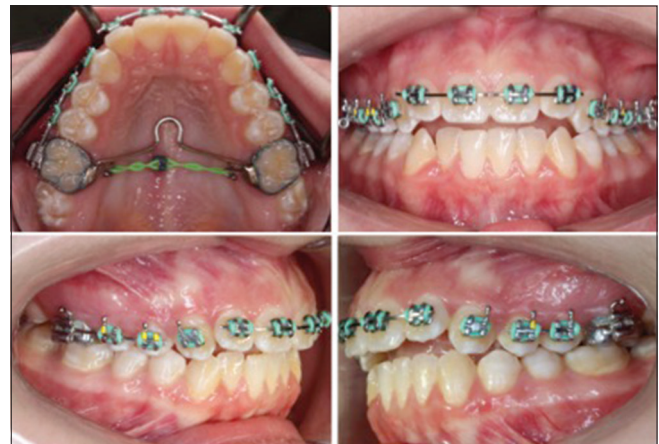


Figure 4: Progress intraoral photographs.

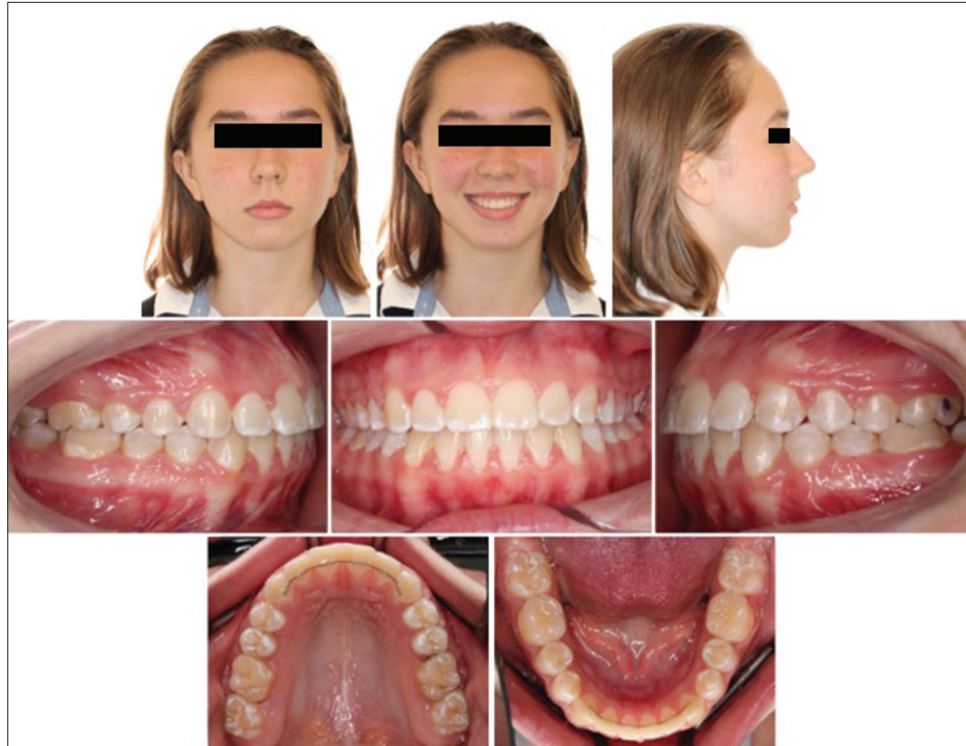

Figure 5: Post-treatment facial and intraoral photographs.

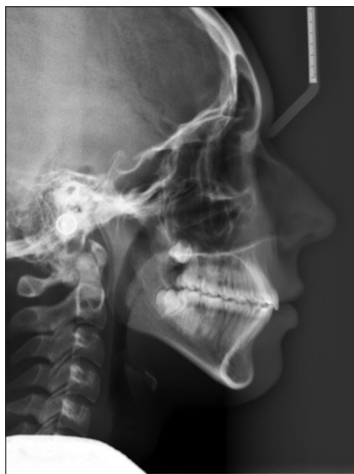

Figure 6: Post-treatment lateral cephalometric radiograph.

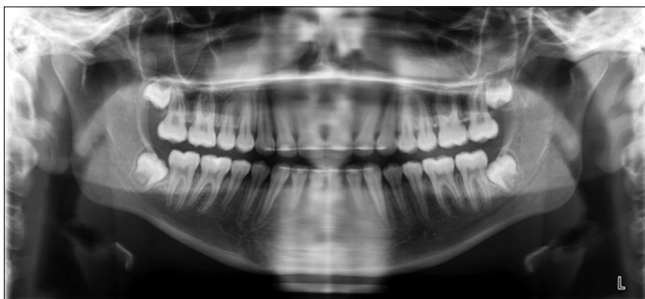


Figure 7: Post-treatment panoramic radiograph.

DISCUSSION

This case demonstrates a novel approach in addressing patients with an anterior open bite due to dental and skeletal components. Treatment of anterior open bite is often complex due to the multifactorial etiology for the open bite. The selection of an appropriate treatment plan is essential in open bite cases to achieve proper treatment goals for facial esthetics and functional occlusion in the vertical, transverse, and anterior-posterior dimensions.

Zawawi *et al.* have shown that 2 mm of gingival display on smile is considered to be an esthetic and attractive smile.^[11] Treatment of anterior open bite by extrusion of the maxillary anterior teeth in a patient with a good incisor show could lead to excessive gingival display. Such cases may benefit from intrusion of posterior teeth to correct anterior open bite without excessively increasing maxillary incisor display. Many open bite cases have an increased mandibular plane angle and decreased chin projection. In patients with a hyperdivergent pattern, posterior teeth intrusion could lead to counterclockwise rotation of the mandible and thus improve the chin projection.^[10] In this case, the patient had 100% maxillary incisor display on smile before treatment. The chosen treatment plan corrected the anterior open bite by a combination of TAD-based intrusion of posterior teeth and extrusion of anterior teeth, as well as to improve the facial convexity with autorotation of the mandible.

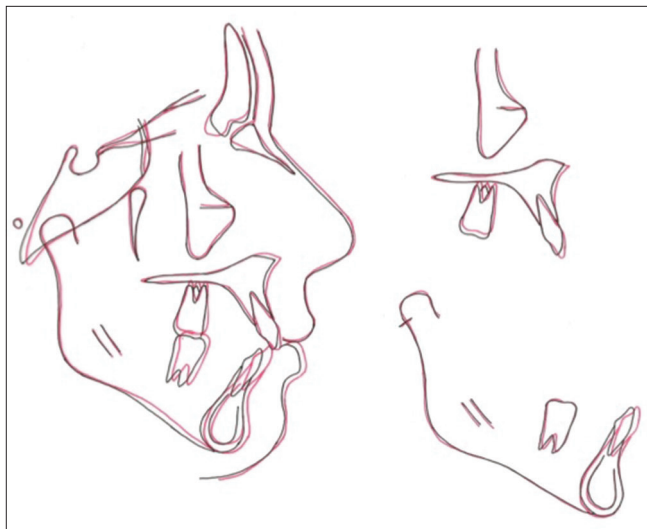


Figure 8: Superimpositions of pre-treatment (black line) and post-treatment (red line) cephalometric tracings.

The patient had a normal nasolabial angle and normal incisor angulation. We did not select an extraction treatment plan to avoid increasing the nasolabial angle and unfavorable changes to the facial profile. Surgical approaches, either single-jaw or bijaw orthognathic surgery combined with orthodontic treatment, can also be used for the correction of anterior open bite. However, the patient did not present with excessive facial imbalance requiring surgical intervention, and surgical and non-surgical treatment outcomes of open bite show similar stability.^[1] TAD-based intrusion of posterior teeth in open bite cases has been found to be considerably stable and has been shown to reduce the need for surgery in for select anterior open bite cases.^[10] Therefore, we selected a treatment plan to correct the anterior open bite non-surgically with TAD-based intrusion of the posterior teeth.

Conventionally, 2 mm of intrusion posteriorly was thought to cause 4 mm of anterior open bite closure. A more recent study found that 2.3 mm intrusion of the maxillary molar causes a change in overbite of 2.2 mm instead of the expected 4 mm, likely due to mandibular molar extrusion.^[12] In our case, the maxillary molar intrusion was 1.5 mm and the maxillary incisor extrusion was 1.2 mm, resulting in an overall change in overbite of 4 mm, from an the initial open bite of -2 mm to a final overbite of 2 mm. The combination of intrusion of the maxillary posterior teeth and extrusion of maxillary anterior teeth achieved correction of the anterior open bite and a consonant and pleasing smile arc [Figure 8]. We maintained the mandibular plane angle and hyperdivergent skeletal pattern in this growing patient but improved the facial profile and chin projection. We achieved a pleasing and esthetic outcome in this case by selecting a treatment plan that would address all of the planned treatment goals.

CONCLUSION

This case report shows a novel, efficient treatment approach using palatal TAD-supported molar intrusion with a TPA to counter adverse transverse side effects.

Declaration of patient consent

The authors certify that they have obtained all appropriate patient consent forms. In the form, the patient(s) has/have given his/her/their consent for his/her/their images and other clinical information to be reported in the journal. The patients understand that their names and initials will not be published and due efforts will be made to conceal their identity, but anonymity cannot be guaranteed.

Financial support and sponsorship

Nil.

Conflicts of interest

There are no conflicts of interest.

REFERENCES

- Greenlee GM, Huang GJ, Chen SS, Chen J, Koepsell T, Hujoel P, *et al.* Stability of treatment for anterior open-bite malocclusion: A meta-analysis. *Am J Orthod Dentofacial Orthop* 2011;139:154-69.
- Reichert I, Figel P, Winchester L. Orthodontic treatment of anterior open bite: A review article is surgery always necessary? *Oral Maxillofac Surg* 2014;18:271-7.
- Janson G, Valarelli FP, Henriques JF, de Freitas MR, Cançado RH. Stability of anterior open bite nonextraction treatment in the permanent dentition. *Am J Orthod Dentofacial Orthop* 2003;124:265-76.
- Kuster R, Ingervall B. The effect of treatment of skeletal open bite with two types of bite-blocks. *Eur J Orthod* 1992;14:489-99.
- Işcan HN, Dinçer M, Gültan A, Meral O, Taner-Sarisoy L. Effects of vertical chin cap therapy on the mandibular morphology in open-bite patients. *Am J Orthod Dentofacial Orthop* 2002;122:506-11.
- Kim YH, Han UK, Lim DD, Serraon ML. Stability of anterior openbite correction with multiloop edgewise archwire therapy: A cephalometric follow-up study. *Am J Orthod Dentofacial Orthop* 2000;118:43-54.
- Küçükkeleş N, Acar A, Demirkaya AA, Evrenol B, Enacar A. Cephalometric evaluation of open bite treatment with niTi arch wires and anterior elastics. *Am J Orthod Dentofacial Orthop* 1999;116:555-62.
- Kiliaridis S, Egermark I, Thilander B. Anterior open bite treatment with magnets. *Eur J Orthod* 1990;12:447-57.
- Costello BJ, Ruiz RL, Petrone J, Sohn J. Temporary skeletal anchorage devices for orthodontics. *Oral Maxillofac Surg Clin North Am* 2010;22:91-105.
- Deng JR, Li YA, Wang XD, Li J, Ding Y, Zhou YH, *et al.*

Evaluation of long-term stability of vertical control in hyperdivergent patients treated with temporary anchorage devices. *Curr Med Sci* 2018;38:914-9.

11. Zawawi KH, Malki GA, Al-Zahrani MS, Alkhiary YM. Effect of lip position and gingival display on smile and esthetics as perceived by college students with different educational backgrounds. *Clin Cosmet Investig Dent* 2013;5:77-80.
12. Scheffler NR, Proffit WR, Phillips C. Outcomes and stability

in patients with anterior open bite and long anterior face height treated with temporary anchorage devices and a maxillary intrusion splint. *Am J Orthod Dentofacial Orthop* 2014;146:594-602.

How to cite this article: Chang J, Mehta S, Chen P, Upadhyay M, Yadav S. Correction of open bite with temporary anchorage device-supported intrusion. *APOS Trends Orthod* 2019;9(4):246-51.