

Oops! There goes my miniscrew!

Any orthodontist with reasonable years in practice will come across situations where patients ingest orthodontic appliances/components, or parts of an appliance incidentally. This can, at times, constitute a serious emergency. The odds of something being inhaled versus swallowed, after passing the tongue is 1:12.

Bilder *et al.*^[1] noted that “Objects that are ingested enter and traverse the alimentary canal and... The majority of them pass through the body without incident... Aspiration is more serious as... obstruction of the larynx or the trachea causes obstruction of the bronchial tree, which may result in pulmonary atelectasis, emphysema, or even death. An impacted foreign body in the gastrointestinal tract may lead to long-term complications such as esophageal erosion or perforation of the gut.”

Usually, we are spared the risk of aspiration because of the gag reflex, however, that can fail, and 3700 people die per year – equating to 1.2 deaths per 100,000 – due to ingestion or inhalation of foreign objects or food. The objects most commonly reported are coins, meat, buttons, and batteries. Whereas most objects pass without an incident, 10%–20% require endoscopic removal and 1% require surgical intervention. The position of the patient during treatment, sitting versus supine, is irrelevant; the literature is mixed on this issue. It goes without question that aspiration, but not so much ingestion, carries a higher risk potential for malpractice litigation.^[2]

An orthodontist should be aware of these and be able to manage such a situation until specialty care arrives. We experienced an in office incident with an 11-year-old male patient who accidentally swallowed an orthodontic miniscrew. Subsequently, it did pass through the gastrointestinal tract without serious repercussions. The possible precautions that need to be taken which could prevent such accidents, and the management protocols to be followed during such emergencies are discussed in this editorial.

Miniscrews today are an indispensable armamentarium in modern-day orthodontic practices. Although an asset to the armamentarium, clinicians have experienced instances of screw loosening.^[3] The fact that miniscrews could loosen and drop into the oral cavity raises the possibility and concern of accidental ingestion or aspiration of



these adjuncts although they have been rarely reported in orthodontic literature. In an animal study, it was concluded that spontaneous ejection usually occurs for orthodontic anchorage screws that are ingested, and patients who swallow these screws should be carefully observed before resorting to early surgical removal.^[4]

OUR TRYST

An 11-year-old male patient was being treated for malaligned upper incisors. After careful assessment, distalization was planned, and the mechanics for the same included the use of two palatal miniscrews. Two miniscrews (2 mm diameter and 8 mm length – 3M Unitek; United States) were placed in the anterior region of the palate [Figure 1a-c]. After the fabrication of an appliance for distalization, the patient was recalled for the next appointment in a week. It was observed that one of the miniscrews had loosened at its position and needed repositioning. The patient was in a supine position, and with the help of the mini-implant driver, the miniscrew was to be removed from the palate. While it was being removed, the patient turned his head to the left, which gave a push to the mini-implant driver, and accidentally, the mini implant fell into the oral cavity. The patient noticing that something had fallen immediately moved his tongue to locate it. Before the operator could pick up the

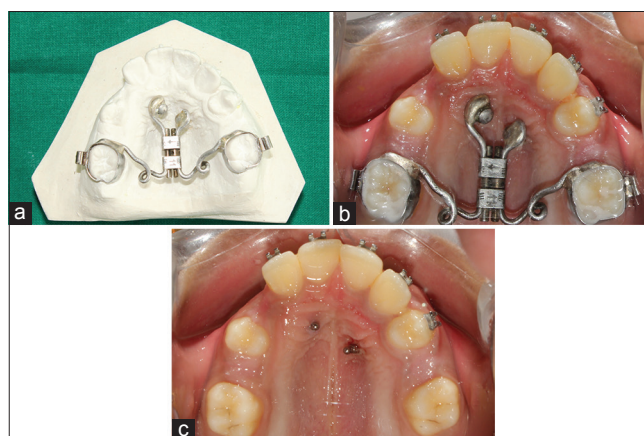


Figure 1: (a-c) Palatal miniscrew supported distalization assembly

mini implant from the oral cavity, the patient swallowed the mini implant.

The patient was immediately made to lie on one side and cough forcefully, but it did not help. The oral cavity was carefully inspected, and the absence of the mini implant confirmed the suspicion of the patient swallowing it. The patient was immediately sent to the Department of Radiology (under supervision) of the Institution's general hospital and posteroanterior radiograph of the chest was made [Figure 2]. The radiograph did not show the presence of any foreign body material. Further, the anteroposterior abdominal radiograph [Figure 3] was made. This radiograph showed the presence of the miniscrew in the abdominal cavity. The laparoscopic surgeon was consulted for the same. He advised us to wait for 2–3 days, in which time he expected the spontaneous ejection of the mini implant. The patient's parents were comforted and assured of providing all the necessary intervention if required after a waiting period of about 2–3 days. Three days after ingestion, another anteroposterior abdominal radiograph [Figure 4] was made which was clear of the foreign body material suggesting that the miniscrew had been expelled.

A PROTOCOL FOR MANAGEMENT OF ACCIDENTAL INGESTIONS

Orthodontic appliances or parts of them can compromise the airway and gastrointestinal tract because of their close proximity to the oropharynx. Any foreign body in the airway needs to be treated as a serious situation since it can be a cause of accidental death.^[5]

The incidence of aspiration or swallowing of dental foreign bodies ranged from 3.6% to 27.7% of all foreign bodies ingested, with the number considerably higher in children compared to adults.^[6] Reported cases of ingestion of orthodontic appliances include swallowing of an expansion appliance key,^[7-9] a mandibular spring retainer,^[10] a fragment of maxillary removable appliance,^[11] a piece of archwire,^[12] a transpalatal arch,^[13] and a fractured twin block appliance.^[14] Most of these were managed conservatively.

Although our case did not showcase further complications, it did create anxiety in our minds until the second radiograph was made. We present certain prevention and management protocols for such situations.

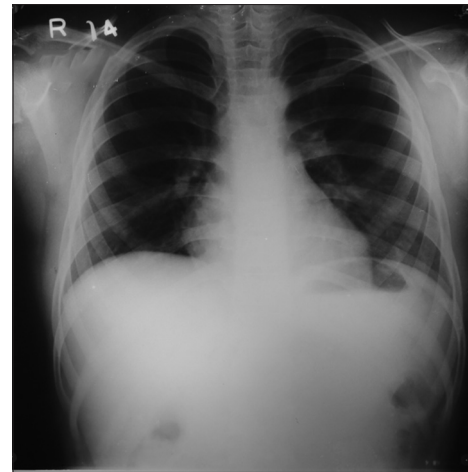


Figure 2: Posteroanterior chest radiograph showing clear field indicating absence of foreign body material

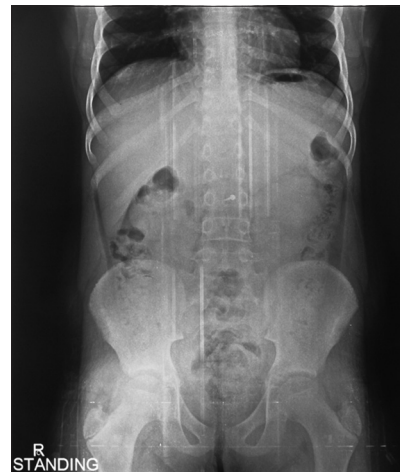

Figure 3: Anteroposterior abdominal radiograph showing the presence of the anchorage screw in the abdominal cavity

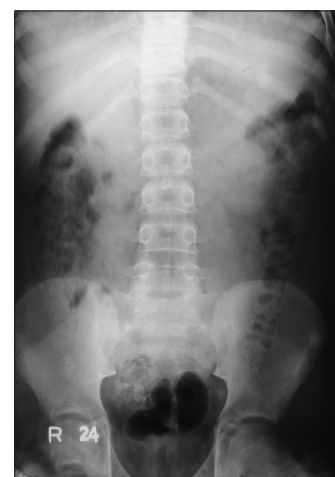

Figure 4: Anteroposterior abdominal radiograph showing no evidence of the anchorage screw in the abdominal cavity

PREVENTION AND MANAGEMENT PROTOCOLS TO BE FOLLOWED IN CASES OF MINISCREW INGESTION/ASPIRATION

Prevention protocols

- Always place or hold a gauze pack distal to the area where the implant is being placed or removed so that it can entrap the anchorage screw if it falls into the oral cavity. Especially for palatal miniscrew placement, removal, or activations, this should be non-negotiable.
- Availability of high-speed suction along with a pharyngeal tip helps in quick retrieval^[15]
- Good illumination in the office so that the operator can locate the site of the fallen implant with ease
- A sterile long handle tweezers should be a part of the orthodontic emergency kit by the chair side, for quick removal of ingested materials
- The anchorage screws could be adequately harbored by steel ligatures to the main appliance^[16]
- Ensure that the implant is properly secured in the driver while it is removed or placed
- If any instrument is used along with the implant driver to aid in the removal of the loose microimplant, it should have a precise grip on the implant and should not, on the contrary, complicate the removal
- Before the removal of an implant from areas such as palate, it should be tied with an adequate length of floss (through the eyelet) as a precautionary measure.

Management protocols

- If the anchorage screw loosens with the head in supine position, turn the patient on one side to encourage it falling on the cheek rather than it dropping into the oropharynx^[17]
- Under good illumination, inspect the oral cavity and oropharynx for the dislodged screw and try retrieving it as soon as it is seen with the help of forceps or high-power suction^[16]
- If there is a suspicion of aspiration, the patient should be encouraged to cough, be given back blows and abdominal thrusts (Heimlich maneuver).^[15-20] If the patient shows signs of breathlessness, then try to maintain a positive airway pressure with the help of artificial respiration and if this fails to maintain a patent airway, the object should be bypassed and an emergency airway established^[21] by the emergency care medical team
- If the patient does not show any acute symptoms, the patient is immediately referred for posteroanterior chest X-ray.

If the posteroanterior chest radiograph confirms the anchorage screw:

- Forward viewing flexible panendoscopy can be performed under local anesthesia and is best suited for intrathoracic objects^[16]
- Foley's catheter can also be used which involves passing a balloon distal to the ingested object usually under fluoroscopic guidance, inflating the balloon and then withdrawing the catheter along with the object proximally^[18]
- If the preceding modalities fail to remove the anchorage screw, surgical intervention is the last resort and is relatively successful.^[16]

If the posteroanterior chest radiograph does not confirm the presence of the foreign body:

- Anteroposterior abdominal radiograph is made. This may show the presence of the foreign body either in the esophagus (impaction usually occurs at the level of fourth cervical vertebrae)^[10] or into the abdominal cavity
- Although approximately 60% of ingested foreign objects pass through the esophagus and enter the stomach,^[22] if the object is lodged in the esophagus, it is unlikely to pass spontaneously and has to be removed with the help of endoscopy
- If the object has passed through the esophagus into the stomach, approximately 80%–90% of objects pass through the gut uneventfully.^[10,23,24] Thus, a wait and watch policy can be adopted. Furthermore, serial abdominal anteroposterior radiographs should be made which are of great value in tracking the passage of the foreign object.^[11] The time taken for a foreign body to traverse the intestinal tract can vary between 2 and 12 days^[10]
- The patients should be advised to supplement their diet with a large amount of cellulose, laxative, and foods such as bananas which aid the passage of the object through the gut^[9]
- Less than 1% of the foreign bodies in the gastrointestinal tract have caused a perforation.^[13,25] The ileocecal junction and the sigmoid colon are the most common sites for perforation of the gastrointestinal tract.^[16] In the rare case of impaction of the foreign body into the stomach, it has to be removed surgically. It is important, however, to note here that these statistics should be evaluated with caution as miniscrews, because of their shape, have a higher potential of perforating the gastrointestinal tract, compared to other orthodontic appliance components.

Every appliance and advancement in mechanotherapy comes with a caveat that the clinician is advised to take cognizance of. Nothing in orthodontics gives us an “absolute” wand to wave. Basic emergency care knowledge

and prevention protocols need to be reviewed and updated by a clinician from time to time.

Vaid Nikhilesh, Shah Pratik¹, Vandekar Meghna²

Editor in Chief,

APOS Trends in Orthodontics,

¹Department of Orthodontics and Dentofacial Orthopedics, YMT Dental College and Hospital, ²Chair and Prof, Department of Orthodontics, YMT Dental College and Hospital, Mumbai, Maharashtra, India

Address for Correspondence: Prof. Nikhilesh R. Vaid,
Ground Floor, New Blue Gardenia Housing Society,
Peddar Road, Mumbai, Maharashtra, India.
E-mail: orthonik@gmail.com

REFERENCES

- Bilder L, Hazan-Molina H, Aizenbud D. Medical emergencies in a dental office: Inhalation and ingestion of orthodontic objects. *J Am Dent Assoc* 2011;142:45-52.
- Jerrold L. Litigation and legislation. The patient has a big mouth. *Am J Orthod Dentofacial Orthop* 2013;143 4 Suppl: S173-5.
- Costa A, Raffaini M, Melsen B. Miniscrews as orthodontic anchorage: A preliminary report. *Int J Adult Orthodon Orthognath Surg* 1998;13:201-9.
- Choi BH, Li J, Kim HS, Ko CY, Jeong SM, Xuan F, *et al.* Ingestion of orthodontic anchorage screws: An experimental study in dogs. *Am J Orthod Dentofacial Orthop* 2007;131:767-8.
- Aytaç A, Yurdakul Y, Ikizler C, Olga R, Saylam A. Inhalation of foreign bodies in children. Report of 500 cases. *J Thorac Cardiovasc Surg* 1977;74:145-51.
- Tamura N, Nakajima T, Matsumoto S, Ohyama T, Ohashi Y. Foreign bodies of dental origin in the air and food passages. *Int J Oral Maxillofac Surg* 1986;15:739-51.
- Nazif MM, Ready MA. Accidental swallowing of orthodontic expansion appliance keys: Report of two cases. *ASDC J Dent Child* 1983;50:126-7.
- Monini Ada C, Maia LG, Jacob HB, Gandini LG Jr. Accidental swallowing of orthodontic expansion appliance key. *Am J Orthod Dentofacial Orthop* 2011;140:266-8.
- Tripathi T, Rai P, Singh H. Foreign body ingestion of orthodontic origin. *Am J Orthod Dentofacial Orthop* 2011;139:279-83.
- Hinkle FG. Ingested retainer: A case report. *Am J Orthod Dentofacial Orthop* 1987;92:46-9.
- Parkhouse RC. Medical complications in orthodontics. *Br J Orthod* 1991;18:51-7.
- Lee BW. Case report – Swallowed piece of archwire. *Aust Orthod J* 1992;12:169-70.
- Absi EG, Buckley JG. The location and tracking of swallowed dental appliances: The role of radiology. *Dentomaxillofac Radiol* 1995;24:139-42.
- Rohida NS, Bhad WA. Accidental ingestion of a fractured Twin-block appliance. *Am J Orthod Dentofacial Orthop* 2011;139:123-5.
- Israel HA, Leban SG. Aspiration of an endodontic instrument. *J Endod* 1984;10:452-4.
- Umesan UK, Chua KL, Balakrishnan P. Prevention and management of accidental foreign body ingestion and aspiration in orthodontic practice. *Ther Clin Risk Manag* 2012;8:245-52.
- Cameron SM, Whitlock WL, Tabor MS. Foreign body aspiration in dentistry: A review. *J Am Dent Assoc* 1996;127:1224-9.
- Lanning GE. Accidental aspiration of a cast crown during attempted delivery. *J Indiana Dent Assoc* 1988;67:22-3.
- Jacobi R, Shillingburg HT Jr. A method to prevent swallowing or aspiration of cast restorations. *J Prosthet Dent* 1981;46:642-5.
- Heimlich HJ. A life-saving maneuver to prevent food-choking. *JAMA* 1975;234:398-401.
- Edmondson HD, Frame JW, Malins AF. Medical emergencies in dental practice: An update on drugs and the management of acute airway obstruction. *Dent Update* 1989;16:254-6.
- Hacker JF 3rd, Cattau EL Jr. Management of gastrointestinal foreign bodies. *Am Fam Physician* 1986;34:101-8.
- Webb WA, McDaniel L, Jones L. Foreign bodies of the upper gastrointestinal tract: Current management. *South Med J* 1984;77:1083-6.
- Ghori A, Dorricott NJ, Sanders DS. A lethal ectopic denture: An unusual case of sigmoid perforation due to unnoticed swallowed dental plate. *J R Coll Surg Edinb* 1999;44:203-4.
- Gonzalez JG, Gonzalez RR, Patiño JV, Garcia AT, Alvarez CP, Pedrosa CS. CT findings in gastrointestinal perforation by ingested fish bones. *J Comput Assist Tomogr* 1988;12:88-90.

This is an open access article distributed under the terms of the Creative Commons Attribution-NonCommercial-ShareAlike 3.0 License, which allows others to remix, tweak, and build upon the work non-commercially, as long as the author is credited and the new creations are licensed under the identical terms.

Access this article online	
Quick Response Code:	Website: www.apospublishations.com
	DOI: 10.4103/2321-1407.194797

How to cite this article: Nikhilesh V, Pratik S, Meghna V. Oops! There goes my miniscrew!. *APOS Trends Orthod* 2016;6:277-80.