

## Original Article

# A simplified method for measurement of palatal bone thickness to select the optimum length of orthodontic mini-implant

Vivek J. Patni<sup>1</sup>, Swapnagandha R. Kate<sup>2</sup>, Sheetal S. Potnis<sup>3</sup>, Neeraj E. Kolge<sup>2</sup>

Departments of Orthodontics and Dentofacial Orthopedics, <sup>1</sup>MGM Dental College and Hospital, <sup>2</sup>MGM Dental College, Navi Mumbai, <sup>3</sup>Sinhagad Dental College and Hospital, Pune, Maharashtra, India.



### \*Corresponding author:

Dr. Swapnagandha R. Kate,  
Department of Orthodontics and  
Dentofacial Orthopedics, MGM  
Dental College and Hospital,  
Navi Mumbai, Maharashtra,  
India.

swapnagandha.kate@gmail.com

Received : 04 April 18


Accepted : 11 October 18

Published : 31 March 19

### DOI

10.25259/APOS\_34\_2019

### Quick Response Code:



## ABSTRACT

**Introduction:** The palatal bone is a suitable site for mini-implant placement due to it being a “rootless area” with dense bone. This application has increased with mini-implant-assisted rapid palatal expansion becoming the preferred method of expansion. It is necessary to measure the vertical bone height with a reasonable accuracy, at the implant insertion site, to utilize the maximum available bone support, and to avoid the risk of perforations. As an accepted method, full-volume cone-beam computed tomography (CBCT) scan is advised for the same. This requires an additional procedure, further, radiation exposure, and cost to the patient. The aim of the study was to establish the utility of lateral cephalogram as a simple and reliable method to measure palatal bone thickness for placement of mini-implants in the 1<sup>st</sup> premolar and 1<sup>st</sup> molar region, which are the most common sites of mini-implant placement.

**Materials and Methods:** A total of 30 CBCT scans and digital lateral cephalograms of patients were selected and analyzed at the 1<sup>st</sup> premolar and molar region and were statistically evaluated using Student’s t-test and Wilcoxon rank-sum test.

**Results:** The results obtained indicated a highly significant correlation between the measurements obtained on lateral cephalograms at both the 1<sup>st</sup> premolar and 1<sup>st</sup> molar areas,  $P < 0.001$ .

**Conclusion:** The data presented show that lateral cephalometry provides a reliable assessment of the quantity of vertical bone for paramedian insertion of a palatal implant.

**Keywords:** Cone-beam computed tomography, Digital cephalogram, Mini-implant-assisted rapid palatal expansion, Palatal bone, Palatal mini-implants.

## INTRODUCTION

The use of mini-implants has become widespread in orthodontic practice. Their application has augmented the viability and versatility of using skeletal anchorage in many innovative ways. This is primarily because they lend themselves to immediate use, without waiting for osseointegration and provide reasonable stability on loading with orthodontic forces.

The interradicular spaces, though most common as mini-implant insertion sites, are limited by the proximity of periodontium of the neighboring roots, with a risk of damage to the roots and eventual implant failure. These risk factors can be avoided by the use of “rootless areas” such as the hard palate. In all probability, the palatal bone is the most suitable site for mini-implant placement due to its histomorphology and the simplicity of placing mini-implants in this area.<sup>[1-8]</sup> Furthermore, the thickness of the soft tissue of the median palate between the first and second premolars is, on average, 3.06–0.45 mm.<sup>[2]</sup> The median and paramedian areas of the palate consist of cortical bone, which is thick and dense enough to support a

This is an open-access article distributed under the terms of the Creative Commons Attribution-Non Commercial-Share Alike 4.0 License, which allows others to remix, tweak, and build upon the work non-commercially, as long as the author is credited and the new creations are licensed under the identical terms.

©2019 Published by Scientific Scholar on behalf of APOS Trends in Orthodontics

mini-implant that can sustain orthodontic forces. This region has the obvious advantage of no anatomical structures such as nerves, blood vessels, or roots that can hinder the placement of mini-implants.<sup>[9,10]</sup> This thickness, with the inherent characteristics of the palatal mucosa, warrants biomechanical stability for placement of mini-implants.<sup>[11-20]</sup>

Methods have been proposed to use palatal mini-implants for retraction of the anteriors and for molar distalization without loss of anchorage.<sup>[21-23]</sup> The palatal implants have been successfully used as an anchorage device for intrusion of few or all the maxillary teeth. It is also used as an indirect anchorage device to stabilize transpalatal arch. There are various other innovative applications of palatal mini-implants like implant-supported habit breaking appliance. The current interests in mini-implant-assisted rapid palatal expansion have necessitated the methods to determine the thickness of the palatal bone so as to enable the use of the longest possible size of the implant to provide skeletal anchorage. The thickness of the palate bone is crucial to the stability of the implant. Palatal bone thicknesses differ in patients with different facial patterns. Sufficient bone depth would provide good mechanical retention and stability to the implant.<sup>[24]</sup> In case of monocortical insertion, it is important to know the width of the available bone to avoid perforation of the nasal floor or the maxillary sinus. In some applications, the suggested method of mini-implant insertion is bicortical engagement. In this type of insertion, the implant size has to be selected so as the tip of the inserted implant is perforating the bony floor of the nose and not the mucosal membrane.

It is necessary to measure the vertical bone height with reasonable accuracy, at the planned implant insertion site to utilize the maximum available bone thickness as well as to avoid the incidence of overextension of the mini-implant. Several studies have assessed palatal bone volume for the placement of mini-implants at various sites, as part of orthodontic treatment in children, adolescents, and young adults using cone-beam computed tomography (CBCT).<sup>[25-27]</sup> Studies have demonstrated that CBCT can provide accurate three-dimensional (3-D) images of oral structures and can reflect the structure of palatal bones and variation in thickness at a particular level. Evaluation of palatal bone depth with CBCT is easy and accurate;<sup>[3,27]</sup> however, this involves additional cost, radiation exposure, time, and expertise associated with the CBCT scan.

Lateral cephalograms form an essential diagnostic aid to diagnose and plan the orthodontic treatment. These radiographs are routinely taken for almost every patient requiring orthodontic intervention. A good quality digital lateral cephalogram will show the palatal bone with a sound clarity. Since the palatal bone is seen as a midline structure, with minimal distortion and superimpositions, it is possible that the thickness of the palate as measured on a lateral cephalogram will closely approximate the bone width measurements taken at the median and paramedian sites on a CBCT.

In conjunction with STROBE's guidelines for observational studies, the present study was performed to evaluate and compare

the palatal bone thickness measurement as taken on CBCT at median and 3 mm paramedian (to evaluate possible morphological variation) and lateral cephalogram in the 1<sup>st</sup> premolar and 1<sup>st</sup> molar region, which are the most common sites of mini-implant placement. The readings were recorded and analyzed to verify the extent of correlation on both lateral cephalogram and CBCT scans. The study was done with an aim to evaluate the feasibility of using lateral cephalograms with a certain degree of confidence as an investigation method for determining the palatal bone thickness for mini-implant insertion.

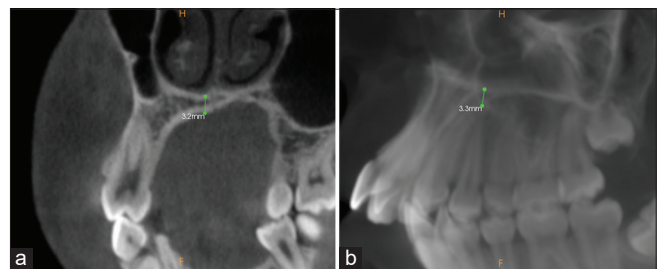
## MATERIALS AND METHODS

All the CBCT scans and digital lateral cephalograms of patients were obtained from a CBCT scan center. The inclusion criteria were patients with malocclusion who were between 18 and 40 years old. Subjects were excluded if they had missing teeth, cleft palate, impacted teeth, or any systemic illnesses. After all the inclusive and exclusive criteria were applied, 30 adults (11 men and 19 women) aged 18–35 years (mean age, 26.8 years) were selected.

The line passing through the midpoint of the posterior border of the foramen incisivum and the posterior nasal spine was defined as the midline. Along the midline, the midsagittal plane was created by multiplanar reconstruction. The image was aligned along the long axis of the maxillary 1<sup>st</sup> premolar [Figures 1a, b and 2] and 1<sup>st</sup> molar [Figures 2 and 3a, b] in all three planes and all the measurements were done along this plane. Measurements were taken in the sagittal and coronal section on the CBCT scans and similarly on the lateral cephalogram [Figure 2] in the sagittal view. Readings were taken twice by two operators. The operators were double blinded to avoid bias. As previous studies have reported, no significant differences were found between the left and right sides of the palate; hence, only data obtained from the right side were analyzed further.

## RESULTS

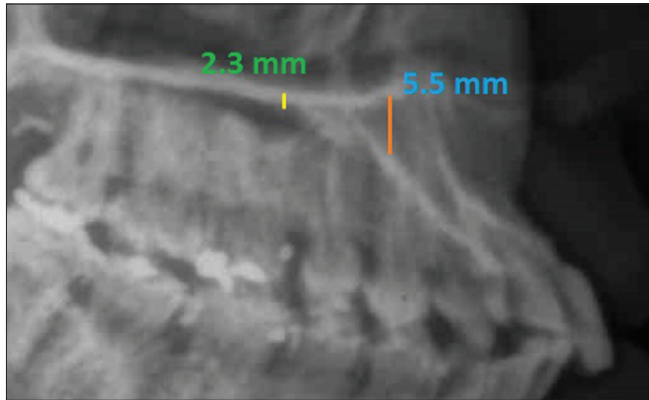
Data were collected and statistically analyzed using the SPSS software. The results obtained indicated a highly significant correlation between the measurements taken on CBCT and



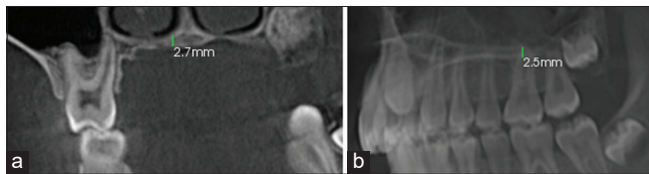
**Figure 1:** (a) Measurements done on cone-beam computed tomography at the 1<sup>st</sup> premolar site coronal view. (b) Measurements done on cone-beam computed tomography at the 1<sup>st</sup> premolar site sagittal view.

**Table 1:** Descriptive statistics ( $n=30$  observations).

Site of measurement	Mean±SD (mm)	25 <sup>th</sup> percentile (mm)	Median (50 <sup>th</sup> percentile) (mm)	75 <sup>th</sup> percentile (mm)
1 <sup>st</sup> premolar				
CBCT coronal	3.14±1.08	2.4	2.95	3.8
CBCT sagittal	3.15±1.08	2.4	3.0	3.8
Lat ceph sagittal	3.14±1.09	2.4	2.95	3.8
1 <sup>st</sup> molar				
CBCT coronal	2.26±0.35	2.0	2.3	2.5
CBCT sagittal	2.23±0.33	2.1	2.3	2.4
Lat ceph sagittal	2.24±0.34	2.1	2.3	2.4



**Figure 2:** Measurements done on lateral cephalogram at the 1<sup>st</sup> premolar and 1<sup>st</sup> molar site.



**Figure 3:** (a) Measurements done on cone-beam computed tomography at the 1<sup>st</sup> molar site coronal view. (b) Measurements done on cone-beam computed tomography at the 1<sup>st</sup> molar site sagittal view.

lateral cephalograms at both the 1<sup>st</sup> premolar and 1<sup>st</sup> molar areas [Tables 1 and 2]. The variations in the reading taken on lateral cephalogram and CBCT had a distribution of the measurement error of 0 mm (for premolar) and 0.01 mm (for molar) values [Tables 3 and 4]. A highly significant correlation (correlation coefficient = 82.3%) was found on the measurements taken on the common median and paramedian sites for mini-implant insertion. Thus, the values measured along the midpalatal line can be relied on to estimate the bone thickness 3–4 mm lateral to it. There was no statistically significant difference found between the means of measured bone thickness at the 1<sup>st</sup> premolar and 1<sup>st</sup> molar as seen on the lateral cephalogram and the CBCT (coronal view and sagittal view) [Table 5]. Student’s t-test was used to compare the means of the 1<sup>st</sup> premolar and 1<sup>st</sup> molar measurements. Wilcoxon rank-sum test was used to compare the means of the 1<sup>st</sup> premolar and 1<sup>st</sup> molar measurements due to non-normal distribution of data. The graphical expression of the statistical finding done by

**Table 2:** Correlation of measurements.

1 <sup>st</sup> premolar	Correlation coefficient	P
Lateral cephalogram sagittal		
CBCT coronal	0.9993	<0.001
CBCT sagittal	0.9971	<0.001
1 <sup>st</sup> molar	Correlation coefficient	P
Lateral cephalogram sagittal		
CBCT coronal	0.9857	<0.001
CBCT sagittal	0.9648	<0.001

taking CBCT measurements as the standard and comparing with the measurements taken on lateral cephalogram shows very close approximation in both premolar and molar readings [Graphs 1-4]. This confirms that readings taken on lateral cephalogram are as reliable as the ones taken on CBCT.

## DISCUSSION

Accurate determination of available bone thickness is important for choosing the optimum length of the mini-implant for a particular insertion site. In case of sufficient thickness of bone, the longest possible mini-implant will have distinct mechanical advantages for stability under load.

Although “surgical” complications during the insertion of palatal implants are extremely uncommon and largely theoretical in nature, it is vital to preoperatively identify patients who may be subjected to a higher risk of complications such as those with lack of sufficient bone for supporting the mini-implant under loading or perforation of the nasal floor. With a clear knowledge of osseous anatomy in a given situation, the implant insertion sites, the appliance designs, and mechanics can be planned even more efficiently.

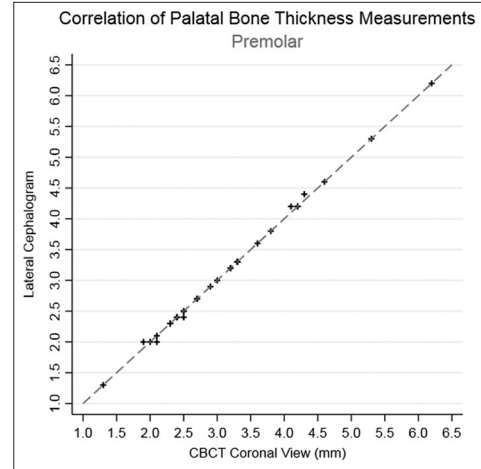
To date, lateral radiographs represent the basic radiological investigation for orthodontic treatment planning and are the gold standard of imaging in patients undergoing orthodontic treatment. Therefore, the aim of this investigation was to evaluate whether lateral cephalometry alone allows an adequate and reliable diagnostic assessment for pre-operative planning of paramedian palatal implants or whether one of the modern 3-D imaging procedures (CT/CBCT) is additionally required before

**Table 3:** Distribution of measurement error with lateral cephalogram: Premolar.

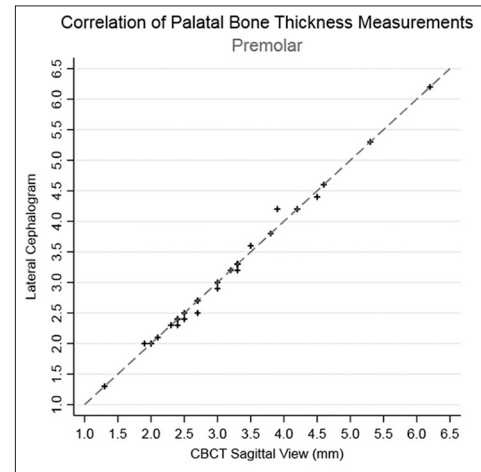
Compared to	Mean error (mm)	1 <sup>st</sup> percentile (mm)	5 <sup>th</sup> percentile (mm)	10 <sup>th</sup> percentile (mm)	25 <sup>th</sup> percentile (mm)	50 <sup>th</sup> percentile (mm)	75 <sup>th</sup> percentile (mm)	90 <sup>th</sup> percentile (mm)	95 <sup>th</sup> percentile (mm)	99 <sup>th</sup> percentile (mm)
CBCT coronal	0	-0.1	-0.1	0	0	0	0	+0.05	+0.1	+0.1
CBCT sagittal	-0.1	-0.2	-0.1	-0.1	0	0	0	+0.5	+0.1	+0.3

**Table 4:** Distribution of measurement error with lateral cephalogram: Premolar.

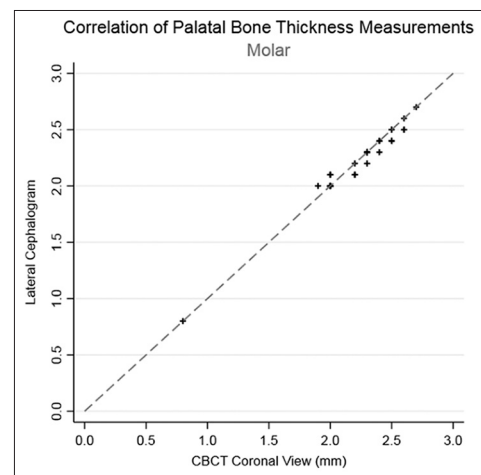
Compared to	Mean error (mm)	1 <sup>st</sup> percentile (mm)	5 <sup>th</sup> percentile (mm)	10 <sup>th</sup> percentile (mm)	25 <sup>th</sup> percentile (mm)	50 <sup>th</sup> percentile (mm)	75 <sup>th</sup> percentile (mm)	90 <sup>th</sup> percentile (mm)	95 <sup>th</sup> percentile (mm)	99 <sup>th</sup> percentile (mm)
CBCT coronal	-0.02	-0.1	-0.1	-0.1	-0.1	0	0	+0.05	+0.1	+0.1
CBCT sagittal	+0.1	-0.1	-0.1	-0.1	0	0	+0.1	+0.1	+0.1	+0.2



**Graph 1:** Graphical representation of variation in premolar measurements (Coronal view).



**Graph 2:** Graphical representation of variation in premolar measurements (Sagittal view).

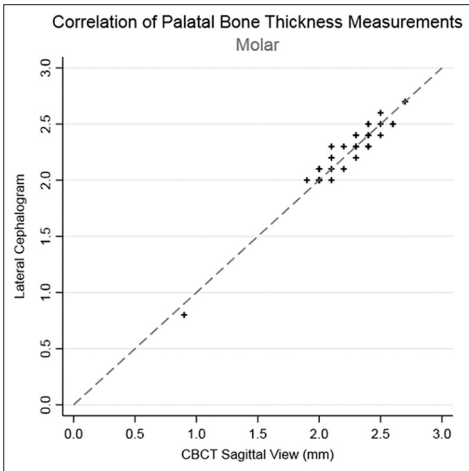


**Graph 3:** Graphical representation of variation in molar measurements (Coronal view).



**Table 5:** Comparison of means.

Site of measurement	Mean (mm)	Standard error	P (comparison of A with B)	P (comparison of A with C)
<b>1<sup>st</sup> Premolar<sup>a</sup></b>				
Lat ceph sagittal (A)	3.14	0.199	-	-
CBCT coronal (B)	3.14	0.198	0.9906	-
CBCT sagittal (C)	3.15	0.197	-	0.9811
<b>1<sup>st</sup> Molar<sup>b</sup></b>				
Lat ceph sagittal (A)	2.24	0.061	-	-
CBCT coronal (B)	2.26	0.064	0.8231	-
CBCT sagittal (C)	2.23	0.059	-	0.9076



**Graph 4:** Graphical representation of variation in molar measurements (Sagittal view).

surgical insertion into the parasagittal plane.

In a clinical study by Jung *et al.*, it was established that 98% of the patients had sufficient bone for insertion of a palatal implant as indicated on pre-operative lateral radiographs, regardless of the demographic features or specific dentofacial abnormalities.<sup>[28]</sup> In this series, 23 patients underwent paramedian implant placement. Although the exact dimension of the paramedian bone was not specifically measured in these cases, sufficient bone was found in all cases. Thus, the question that remained to be conclusively answered was the principal necessity of 3-D imaging before paramedian insertion of palatal implants.<sup>[29]</sup> It has been assumed thus far that the vertical bone height as seen on lateral cephalometry corresponds to the quantity of bone in the median plane and, therefore, reflects the maximum quantity of available bone. Hence, we were apprehensive about paramedian insertion as one might come across a bone deficit that escaped detection on lateral cephalometry. A couple of years ago, other work groups Bernhart *et al.*, Bantleon *et al.*, and Gahleiter *et al.* (2004) used 3-D data sets (CBCT and CT data) to inspect the morphological limitations of vertical volume of bone in the midsagittal and paramedian region of the anterior hard palate in relation to the insertion of palatal implants. The results showed a wide spectrum of values with respect to vertical bone height.

Therefore, a pre-operative 3-D evaluation was considered necessary, especially for paramedian insertion of palatal implants. However, no systematic comparisons with lateral radiographs which served as the basic diagnostic procedure were performed. Most interestingly, the study showed that the vertical height of palate on lateral cephalometry and CBCT (median plane) coincides at the level of the upper first premolars. Palatal heights in the median plane determined on CBCT were markedly higher than those registered on lateral radiographs. The data obtained were among the first to confirm that the amount of vertical bone on lateral cephalometry does not reflect the actual existing quantity of vertical bone in the median sagittal plane but usually expresses the minimum quantity of bone. This is confirmed by the association between vertical palatal height on lateral cephalometry and minimum palatal height on CBCT.

## CONCLUSION

Selection of the suitable radiographic imaging technique (or techniques) is based on the principle that practitioners who use imaging with ionizing radiation have a professional responsibility of beneficence that imaging is performed to “serve the patient’s best interests.” This requires that each radiation exposure is warranted clinically and that procedures are applied that minimize patient radiation exposure while optimizing maximal diagnostic benefit. The extension of this principle referred to as the “as low as reasonably achievable” (ALARA)<sup>[30]</sup> to CBCT imaging is supported by the American Dental Association.<sup>[31]</sup> Justification of every radiographic exposure must be based primarily on the individual patient’s presentation including considerations of the chief complaint, medical and dental history, and assessment of the physical status (as determined with a thorough clinical examination) and treatment goals.

The data obtained show that lateral cephalometry provides a reliable valuation of the quantity of vertical palatal bone for paramedian insertion of a palatal implant. In other words, patients with a critical quantity of vertical bone can securely identify on the basis of lateral radiographs. Thus, the evaluation of bone on lateral cephalometry is valid for median as well as paramedian insertion of palatal implants. One further conclusion may be drawn from the results obtained in our study: Keeping in mind, the fact that lateral radiographs show the minimum quantity of

bone, a critically small quantity of bone on a lateral radiograph should allow to perform 3-D imaging and to determine whether sufficient bone for implant insertion is available, for example, in the midpalatal area. Thus, 3-D imaging may extend the spectrum of indications for palatal implants.

Therefore, lateral cephalometry completely accomplishes radiation protection regulations and immediately translates the ALARA principle in the clinical practice. Therefore, a need for a pre-operative CT or CBCT arises only when lateral cephalogram detects a very marginal quantity of bone.

### Acknowledgment

We would like to thank Dr. Manasi Kode for helping us understand and interpret the CBCT scans.

### Declaration of patient consent

Patient's consent not required as patients identity is not disclosed or compromised.

### Financial support and sponsorship

Nil.

### Conflicts of interest

There are no conflicts of interest.

### REFERENCES

- Poggio PM, Incorvati C, Velo S, Carano A. "Safe zones": A guide for miniscrew positioning in the maxillary and mandibular arch. *Angle Orthod* 2006;76:191-7.
- Costa A, Pasta G, Bergamaschi G. Intraoral hard and soft tissue depths for temporary anchorage devices. *Semin Orthod* 2005;11:10-5.
- Deguchi T, Nasu M, Murakami K, Yabuuchi T, Kamioka H, Takano-Yamamoto T, *et al.* Quantitative evaluation of cortical bone thickness with computed tomographic scanning for orthodontic implants. *Am J Orthod Dentofacial Orthop* 2006;129:721.e7-12.
- Wehrbein H, Glatzmaier J, Mundwiler U, Diedrich P. The orthosystem-a new implant system for orthodontic anchorage in the palate. *J Orofac Orthop* 1996;57:142-53.
- Wehrbein H, Merz BR, Hämmerle CH, Lang NP. Bone-to-implant contact of orthodontic implants in humans subjected to horizontal loading. *Clin Oral Implants Res* 1998;9:348-53.
- Wehrbein H, Feifel H, Diedrich P. Palatal implant anchorage reinforcement of posterior teeth: A prospective study. *Am J Orthod Dentofacial Orthop* 1999;116:678-86.
- Wehrbein H, Merz BR, Diedrich P, Glatzmaier J. The use of palatal implants for orthodontic anchorage. Design and clinical application of the orthosystem. *Clin Oral Implants Res* 1996;7:410-6.
- Wehrbein H, Merz BR, Diedrich P. Palatal bone support for orthodontic implant anchorage-a clinical and radiological study. *Eur J Orthod* 1999;21:65-70.
- Misch CE. *Contemporary Implant Dentistry*. 2<sup>nd</sup> ed. St. Louis: Mosby; 1999. p. 113.
- Kyung SH, Hong SG, Park YC. Distalization of maxillary molars with a midpalatal miniscrew. *J Clin Orthod* 2003;37:22-6.
- Bernhart T, Vollgruber A, Gahleitner A, Dörtbudak O, Haas R. Alternative to the median region of the palate for placement of an orthodontic implant. *Clin Oral Implants Res* 2000;11:595-601.
- Schlegel KA, Kinner F, Schlegel KD. The anatomic basis for palatal implants in orthodontics. *Int J Adult Orthodon Orthognath Surg* 2002;17:133-9.
- Martin W, Heffernan M, Ruskin J. Template fabrication for a midpalatal orthodontic implant: Technical note. *Int J Oral Maxillofac Implants* 2002;17:720-2.
- Tosun T, Keles A, Erverdi N. Method for the placement of palatal implants. *Int J Oral Maxillofac Implants* 2002;17:95-100.
- Bantleon H, Bernhart T, Crismani AG, Zachrisson BU. Stable orthodontic anchorage with palatal osseointegrated implants. *World J Orthod* 2002;3:109-16.
- Januzzi E, Leite FM, Primo BT, Grossmann E. Use of osseointegrated implants in the intermaxillary suture: A new possibility for the prosthetic rehabilitation of atrophic maxillae. *Int J Oral Maxillofac Surg* 2013;42:904-6.
- Lee J, Miyazawa K, Tabuchi M, Kawaguchi M, Shibata M, Goto S, *et al.* Midpalatal miniscrews and high-pull headgear for anteroposterior and vertical anchorage control: Cephalometric comparisons of treatment changes. *Am J Orthod Dentofacial Orthop* 2013;144:238-50.
- Kyung SH, Lee JY, Shin JW, Hong C, Dietz V, Gianelly AA, *et al.* Distalization of the entire maxillary arch in an adult. *Am J Orthod Dentofacial Orthop* 2009;135:S123-32.
- Ludwig B, Glasl B, Kinzinger GS, Walde KC, Lisson JA. The skeletal frog appliance for maxillary molar distalization. *J Clin Orthod* 2011;45:77-84.
- Watanabe Y, Miyamoto K. A palatal locking plate anchor for orthodontic tooth movement. *J Clin Orthod* 2009;43:430-7.
- Mah SJ, Kim JE, Ahn EJ, Nam JH, Kim JY, Kang YG, *et al.* Analysis of midpalatal miniscrew-assisted maxillary molar distalization patterns with simultaneous use of fixed appliances: A preliminary study. *Korean J Orthod* 2016;46:55-61.
- Park HS. A miniscrew-assisted transpalatal arch for use in lingual orthodontics. *J Clin Orthod* 2006;40:12-6.
- Kircelli BH, Pektaş ZO, Kircelli C. Maxillary molar distalization with a bone-anchored pendulum appliance. *Angle Orthod* 2006;76:650-9.
- Lee J, Park YC. A Contact Finite Element Analysis for Initial Stability of Orthodontic Miniscrew. Seoul: Orthodontics Department, Yonsei University; 2004.
- Chan HJ, Woods M, Stella D. Mandibular muscle morphology in children with different vertical facial patterns: A 3-dimensional computed tomography study. *Am J Orthod Dentofacial Orthop* 2008;133:10.e1-13.
- Ozdemir F, Tozlu M, Germec-Cakan D. Cortical bone thickness of the alveolar process measured with cone-beam computed tomography in patients with different facial types. *Am J Orthod Dentofacial Orthop* 2013;143:190-6.
- Masumoto T, Hayashi I, Kawamura A, Tanaka K, Kasai K. Relationships among facial type, buccolingual molar inclination, and cortical bone thickness of the mandible. *Eur J Orthod* 2001;23:15-23.
- Jung BA, Wehrbein H, Heuser L, Kunkel M. Vertical palatal bone dimensions on lateral cephalometry and cone-beam computed

- tomography: Implications for palatal implant placement. *Clin Oral Implants Res* 2011;22:664-8.
29. King KS, Lam EW, Faulkner MG, Heo G, Major PW. Vertical bone volume in the paramedian palate of adolescents: A computed tomography study. *Am J Orthod Dentofacial Orthop* 2007;132:783-8.
30. National Council on Radiation Protection and Measurements. Radiation Protection in Dentistry (Report No. 145). Bethesda, MD: NRC Publications; 2003.
31. American Dental Association Council on Scientific Affairs. The use of cone-beam computed tomography in dentistry: An advisory statement from the American dental association council on scientific affairs. *J Am Dent Assoc* 2012;143:899-902.

**How to cite this article:** Patni VJ, Kate SR, Potnis SS, Kolge NE. A simplified method for measurement of palatal bone thickness to select the optimum length of orthodontic mini-implant. *APOS Trends Orthod* 2019;9(1):52-8.