

Periodontally accelerated osteogenic orthodontics

Shailesh Mohanlal Bhandari

Panineeya Institute of Dental
Sciences and Research Centre,
Hyderabad, Telangana, India

Abstract

This case report demonstrates an orthodontic method that offers short treatment time and the ability to simultaneously reshape and increase the buccolingual thickness of the supporting alveolar bone. A 23-year-old female with Angle's Class I moderately to severely crowded malocclusion with periodontal pocket with 31 and reduced thickness of the buccal cortical plate of lower anteriors, requested shortened orthodontic treatment time. This surgery technique included buccal full-thickness flaps, selective partial decortication of the cortical plates, concomitant bone grafting/augmentation, and primary flap closure. Following the surgery, orthodontic adjustments were made approximately every 2 weeks. From bracketing to debracketing, the case was completed in approximately 7 months and 3 weeks. Posttreatment evaluation of patient revealed good results. Preexisting thin labial bony cortical plate with lower anteriors was covered. This finding suggests credence to the incorporation of the bone augmentation procedure into the corticotomy surgery because this made it possible to complete the orthodontic treatment with a more intact periodontium. The rapid expansive tooth movements with no significant apical root resorption may be attributed to the osteoclastic or catabolic phase of the regional acceleratory phenomenon.

Key words: Accelerated orthodontics, interdisciplinary treatment, periodontal pathologies

INTRODUCTION

Periodontal accelerated osteogenic orthodontics (PAOO) is a clinical procedure that combines selective alveolar corticotomy, particulate bone grafting, and the application of orthodontic forces.^[1] This procedure is theoretically based on the bone healing pattern known as the regional acceleratory phenomenon (RAP).^[2] PAOO, as claimed by distinguished authors, helps in an increase in alveolar bone width,^[3] shorter treatment time,^[4] increased posttreatment stability,^[5] and decreased amount of apical root resorption.^[6] The purpose of this article is to describe a case report that comprises the PAOO procedure.

Kole^[7] believed that the surgical preparation of the alveolus would permit rapid tooth movement, suggesting that it was the continuity and thickness of the denser layer of cortical bone that offered the most resistance to tooth movement. Kole's interpretation of the rapid tooth movement being attributable to "bony block" movement did prevail until the 2001 publication of Wilcko *et al.*^[1] Case reports were presented, in which computed tomography scan evaluation of patients who had undergone corticotomy showed that the rapid tooth movement was not the result of bony block movement but rather a transient localized demineralization/remineralization process in the bony alveolar housing consistent with the wound healing pattern of the RAP.^[7] Wilcko *et al.*^[1] proposed that after the demineralization of the alveolar housing over the root surfaces, a soft tissue matrix of the bone, which could be carried with the root

Access this article online

Quick Response Code:



Website:

www.apospublications.com

DOI:

10.4103/2321-1407.190748

| | |
|----------------------------|--------------------------------------|
| Access this article online | |
| Quick Response Code: | Website: www.apospublications.com |
| | DOI: 10.4103/2321-1407.190748 |

Address for Correspondence:

Dr. Shailesh Mohanlal Bhandari, Saraf Bazar, Mahavir Path,
Manmad - 423 104, Maharashtra, India.
E-mail: shailsbds@gmail.com

This is an open access article distributed under the terms of the Creative Commons Attribution-NonCommercial-ShareAlike 3.0 License, which allows others to remix, tweak, and build upon the work non-commercially, as long as the author is credited and the new creations are licensed under the identical terms.

For reprints contact: reprints@medknow.com

How to cite this article: Bhandari SM. Periodontally accelerated osteogenic orthodontics. APOS Trends Orthod 2016;6:265-70.

and later remineralize, occurred after the completion of the orthodontic treatment. In an effort to enhance bony volumes, after the application of orthodontic forces, they also suggested the use of particulate bone grafting in combination with the decortications procedures. Wilcko combined the refined corticotomy-facilitated orthodontic technique with alveolar augmentation and named the orthodontic and periodontal aspects of this procedure the AOO technique, and more recently, the PAOO surgical technique, respectively.

CASE REPORT

PAOO has been shown to be efficacious in the treatment of Class I malocclusions with moderate to severe crowding, Class II malocclusions requiring expansion or extractions, and mild Class III malocclusions. Careful coordination between the surgeon and orthodontist is required for successful outcomes. It is suggested that both the surgeon and orthodontist be trained together in the use of this technique to ensure a common basis of knowledge. The surgical specialist must also evaluate the esthetic needs of the patient and incorporate these requirements into the surgical treatment plan. For example, if a patient presents with the gingival recession in an area requiring corticotomy, a subepithelial connective tissue graft can be placed in conjunction with the PAOO surgery.

The placement of orthodontic brackets and activation of the archwires are typically done the week before the surgical

aspect of PAOO is performed. However, bracketing can occur up to 1–2 weeks after surgery. If complex mucogingival procedures are combined with the PAOO surgery, the lack of fixed orthodontic appliances may enable easier flap manipulation and suturing. In all cases, initiation of orthodontic force should not be delayed more than 2 weeks after surgery. A longer delay will fail to take full advantage of the limited period that the RAP is occurring.

The orthodontist has a limited amount of time to accomplish accelerated tooth movement. This period is usually 4–6 months after which finishing movements occur with normal speed. Given this limited “window” of rapid movement, the orthodontist will need to advance archwire sizes rapidly, initially engaging the largest archwire possible.

Diagnosis and etiology

A 23-year-old postpubertal female patient wanted to improve esthetics of her smile. She presented with Angle's Class I malocclusion on a Class I skeletal base, hypodivergence, crowding with upper and lower anteriors, periodontal pocket with 31 and reduced thickness of buccal cortical plate of lower anteriors, with straight profile, and decreased lower facial height and missing 27 and erupting 28 [Figures 1 and 2]. The possible etiology of crowding can be traced to arch length tooth size discrepancy. The patient's gingival health was reasonably good except with lower anteriors and her oral hygiene was satisfactory. Sulcus depths were in the normal range in most areas, with no bleeding on probing. Her temporomandibular

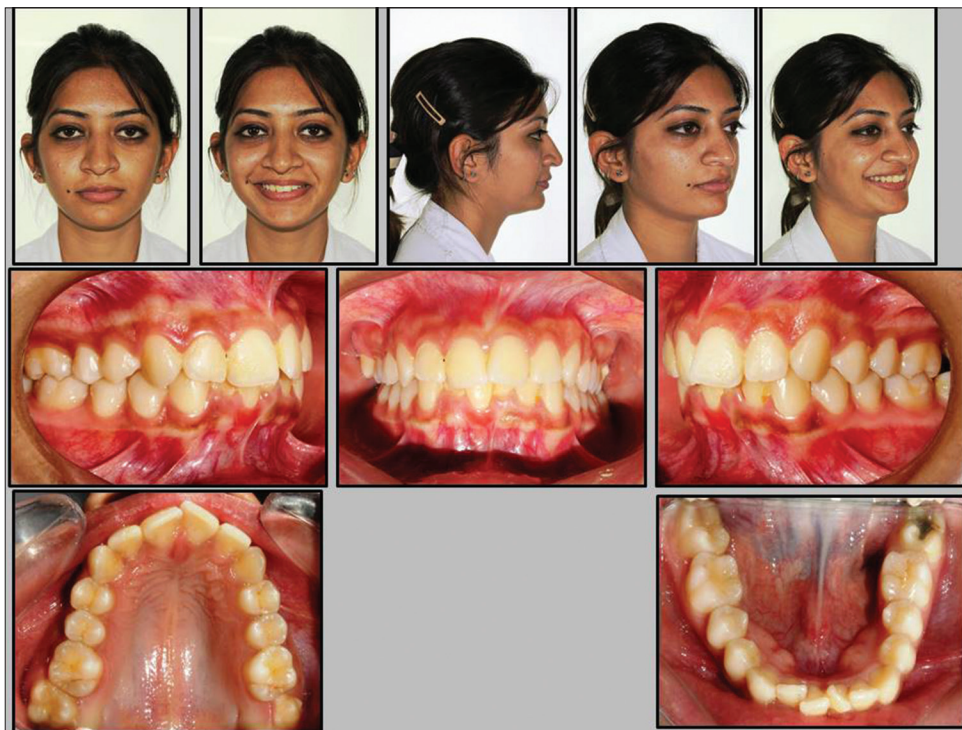


Figure 1: Pretreatment photographs

joints were asymptomatic. Her goal was to have better smile esthetics.

Treatment objectives

- Correction of periodontal problem with lower anteriors
- Correction of anterior deep bite and lower anterior crowding without compromising the thin labial cortical plate
- Correction of rotated teeth.

Treatment alternatives

Several orthodontic treatment alternatives could have been employed to achieve these aforementioned goals or objectives:

1. Alignment of upper and lower anteriors to their proper position in the arch and closure of space in lower arch with the extraction of lower single incisor for correction of curve of Spee and Bolton's discrepancy. Contemplating the distance to be moved for derotating the lower incisors to their normal position in the arch, there was further risk of iatrogenic dehiscence and fenestration with lower anteriors. The patient wanted to save her natural teeth and opposed any extraction of teeth. Hence, this treatment plan was neglected
2. Because of the scarcity of attached fibrotic gingiva, the prominence of the roots, and the fact that these teeth would be expanded facially, free gingival grafting with freeze dries bone graft of lower anterior teeth was deemed advisable. It was hoped that the increased zone of attached fibrotic gingiva would lessen the likelihood of significant additional gingival recession. It was, however, explained to the patient that because of the reduction in the height of the crestal bone that had resulted from the earlier periodontal disease

in some areas she might experience some additional gingival shrinkage. All teeth registered vital to ice. All of the erupted teeth were designated for expansive movement (decrowding). The orthodontic treatment plan included maxillary and mandibular braces and pure orthodontic expansion of the arches to assist in correcting the crowding. When presented with the option of completing the orthodontic treatment in about 1/4–1/3 of the time needed for conventional orthodontic treatment and reduced risk of further periodontal problems, she readily accepted the new treatment method. She had no objection to the inclusion of a periodontal plastic surgical procedure with resorbable grafting materials. The patient was informed of the possible sequelae to her decisions.

Treatment progress

A thorough scaling before orthodontic banding was done, with maintenance appointments for tooth cleaning every 4 months during active orthodontics. Orthodontic brackets McLaughlin, Bennett, Terevisi 0.22" × 0.028" slot (3M Clarity SL*) were placed on all teeth in both arches [Figure 3].

Surgical technique

The objectives of the flap design were to: (1) Provide access to the alveolar bone wherein corticotomies are to be performed, (2) provide for coverage of the particulate graft, (3) maintain the height and volume of the interdental tissues, and (4) enhance the esthetic appearance of the gingival form where necessary.

The purpose of the decortication was to initiate the RAP response and not to create movable bone segments. By the use of no. 2 round bur in a high-speed handpiece, decortications were made in the alveolar bone. The corticotomies were placed on the labial aspect of the

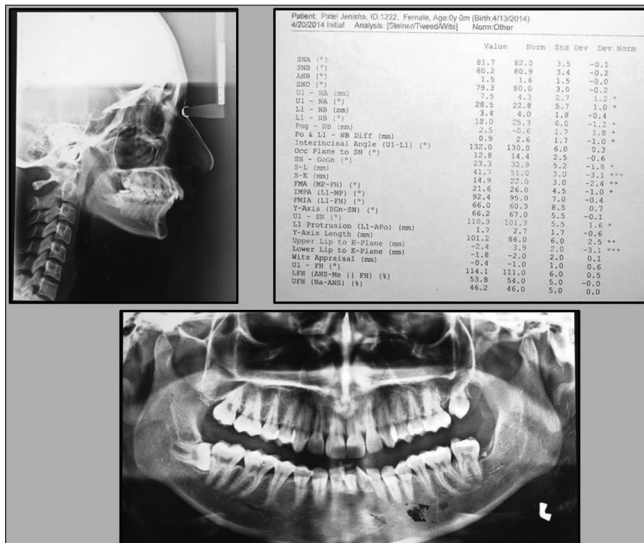


Figure 2: Pretreatment Lat Ceph and orthopantomogram

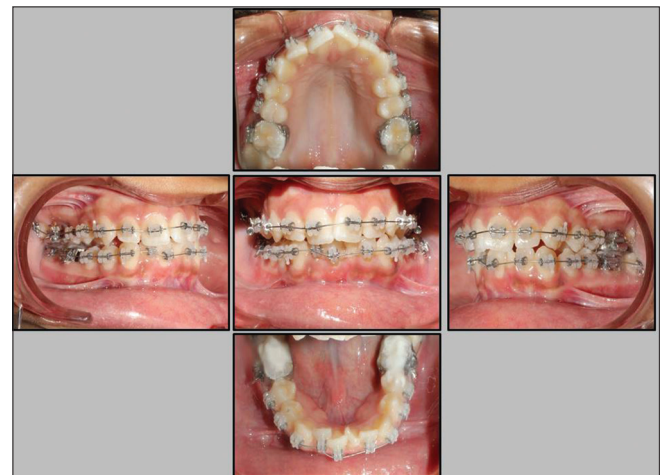

Figure 3: Initial bonding photographs

alveolar bone in the lower anterior region. Typically, a vertical groove was placed in the inter-radicular space, midway between the root prominences in the alveolar bone. This groove extended from a point 2–3 mm below the crest of the bone to a point 2 mm beyond the apices of the roots. These vertical corticotomies were then connected with a circular-shaped corticotomy. Solitary perforations were placed in the alveolar bone over the radicular surface [Figure 4].

Grafting was done in most areas that have undergone corticotomies. The volume of the graft material used was dictated by the direction and amount of tooth movement, the pretreatment thickness of the alveolar bone, and the need for labial support by the alveolar bone. The graft material used was decalcified freeze-dried bone allograft. A typical volume used was 0.25–0.5 mL of graft material per tooth. The decorticated bone acts to retain the graft material [Figure 5].

Primary closure of the gingival flaps without excessive tension and graft containment were the therapeutic endpoints of suturing. These were typically achieved with nonresorbable interrupted sutures. The sutures that approximate the tissues at the midline were placed first to ensure the proper alignment of the papillae. The remaining interproximal sutures were placed next followed by the closure of any vertical incisions. No packing was required. The sutures were left in place for 1 week [Figure 6].

The short-term steroids were given orally, which enhanced patient comfort and clinical healing. Antibiotics and pain medications were administered. However, long-term postoperative administration of nonsteroidal anti-inflammatory agents is discouraged because they may theoretically interfere with the regional acceleratory process. The application of icepacks to the affected areas also was suggested to decrease the severity of any possible postoperative swelling or edema. The most commonly reported postsurgical complications are edema and ecchymosis, both of which are self-limiting. The patient returned for postsurgical evaluation and gentle prophylaxis every week for the 1st month and then monthly thereafter.

Treatment results

This interdisciplinary approach to managing this patient's occlusal, gingival, and esthetic discrepancies allowed the team to achieve all of the periodontal and orthodontic objectives that were established before treatment within 7 months and 3 weeks [Figure 7]. Her facial profile did not change. Her maxillary and mandibular anterior dental esthetics has been improved. The patient has canine-protected occlusion bilaterally with no balancing interferences.

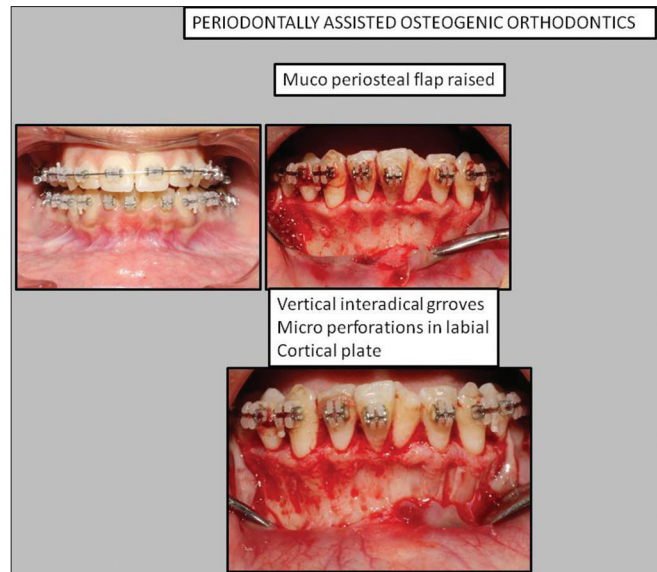


Figure 4: Corticotomy cuts photographs

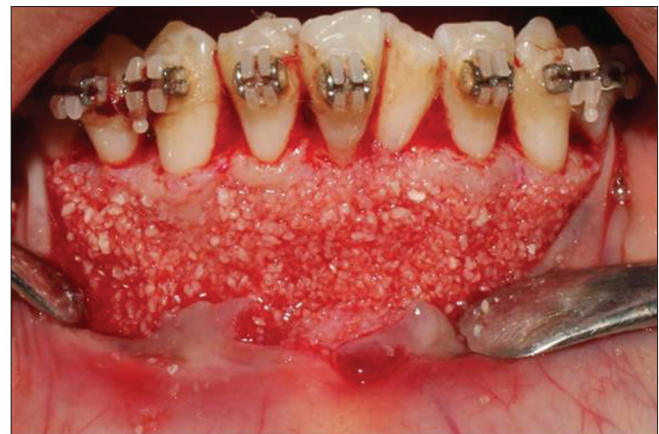

Figure 5: Graft placement photographs

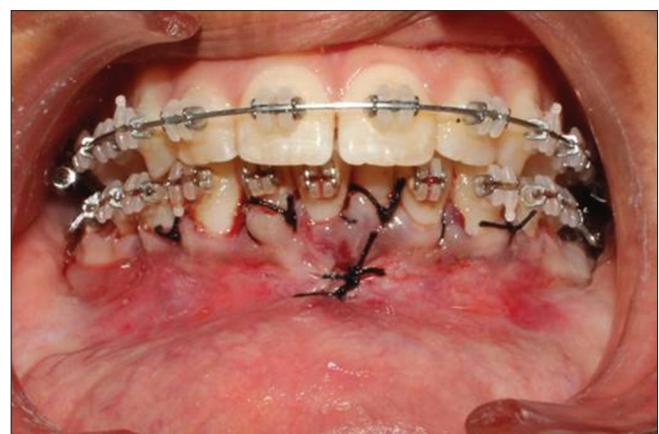

Figure 6: Flap suturing photographs

DISCUSSION

PAOO is an extension of previously described techniques that surgically alter the alveolar bone to decrease treatment

successful coordination of the orthodontic and surgical specialists. Without this coordination of the treatment plan and therapy, chances for a successful treatment outcome are decreased.

Declaration of patient consent

The authors certify that they have obtained all appropriate patient consent forms. In the form the patient(s) has/have given his/her/their consent for his/her/their images and other clinical information to be reported in the journal. The patients understand that their names and initials will not be published and due efforts will be made to conceal their identity, but anonymity cannot be guaranteed.

Financial support and sponsorship

Nil.

Conflicts of interest

There are no conflicts of interest.

REFERENCES

1. Wilcko WM, Wilcko T, Bouquot JE, Ferguson DJ. Rapid orthodontics with alveolar reshaping: Two case reports of decrowding. *Int J Periodontics Restorative Dent* 2001;21:9-19.
2. Pham-Nguyen K. Micro-CT Analysis of Osteopenia Following Selective Alveolar Decortication and Tooth Movement [Master's Thesis]. Boston, MA: Boston University; 2006.
3. Twaddle BA, Ferguson DJ, Wilcko WM, Wilcko MT. Dento-alveolar bone density changes following corticotomy-facilitated orthodontics. *J Dent Res* 2002;80:301.
4. Hajji SS. The influence of the accelerated osteogenic response on mandibular decrowding. *J Dent Res* 2001;30:180.
5. Nazarov AD, Ferguson DJ, Wilcko WM, Wilcko MT. Improved orthodontic retention following corticotomy using ABO objective grading system [abstract]. *J Dent Res* 2004;83:2644.
6. Machado IM, Ferguson DJ, Wilcko WM. Root resorption after orthodontic treatment with or without alveolar corticotomy. *Rev Venez Ortod* 2002;19:647.
7. Kole H. Surgical operations on the alveolar ridge to correct occlusal abnormalities. *Oral Surg Oral Med Oral Pathol* 1959;12:515-29.
8. Frost HM. The biology of fracture healing. An overview for clinicians. Part I. *Clin Orthop Relat Res* 1989;248:283-93.
9. Frost HM. The biology of fracture healing. An overview for clinicians. Part II. *Clin Orthop Relat Res* 1989;248:294-309.
10. Shih MS, Norrdin RW. Regional acceleration of remodeling during healing of bone defects in beagles of various ages. *Bone* 1985;6:377-9.
11. Goldie RS, King GJ. Root resorption and tooth movement in orthodontically treated, calcium-deficient, and lactating rats. *Am J Orthod* 1984;85:424-30.
12. Nyman S, Karring T, Bergenholtz G. Bone regeneration in alveolar bone dehiscences produced by jiggling forces. *J Periodontal Res* 1982;17:316-22.