

Intrusion of over-erupted maxillary first molar using a mandibular removable acrylic bite plate

Namit Nagar, Pratik Gupta,
Prabhuraj Kambalyal¹

Departments of Orthodontics and
Dentofacial Orthopedics, Pacific
Dental College and Hospital, Udaipur,
¹Darshan Dental College and Hospital,
Udaipur, Rajasthan, India

Abstract

Over-eruption of maxillary molar because of loss of the opposing teeth creates occlusal interference and functional disturbances. To provide prosthetic treatment of the missing teeth, these over-erupted teeth need to be intruded, but molar intrusion is difficult in adults. In this report, we present a simplified version of the orthodontic appliances in conjunction with lower removable acrylic bite plate to intrude the over-erupted molars. The method advocated here, uses a removable acrylic plate resulting in a true molar intrusion, thus eliminating an additional surgical step of implant placement. The results showed that the biological responses of the teeth and the surrounding bony structures to the intrusion appeared normal and acceptable.

Key words: Bite plate, implant, molar intrusion

INTRODUCTION

Patients who have over-erupted molars due to the loss of antagonists are a common clinical finding. To provide prosthetic treatment of the missing teeth, these over-erupted teeth need to be intruded, but molar intrusion is difficult in adults.^[1,2]

To reconstruct the proper occlusion for the posterior dentition and to maintain periodontal health, an interdisciplinary and comprehensive dental treatment is necessary. Correction of the over-erupted molar is a first and essential step before other procedures can be started. Procedures such as orthodontic intrusion, prosthodontic reduction, and surgical impaction have been presented.^[3-8] However, prosthodontic reduction requires endodontic intervention and crown restoration at the expense of tooth vitality, whereas surgical impaction involves an aggressive segmental operation.

Grinding the over-erupted tooth is quick and easy, but in severe cases, the teeth need to be treated endodontically.^[9]

Various methods of molar intrusion using micro-implants, mini-plates etc., have been advocated.^[10-12] We have devised a simplified method of molar intrusion using a removable lower acrylic bite plate.

CASE REPORTS

An adult patient aged 25 years reported prosthetic department seeking replacement of missing lower right first molar. Patient was referred to orthodontics, as over-eruption of upper first molar hampered the proper replacement of missing tooth [Figure 1a-c]. We advocated a simple method of molar intrusion using a removable acrylic plate.

PROCEDURE

Upper arch was strapped up using a MBT 0.022 × 0.028” bracket prescription and initial flexible arch wires were ligated.

A lower removable acrylic bite plate was fabricated with posterior bite block occupying the space created by missing lower molar [Figure 2a and b].

Access this article online

Quick Response Code:



Website:

www.apospublications.com

DOI:

10.4103/2321-1407.142920

Address for Correspondence:

Dr. Pratik Gupta, A/2 Krupa Riddhi Apartment, Near Ghosha Society, Thaltej, Ahmedabad, Gujarat, India.
E-mail: drpratikgupta@gmail.com

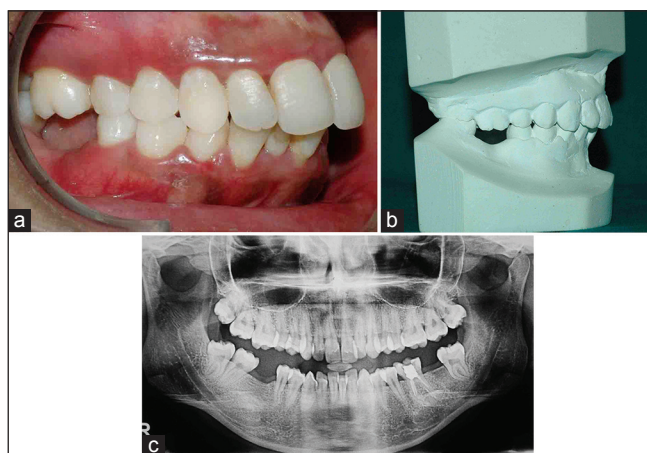


Figure 1: (a) Intra-oral right view depicting over-erupted maxillary molar. (b) Study model showing over-erupted maxillary molar. (c) Pretreatment Orthopentogram

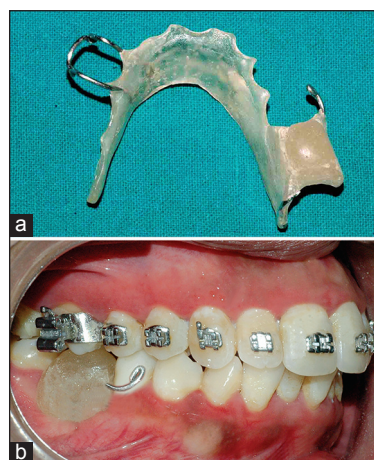


Figure 2: (a) Lower acrylic bite plate. (b) Intra-oral view of bite plate

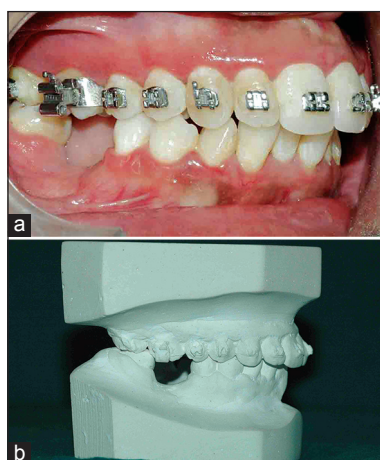


Figure 3: (a) Intra-oral right view depicting intruded maxillary molar. (b) Study model showing intruded maxillary molar

The bite block occlusal surface was kept flat in order to apply an even intrusion force onto upper molar. Clasps were embedded in acrylic plate to enhance retention. Patient was instructed about plate placement and was insisted to wear the plate during mastication also.

After 3 months of active therapy, significant intrusion of maxillary molar was observed [Figure 3a and b]. Sagging of palatal cusp of upper molar was not seen, depicting true intrusion. Superimposition of cephalograms showed intrusion of maxillary molar by about 2 mm [Figure 4].

CONCLUSION

Various methods like mini-implants, mini-plates have been used for intrusion of upper molar due to missing lower molar. These methods require an additional step of placing implants or mini-plates. True intrusion of upper

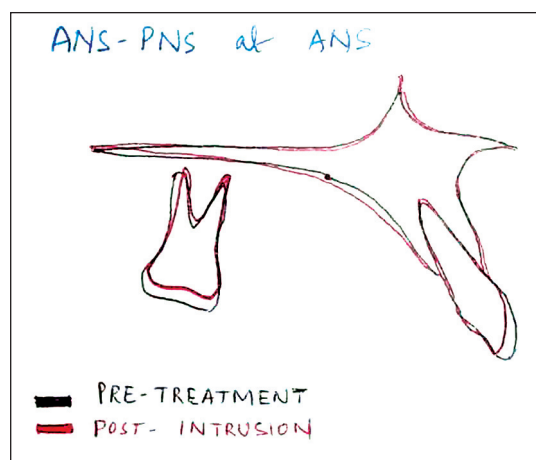


Figure 4: Cephalometric superimpositions

molar mostly requires implants to be placed on both buccal and palatal sides. The method advocated here, uses a removable acrylic plate resulting in a true molar intrusion, thus eliminating an additional surgical step of implant placement. The results showed that the biological responses of the teeth and the surrounding bony structures to the intrusion appeared normal and acceptable.

REFERENCES

1. Melsen B. Limitation in adult orthodontics. In: Melsen B, editor. *Current Controversies in Orthodontics*. Chicago, Ill: Quintessence; 1991. p. 147-80.
2. Suya H. Corticotomy in orthodontics. In: Hošl E, Baldauf A, editors. *Mechanical and Biological Basics in Orthodontic Therapy*. Heidelberg, Germany: Hüthig; 1991. p. 207-26.
3. White R, Terry B. Segmental jaw surgery. In: Proffit W, White R, editors. *Surgical-Orthodontic Treatment*. St. Louis, Mo: Mosby; 1991. p. 283-319.
4. Smith B. Occlusal considerations. In: Smith B, editor. *Planning and Making Crowns and Bridges*. 1st ed. London, UK: Martin Dunitz; 1987. p. 58-77.
5. Rosen PS, Forman D. The role of orthognathic surgery in the treatment of severe dentoalveolar extrusion. *J Am Dent Assoc* 1999;130:1619-22.

6. Daly PF, Pitsillis A, Nicolopoulos C. Occlusal reconstruction of a collapsed bite by orthodontic treatment, pre-prosthetic surgery and implant supported prostheses. A case report. SADJ 2001;56:278-82.
7. Belinfante LS, Abney JM Jr. A teamwork approach to correct a severe prosthodontic problem. J Am Dent Assoc 1975;91:357-9.
8. Alexander JM, Van Sickels JE. Posterior maxillary osteotomies: An aid for a difficult prosthodontic problem. J Prosthet Dent 1979;41:614-7.
9. Miller TE. Orthodontic therapy for the restorative patient. Part I: The biomechanic aspects. J Prosthet Dent 1989;61:268-76.
10. Yao CC, Wu CB, Wu HY, Kok SH, Chang HF, Chen YJ. Intrusion of the overerupted upper left first and second molars by mini-implants with partial-fixed orthodontic appliances: A case report. Angle Orthod 2004;74:550-7.
11. Lin J, Liou E, Chin-Lang Y. Intrusion of over-erupted maxillary molar with mini-screw anchorage. J Clin Orthod 2006;40:378-83.
12. Moon CH, Wee JU, Lee HS. Intrusion of overerupted molars by corticotomy and orthodontic skeletal anchorage. Angle Orthod 2007;77:1119-25.

How to cite this article: Nagar N, Gupta P, Kambalyal P. Intrusion of over-erupted maxillary first molar using a mandibular removable acrylic bite plate. APOS Trends Orthod 2014;4:180-2.

Source of Support: Nil. **Conflict of Interest:** None declared.