

Skeletal class II malocclusion correction using the Bass appliance

Jigar Doshi,
Tarulatha Revanappa Shyagali,
Kalyani M. Trivedi¹

*Departments of Orthodontics and
Dentofacial Orthopedics, Darshan
Dental College and Hospital, Loyara,
Udaipur, Rajasthan, ¹Karnavati
School of Dentistry, Ahmedabad,
Gujarat, India*

Abstract

Skeletal class II malocclusion is best treated by growth modification using the myofunctional appliances or the orthopedic appliances or the combination of the both depending upon the type of malocclusion encountered during the growth period of an individual. Though all myofunctional appliances work on the same principle with few basic differences; the orthodontist has to make a choice among the plethora of the appliances at his disposal. The present article is a case report of class II malocclusion treatment using the Bass appliance for the growth modification, which was followed by fixed appliance for the occlusal detailing.

Key words: Bass appliance, class II malocclusion, growth modification, myofunctional appliance

INTRODUCTION

Class II division 2 malocclusion is characterized by the retroclined maxillary incisors along with a complete deep bite in the anterior region which results in concomitant functional retrusion or locking of the mandible^[1,2] and the pathognomonic cephalometric characteristic include, the orthognathic maxilla, retrognathic mandible, prominent chin, hypo-divergent growth pattern, and the retroclined upper incisors.^[3] The usual treatment strategy is to procline the upper anterior teeth and convert the malocclusion to class II division 1 and then treat accordingly.^[4]

Functional appliances enhance forward mandibular growth and restrain the maxillary forward growth and remove the muscular imbalance if any in such cases.^[5]

The efficacy of functional appliance with the progressive advancement increased in comparison to the one-step advancement.^[6,7] The Bass appliance is one such appliance which, is capable of the sequential advancement.^[6] The present article is a report of one such case of class II division 2 malocclusion using the Bass appliance.

CASE REPORT

A 13-year-old male patient presented himself with the chief complaint of irregularly placed upper front teeth. On examination, he had a convex profile with prognathic maxilla, retrognathic mandible and posterior divergence [Figure 1a-d]. He had acute nasolabial angle, potentially incompetent lips with deep mentolabial sulcus.

On hard tissue examination [Figure 2a-e], full set of teeth were present in all four quadrant except for the third molars. Generalized enamel hypoplasia was present. Incisors were in class II division 2 relationship. Crowding was seen in both upper and lower arches. Molars and canines were in class II relationship on both the side. Over jet at the lateral incisor region was 6 mm, and the overbite was 10 mm. The functional examination revealed retrusive

Access this article online

Quick Response Code:



Website:

www.apospublications.com

DOI:

10.4103/2321-1407.148031

Address for Correspondence:

Dr. Tarulatha Revanappa Shyagali, GBH American Hospital, 101, Kothi Bhag, Bhattji Ki Bhari, Udaipur - 313 001, Rajasthan, India.
E-mail: drtarulatha@gmail.com

path of closure of mandible and the freeway space was found to be 4 mm.

The radiographic examination [Figures 3a and 4a] presented with skeletal class II jaw bases with average growth pattern and retroclined upper and lower incisors [Table 1]. The Bolton's model analysis showed mandibular teeth excess in both the overall ratio (4.7 mm) and anterior tooth material ratio (5 mm) calculation.

Diagnosis

It was a case of growing skeletal class II malocclusion with Angle's class II division 2 dentoalveolar pattern with prognathic maxilla and retrognathic mandible and average growth pattern.

Treatment objectives

1. Controlling the skeletal class II growth pattern by restricting the maxillary growth and allowing the mandibular growth
2. Aligning the position of upper and lower incisors for proper axial inclination
3. To bring about correct overbite and over jet.

Treatment alternatives and treatment plan

Two-phase treatment was planned. In the first-phase growth modification using Bass appliance with high-pull headgear therapy was planned and was followed by MBT preadjusted edgewise appliance (0.22") for occlusal detailing.

Alternatively, a protraction utility arch in the upper, followed by the myofunctional appliance and the fixed appliance or else a myofunctional appliance with the "Z" spring and expansion screw, followed by the fixed appliance could have been done. Nonetheless, Bass appliance was chosen over the other myofunctional appliances as it was capable of producing sequential advancement, without the need of constructing the new appliance every time when we are advancing the bite or adding the acrylic on the

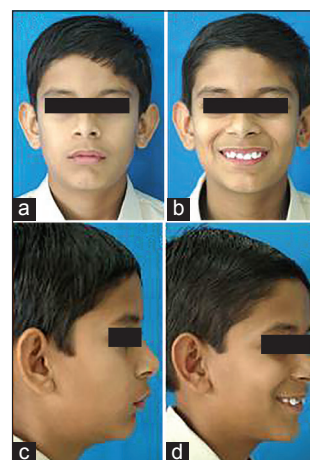


Figure 1: (a-d) Pretreatment extraoral photographs

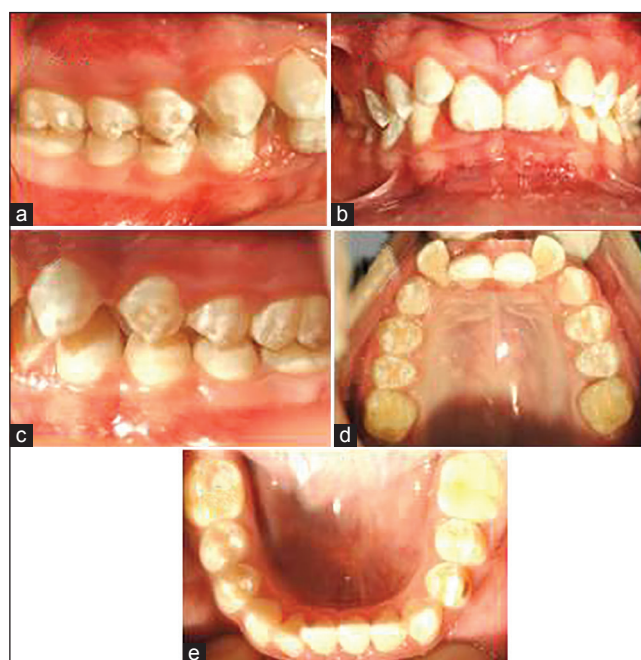

Figure 2: (a-e) Pretreatment intraoral photographs

Table 1: Cephalometric tracing reading

Parameters	Pretreatment	After functional appliance treatment	Posttreatment
SNA	85°	84°	84°
SNB	77°	78°	81°
ANB	8°	6°	3°
SN-MP	32°	35°	24°
U1-SN plane	86°	120°	112°
L1-MAN plane	85°	82°	94°
U1-NA (angle)	0°	30°	23°
U1-NA (linear)	-4 mm	6 mm	4 mm
L1-NB (angle)	13°	15°	25°
L1-NB (linear)	4 mm	3 mm	8 mm

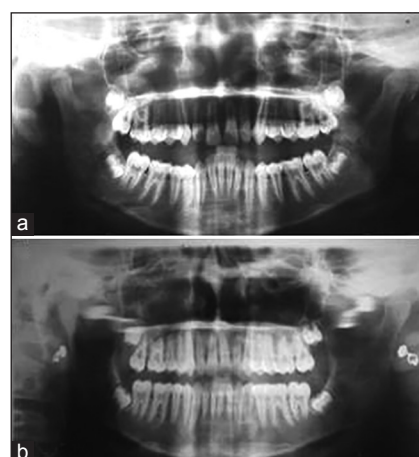


Figure 3: Orthopantomograph. (a) Pretreatment. (b) Posttreatment

twin block for reactivation apart from this, the sequential advancement was an added advantage, as it produced the efficient treatment results.^[6,7]

Treatment progress

The treatment was started by the placement of Bass appliance without the buccal phalanges, and the incremental mandibular growth was stimulated with the lingual pads [Figure 5a-f]. The appliance was constructed as per the recommendation of the available literature.^[6,8] The occipital pull head gear was given to restrain the further forward growth of the maxilla [Figure 6a and b]. The force of the head gear was kept at 500 g per side, and the duration of wear was minimum 12 h. The appliance also had the spring that produced the labial component of force on the incisors for the correction of axial inclination [Figure 5c]. Once the desired result of mandibular advancement was achieved [Figures 7a-d and 8a-e], both the arches were bonded with 3M Unitek Gemini series 022” slot brackets. The initial arch wire was 014. NiTi in both the arches. The head gear and the reverse inclined

plane were given for the retention of the results achieved [Figure 9a-e].

After the initial wire 0.016” × 0.022” NiTi, followed by 0.019” × 0.025” NiTi [Figure 10a-e] and 0.019” × 0.025” stainless steel with L-hooks were placed for the sequential leveling. Active tie backs were given to close the residual spaces acquired due to the proclination of the incisors [Figure 11a-e]. Finishing and detailing was carried out by using the 0.019” × 0.025” TMA wire.

Treatment results

Posttreatment photographs revealed pleasing profile with well aligned arches [Figures 12a-d and 13a-e]. Total duration of the treatment was 3 years. Retention protocol involved the full time wear of removable Begg retainers in the upper

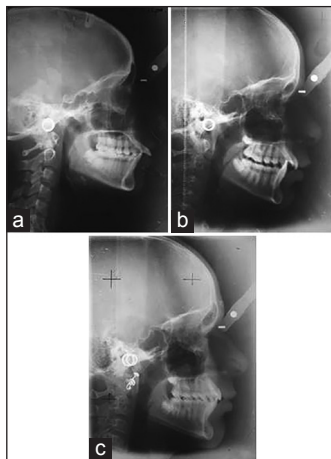


Figure 4: Lateral cephalograph. (a) Pretreatment. (b) Postfunctional appliance. (c) Posttreatment

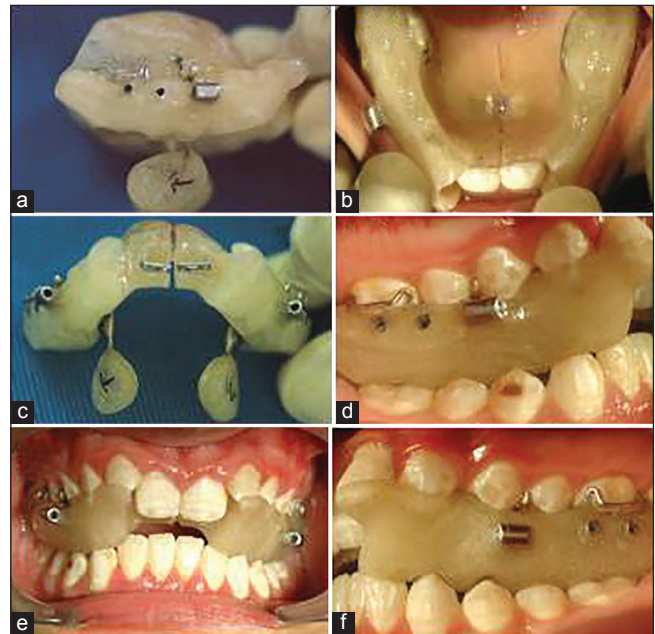


Figure 5: (a-f) Intraoral view of the Bass appliance

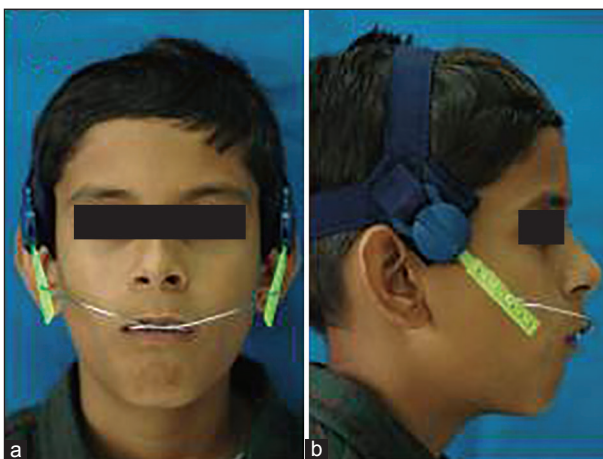

Figure 6: (a, b) Patient wearing head gear

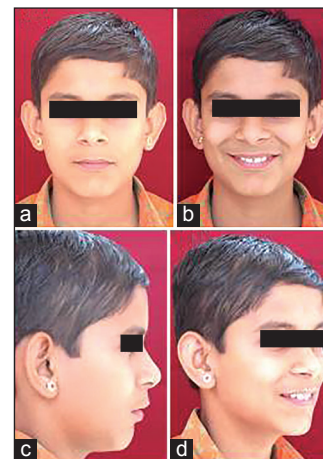


Figure 7: (a-d) Postfunctional appliance extraoral photographs

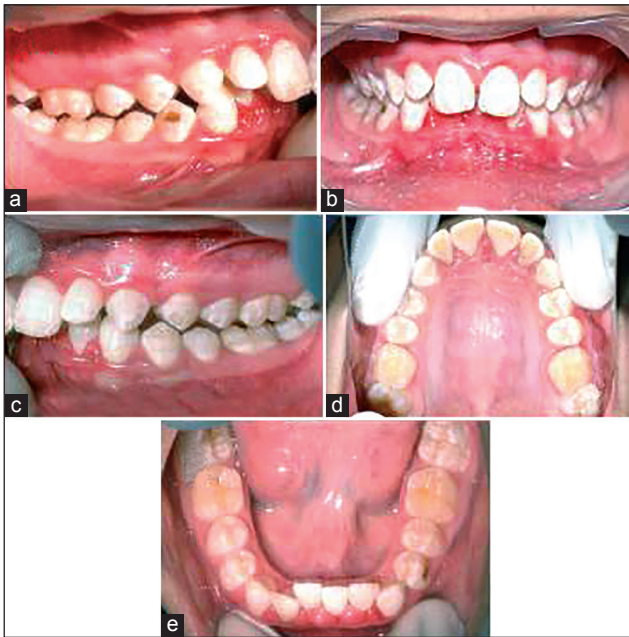

Figure 8: (a-e) Postfunctional appliance intraoral photographs

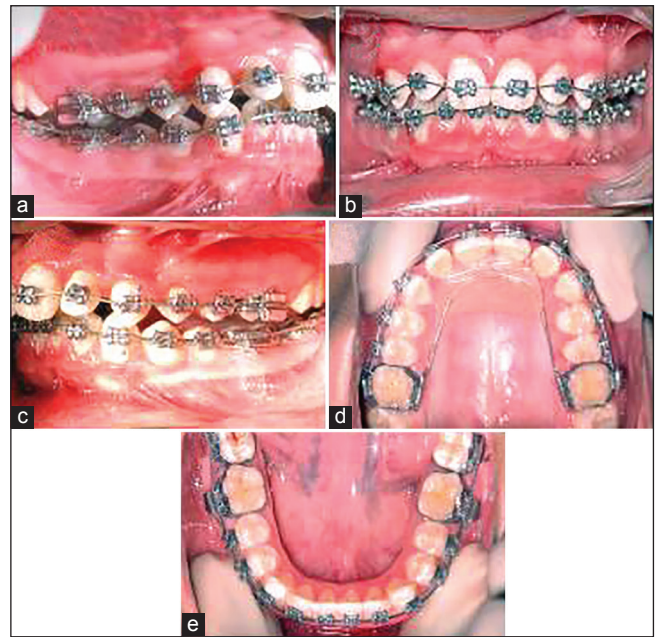

Figure 9: (a-e) Leveling and aligning photographs

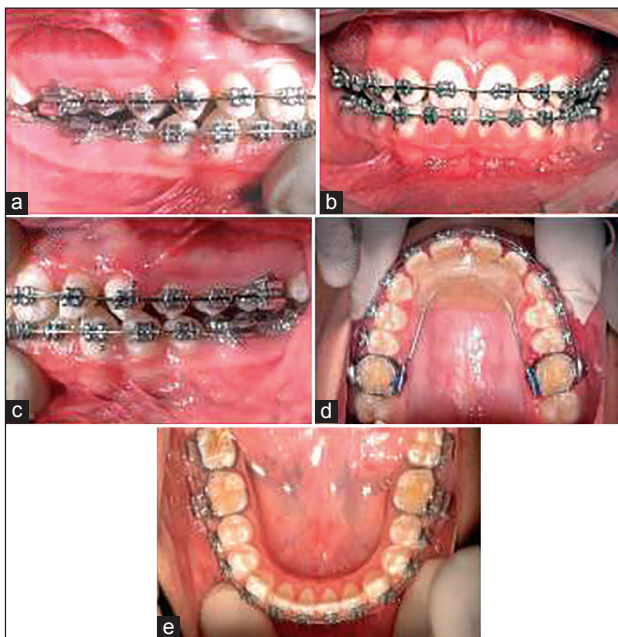


Figure 10: (a-e) Mid-treatment photographs

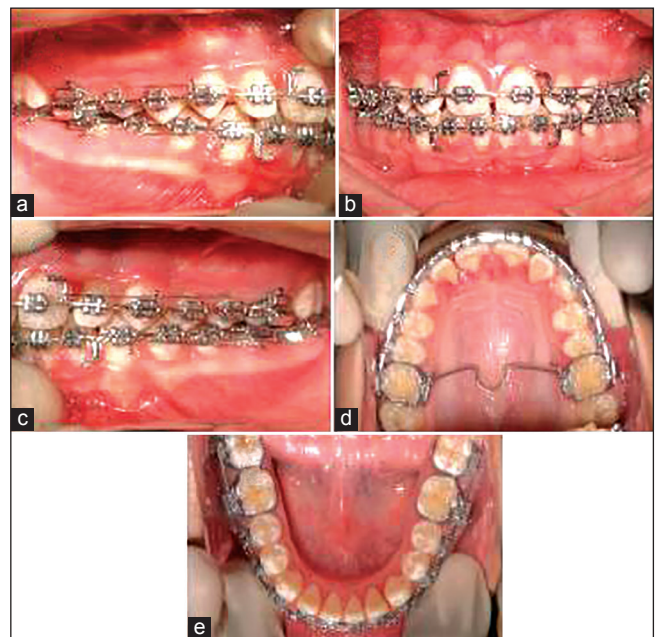


Figure 11: (a-e) Retraction phase

and lower arches. Reverse inclined plane was incorporated in the upper retainer to maintain the results achieved by the Bass appliance.

The overall superimposition [Figure 14a-c] showed that the good mandibular growth and restrict maxillary growth. The vertical component of growth was maintained throughout the treatment. The comparison of the pre-lateral and the postlateral cephalometric reading [Figure 4a-c, Table 1] showed reduction in the class II skeletal pattern along with the restriction of growth in a

vertical direction. The post-treatment of OPG is shown in Figure 3b.

DISCUSSION

The constructed Bass appliance for this particular patient was different from the original design suggested by Bass.^[6,8] The constructed appliance did not have the vestibular phalanges for the soft tissue screen as the buccal musculature was found to be normal. When the visual treatment objective was assessed,

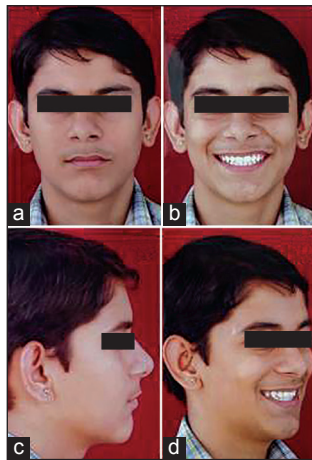


Figure 12: (a-d) Posttreatment extraoral photographs

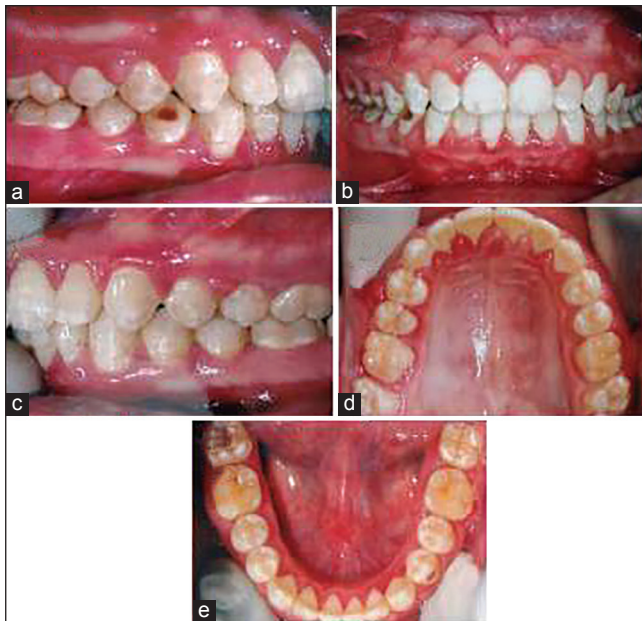

Figure 13: (a-e) Posttreatment intraoral photographs

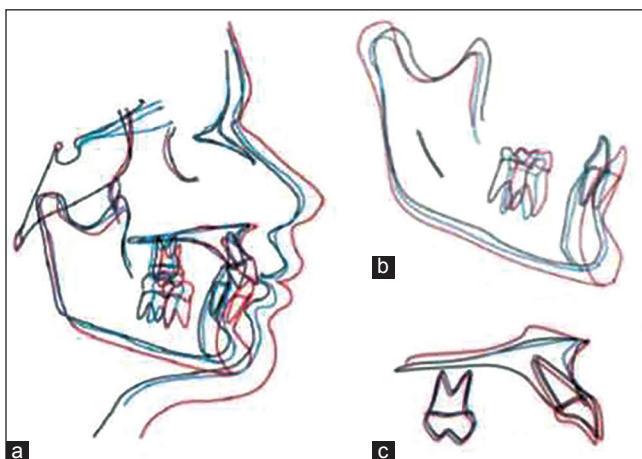


Figure 14: (a-c) Superimposition results

a considerable amount of the posterior cross bite was noticed that was addressed by incorporating the expansion screw in the appliance. Even though, authors recommend 5 mm of forward registration of the bite, in the present case, as it was class II division 2, the bite registration was taken for the incisor edge to edge position, ensuring 6-7 mm opening in the buccal segment. The Bass appliance was effective in maintaining the vertical dimension of the growth as there was no change in the inclination of either maxilla or mandible and the results were in agreement with the reports of the earlier study.^[9] On the contrary, when Bass compared with the other contemporary functional appliances, twin block was more effective in producing the sagittal and vertical changes.^[10]

CONCLUSION

Following positive changes were noticed in the present case:

- The forward mandibular growth was enhanced
- Maxillary growth was restrained
- Vertical dimension of the growth was maintained
- Desired overjet and overbite was achieved by correcting the upper and lower incisor inclination.

REFERENCES

1. Millett DT, Cunningham SJ, O'Brien KD, Benson PE, de Oliveira CM. Treatment and stability of class II division 2 malocclusion in children and adolescents: A systematic review. *Am J Orthod Dentofacial Orthop* 2012;142:159-69.e9.
2. Yousefian J, Trimble D, Folkman G. A new look at the treatment of class II division 2 malocclusions. *Am J Orthod Dentofacial Orthop* 2006;130:771-8.
3. Brezniak N, Arad A, Heller M, Dinbar A, Dinte A, Wasserstein A. Pathognomonic cephalometric characteristics of angle class II division 2 malocclusion. *Angle Orthod* 2002;72:251-7.
4. Tuncay OC, Tulloch JF. Apparatus criticus: Methods used to evaluate growth modification in class II malocclusion. *Am J Orthod Dentofacial Orthop* 1992;102:531-6.
5. Antonarakis GS, Kiliaridis S. Short-term anteroposterior treatment effects of functional appliances and extraoral traction on class II malocclusion. A meta-analysis. *Angle Orthod* 2007;77:907-14.
6. Bass NM. Orthopedic coordination of dentofacial development in skeletal class II malocclusion in conjunction with edgewise therapy. Part I. *Am J Orthod* 1983;84:361-83.
7. Lehman R, Romuli A, Bakker V. Five-year treatment results with a headgear-activator combination. *Eur J Orthod* 1988;10:309-18.
8. Bass NM. Orthopedic coordination of dentofacial development in skeletal class II malocclusion in conjunction with edgewise therapy. Part II. *Am J Orthod* 1983;84:466-90.
9. Cura N, Saraç M. The effect of treatment with the Bass appliance on skeletal class II malocclusions: A cephalometric investigation. *Eur J Orthod* 1997;19:691-702.
10. Illing HM, Morris DO, Lee RT. A prospective evaluation of Bass, Bionator and Twin Block appliances. Part I — The hard tissues. *Eur J Orthod* 1998;20:501-16.

How to cite this article: Doshi J, Shyagali TR, Trivedi KM. Skeletal class II malocclusion correction using the Bass appliance. *APOS Trends Orthod* 2015;5:44-8.

Source of Support: Nil. **Conflict of Interest:** None declared.