



Original Research

Maxillary central incisor gingival papilla and zenith heights with and without periodontally accelerated osteogenic orthodontics

Mariam Alzaabi¹, Donald J. Ferguson², Laith Makki³, M. Thomas Wilcko⁴

¹Private Practice in Orthodontics, Abu Dhabi, UAE, ^{2,3}Department of Orthodontics, European University College, Dubai, United Arab Emirates, ⁴Private Practice in Periodontology, Erie, PA, Department of Periodontology, Case Western Reserve University, Cleveland, OH, USA.




***Corresponding author:**

Donald J. Ferguson,
European University College,
Dubai Healthcare City, Bldg 27,
Block D, Office 302,
PO Box 53382, Dubai,
United Arab Emirates.
fergusonloud@gmail.com

Received : 08 June 19
Accepted : 10 June 19
Published : 28 September 19

DOI
10.25259/APOS_74_2019

Quick Response Code:



ABSTRACT

Objectives: The objective of the study is to compare maxillary central incisor gingival papilla and zenith heights photogrammetrically in orthodontically treatment patients with and without periodontally accelerated osteogenic orthodontics (PAOs).

Materials and Methods: Samples of 29 participants were matched for pre-treatment age and five gingival height dimensions supporting the four maxillary incisors. PAOO active orthodontic treatment time (9.29 vs. 20.47 months) and control post-treatment observation time (10.7 vs. 20.1 months) were significantly shorter ($P < 0.05$). Linear gingival heights were measured photogrammetrically on standardized intraoral frontal photographs perpendicular to a horizontal line constructed parallel to the maxillary central incisal edges.

Results: (1) The three papillae and two zenith gingival margins moved incisally as a consequence of conventional orthodontic therapy ($P < 0.05$) but not in PAOO therapy. (2) At least 6-month post-orthodontic treatment, PAOO gingival dimensions were longer for both central incisor zenith heights, and the interdental papilla height between maxillary central incisors was shorter.

Conclusions: Based on the conditions of the study, orthodontic treatment with and without PAOO results in similar maxillary incisor papilla and zenith heights if viewed from a clinical perspective.

Keywords: Gingival papilla height, Zenith height, Alveolar corticotomy

INTRODUCTION

The beautiful smile is a combination of teeth, gingiva, and lips to create unity, harmony, and esthetics. The interdental appearance of the gingival papilla in an apicocoronal location is critical during smiling.^[1] When the gingival embrasure is filled with the interdental papilla in proportion to surrounding teeth, the results of gingival architecture esthetics are positive and pleasing.^[2] Hence, preserving the interdental papilla in the gingival embrasure, particularly in the esthetic zone, is a key consideration in restorative and orthodontic treatment.^[3]

Chow *et al.*^[4] comprehensively summarized the clinical conditions found to favor a gingival papilla that fills the interproximal embrasure space as follows: (1) Young participant, (2) crown width/length ≥ 0.87 , (3) long proximal contact ≥ 2.8 mm, (4) bone crest to contact point

This is an open-access article distributed under the terms of the Creative Commons Attribution-Non Commercial-Share Alike 4.0 License, which allows others to remix, tweak, and build upon the work non-commercially, as long as the author is credited and the new creations are licensed under the identical terms.

©2019 Published by Scientific Scholar on behalf of APOS Trends in Orthodontics

≤5 mm, and (5) thick interproximal gingival tissue ≥1.5 mm. According to the authors, the site most susceptible to having a deficient papilla after orthodontic treatment was at the midline between the two maxillary central incisors.

The status of the interdental papilla consequent to comprehensive orthodontic treatment has been investigated. Kurth and Kokich^[5] observed gingival embrasure status between maxillary central incisors in 119 patients and reported 38% open embrasures prevalence in adults at post-orthodontic treatment. The authors found open gingival embrasures were not directly related to pre-treatment maxillary central incisor rotation and overlap. In contrast, open embrasures were associated with increased tooth contact point to crestal bone height, shorter and more incisally positioned interproximal contacts, divergent or triangular-shaped crown forms, and increased embrasure area. Castro *et al.*^[6] found no statistically significant change in gingival papilla height between the maxillary central incisors pre- and post-orthodontic treatment.

Periodontally accelerated osteogenic orthodontics (PAOOs) were introduced in 2001 by Wilcko *et al.* and reduce active orthodontic treatment time^[7] and root resorption.^[8] The technique includes alveolar augmentation bone grafting that has been shown to maintain labial bone thickness,^[9] labial bone height,^[10] as well as increase width of keratinized tissue.^[11]

Purpose and hypothesis

To date, no study has evaluated the interdental papilla height change in patients who had PAOO treatment. The aim of this study was to assess the status of the interdental papilla in patients with regard to (1) pre- and post-orthodontic treatment and (2) with and without a history of PAOO therapy. The null hypothesis tested was no difference in papillary and zenith heights measured photogrammetrically.

MATERIALS AND METHODS

Sample

The sample of this retrospective study was comprised 58 patients with healthy, intact periodontium without recession defect treated with comprehensive orthodontic therapy. Primary target variables were height of gingival papillae between maxillary incisors and maxillary central incisor zenith heights.

Selection criteria for all patients in this case-controlled study included the following: (1) Comprehensive orthodontic treatment in the permanent dentition using fixed, straight-wire orthodontic appliances 0.022" slot size with and without premolar extractions, (2) post-orthodontic treatment retainer wear with removable thermoplastic and/or Hawley-type

retainers, and (3) availability of intraoral frontal occlusion photographs showing maxillary gingiva status at pre-treatment and at least 6 months after active orthodontic therapy.

Participants were excluded on the basis of any of the following criteria: (1) Inability to measure the gingival papilla on the intraoral frontal photograph, (2) pre-treatment open bite malocclusion, (3) congenitally absent or missing maxillary incisor teeth, (4) diagnosis of any syndrome including cleft lip and palate, (5) history of orthognathic surgery, (6) history of smoking, (7) history of periodontal surgery, (8) interproximal caries or caries restoration, (9) absence of interproximal contact, or (10) gingival overgrowth.

Two equal groups of 29 participants were created with and without having undergone PAOO; the two samples were matched for sample size, pre-treatment age, and heights of gingival papillae between maxillary incisors and maxillary central incisor zenith heights.

Procedures

Approval of the Institutional Review Board at European University College was obtained to conduct the retrospective research project.

Target measurement variables included the clinical height of interdental papilla located in the labial embrasure between maxillary central incisors and between maxillary centrals and laterals incisors (3 sites per participant) as well as the gingival zenith of both maxillary central incisors. Measurements were obtained from standardized photographic images of the frontal intraoral view using ImageJ software before and after orthodontic treatment. Pre-treatment and retention photographs were standardized per participant following a modification of Coatoam *et al.*^[12] and Trentini *et al.*^[13] published equations proven to be reliable and valid: Pre-tx central width/retention central width X retention gingival height measurement. All retention gingival height values recorded were thereby standardized.

- A horizontal line was constructed vertically 3 mm from the mid-incisal edge of each maxillary central incisor [Figure 1].
- The height of the interdental papilla was measured and recorded from the tip of the papilla perpendicular to the horizontal reference line drawn per tooth parallel to the incisal edge.
- The two measurements from each central incisor were averaged.
- The height of the central incisor gingival zenith perpendicular to the horizontal line was measured and recorded.

The ImageJ measurement technique was tested for validity by comparing measurements from photographic images

using ImageJ software to clinical measurements made on the patient. For the clinical measurements on patients, a 3 mm line bisecting the incisal edges was drawn on each central incisor, and a horizontal line parallel to the incisal edge was drawn on each central with a sharpened marker and a metal ruler. A digital caliper and a magnifying loop were then used to measure the vertical perpendicular distance from the tip of the papilla and from the zenith heights to the horizontal line. The ImageJ photogrammetric technique was described previously. Paired *t*-test was used to compare the means at 3-week intervals between clinical patient and photogrammetric ImageJ measurements; no significant differences were found at the 99% level of confidence.

The measurement techniques were tested for reliability by repeating both clinical and ImageJ photogrammetric measurements weekly for 3 weeks. ANOVA test was used to compare measurement means taken at 3-week intervals within both the clinical and the ImageJ techniques; no significant differences were found at the 99% confidence interval.

RESULTS

The sample in this retrospective study was comprised 58 patients with healthy, intact periodontium without recession defect treated with comprehensive orthodontic therapy. Two equal groups ($n = 29$) were created with and without PAOO therapy aged 30.5 and 30.9 years, respectively. Active

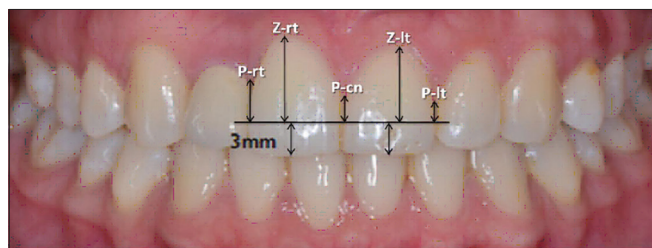


Figure 1: A horizontal line was constructed vertically 3 mm from the mid-incisal edge of each maxillary central incisor. The horizontal reference line was used to measure height of papillae right, left, and center as well as and zenith heights right and left on both pre-treatment and retention photographs.

orthodontic treatment time was 9.29 months for the PAOO group and 20.47 months and for non-PAOO (conventional) control group. Patient records were taken at pre-treatment (T1) and at least 6 months after removal of fixed orthodontic appliances (T2) [Table 1].

Although pre-treatment papilla and zenith heights were matched between the two groups, independent *t*-testing demonstrated a significantly greater PAOO post-treatment zenith heights on both right (8.74 vs. 7.84 mm, $P = 0.007$) and left (8.78 vs. 7.80 mm, $P = 0.011$) central incisors as well as a significantly shorter PAOO papilla height (3.25 vs. 2.63 mm, $P = 0.014$) located between the central incisors [Table 2].

Paired sample *t*-tests comparing papilla and zenith height means pre-treatment (T1) and post-treatment (T2) within each group demonstrated both papilla tips and zenith contours moved significantly more incisally in the control group as a consequence of conventional orthodontic therapy but not in the PAOO group [Table 3 and Figure 2].

DISCUSSION

A main finding of the present study was a statistically significant incisal pre-treatment to post-treatment movement of gingival margins due to the conventional orthodontic therapy (control) but not the PAOO therapy. Mean increases for the five study variable ranged from 0.32 to 0.52 mm in the control sample; although all five variables demonstrated significant statistical change, the amount of change in the control sample was not clinically important [Figure 2]. Interestingly, none of the gingival height study variables showed statistically significant change in the PAOO group while measurements ranged from 0.15 to -0.27 mm. No previous study has measured gingival height changes as in the present study.

Patient age and pre-treatment gingival study variable heights were matched between the two samples with and without PAOO therapy. An independent *t*-test comparison of the five study variables at least 6 months following active orthodontic therapy demonstrated that three variables differed; the papilla height between maxillary central incisors was significantly

Table 1: Description of study groups including, sample size, age at pre-treatment, active treatment time (pre-tx to post-tx), number cases with premolar extraction, and average length of observation time following removal of active orthodontic appliances. Note that samples were matched for size, pre-treatment age, and pre-treatment target gingival height parameters; PAOO active orthodontic treatment time (9.29 vs. 20.47 months) and control post-treatment observation time (10.7 vs. 20.1 months) were significantly shorter ($P < 0.05$).

Sample description	Description	Sample size	Pre-tx age	Premolar extraction (%)	Active Tx (months)	Observe (months)
Corticotomy+grafting+orthodontics	PAOO	29	30.5	0 (0)	9.29	20.1
Conventional orthodontics	Control	29	30.9	8 (27.6)	20.47*	10.7*

PAOO: Periodontally accelerated osteogenic orthodontics, *= $P < 0.05$

Table 2: Means and SD for study papilla and zenith height variables at pre-treatment (T1) and post-treatment (T2) as well as changes in variable dimensions from T1 to T2. Independent t-testing showed significantly shorter mean PAOO papilla height between central incisors and central incisor greater zenith heights.

Variables	Control (n=29)	PAOO (n=29)	Mean difference	Significance
	Mean±SD	Mean±SD		
Papilla right T1	3.48±0.99	3.50±1.31	-0.40	NC
Zenith right T1	8.15±1.45	8.74±1.29	-0.59	NC
Papilla center T1	3.00±0.75	3.40±0.86	-0.37	NC
Zenith left T1	8.15±1.64	8.52±1.15	-0.08	NC
Papilla left T1	3.43±1.06	3.51±0.88	-0.01	NC
Papilla right T2	2.96±1.03	3.50±1.08	0.53	NC
Zenith right T2	7.84±1.34	8.74±1.14	0.91	0.007
Papilla center T2	2.63±0.91	3.25±0.95	0.62	0.014
Zenith left T2	7.80±1.55	8.78±1.28	0.98	0.011
Papilla left T2	3.09±0.94	3.53±1.08	0.44	NC
Papilla change right	0.52±0.78	0.00±1.17	-0.52	NC
Zenith change right	0.32±0.61	-0.01±0.99	-0.32	NC
Papilla change center	0.37±0.64	0.15±0.96	-0.22	NC
Zenith change left	0.35±0.64	-0.26±1.08	-0.60	0.012
Papilla change left	0.35±0.82	-0.02±0.98	-0.36	NC

SD: Standard deviations, PAOO: Periodontally accelerated osteogenic orthodontics, NC=Non-significant, i.e., $P>0.05$

Table 3: Within group paired t-testing demonstrated measurements to papilla tips and zenith heights decreased as a consequence of orthodontic treatment from pre-treatment (T1) to post-treatment (T2) for both PAOO and conventional control groups.

Variable	Control T1-T2 change		PAOO T1-T2 change	
	Mean difference	Significance	Mean difference	Significance
Papilla right	0.52	0.001	0.00	NC
Zenith right	0.32	0.009	0.01	NC
Papilla center	0.37	0.004	0.15	NC
Zenith left	0.35	0.007	0.27	NC
Papilla left	0.35	0.031	0.02	NC

PAOO: Periodontally accelerated osteogenic orthodontics, NC=Non-significant, i.e., $P>0.05$

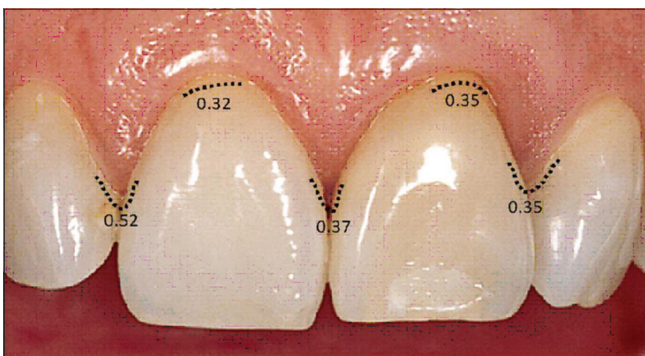


Figure 2: Change (in millimeters) of papilla and zenith gingival measurements in the incisal direction from pre-treatment to at least 6 months after active conventional orthodontic treatment (control sample). Papilla and zenith heights demonstrated a statistically significant ($P < 0.05$) incisal movement, but the amount of change was not clinically important.

shorter in the PAOO group compared to control, and both central incisor zenith heights were significantly greater in

the PAOO compared to control. In PAOO, post-treatment midline papilla height averaged 0.62 mm ($P = 0.014$) shorter and zenith heights averaged about 0.94 mm longer ($P < 0.02$) in PAOO.

Shorter midline papillae and longer central incisor zenith heights in the PAOO group may be the result of more pre-treatment crowding in the PAOO patients. Although amount of pre-treatment crowding was not assessed in the study, it is well established that a greater amount of crowding can be managed by PAOO therapy compared to conventional orthodontic therapy.^[14] The PAOO maxillary incisors may have experienced greater rotation, proclination, and/or prominence than did the non-PAOO maxillary incisors, and a more apical relocation of the gingival margins in the PAOO patients may have resulted. In other words, the amount of tooth movements that were needed to accommodate dental arch malocclusion may have been greater in PAOO than in control. Because this situation was possible, all pre-treatment photographs were reviewed for both samples; it was found

generally a greater maxillary incisor overlap (crowding) between central and lateral incisors but not between central incisors. Hence, the potential confounding factor of crowding differences between samples does not appear to have been a major intervening factor in height of central papilla.

Active orthodontic therapy for PAOO averaged half the amount of time compared to control (9.29 vs. 20.47 months), and post-therapy observation time was twice as long in the PAOO group (20.1 vs. 10.7 months). An observation time of 10.7 months for control vs. 20.1 months for experimental is a confounding factor that may have influenced the results of the study, but these number of months should be adequate for the normalizing of periodontal soft tissues. Hence, neither active therapy nor post-treatment observation times adequately explain the differences in gingival study heights between the groups.

Type of retainer used is a confounding factor. Control used primarily a vacuum formed retainer whereas the experimental group started with a vacuum formed which was replaced by a removable Hawley-type retainer. Other factors (e.g., root angulation of adjacent teeth, crown shape, space between adjacent teeth, and volume of the embrasure space) which affect the interdental papilla were not examined. Future studies should consider the interactions of these factors in relation to differences in gingival heights. Differences in findings regarding the amount of periodontal support loss resulting from a full period of orthodontic treatment with fixed appliance may partly reflect differences in achieved degree of plaque control by the patients during treatment.^[15] Accurate information on hygiene status and toothbrushing habits of the patients in the present study was not available.

Results of the present study indicated that periodontal gingival margins moved significantly more incisally in the control group. These results conflict with one other studies that observed the interdental papilla after conventional orthodontic treatment. Castro *et al.*^[6] measured interincisal papilla height between maxillary central incisors perpendicular to a horizontal line connecting maxillary central incisor zenith heights and reported no statistically significant change as a result of orthodontic therapy. However, this technique does not account for zenith height changes which may have influenced the papilla height measurement.

CONCLUSIONS

Maxillary gingival papilla and zenith heights were compared in orthodontically treatment samples with and without PAOO. The samples ($n = 29$ each) were matched for pre-treatment age and five gingival height dimensions supporting the four maxillary incisors. Average PAOO

active orthodontic treatment time (9.29 vs. 20.47 months) and control post-treatment observation time (10.7 vs. 20.1 months) were significantly shorter ($P < 0.05$). Linear gingival height measurements were made perpendicular to a horizontal line constructed parallel to the maxillary central incisal edges. The following results were demonstrated:

1. The three papillae and two zenith gingival margins moved incisally as a consequence of conventional orthodontic therapy ($P < 0.05$) but not in PAOO therapy.
2. At least 6-month post-orthodontic treatment, PAOO gingival dimensions were longer for both central incisor zenith heights and the interdental papilla height between maxillary central incisors was shorter.

Based on the conditions of the study, it may be concluded that orthodontic treatment with and without PAOO results in maxillary incisor papilla and zenith heights that are similar if viewed from a clinical perspective.

Financial support and sponsorship

Nil.

Conflicts of interest

Author MT Wilcko has a conflict of interest by holding a patent related to Accelerated Osteogenic Orthodontics and Periodontally Accelerated Osteogenic Orthodontics. The authors Alzaabi, Ferguson, and Makki declare to have no conflict of interest and designed the study at their own initiative. This study was self-funded by the authors and their institution.

REFERENCES

1. Jain N, Dugal R, Kheur M, Musani S. Factors influencing the presence of interproximal dental papillae between maxillary anterior teeth: A clinical and radiographic study of the Indian population. *World J Dent* 2013;4:158-63.
2. Ziahosseini P, Hussain F, Millar BJ. Management of gingival black triangles. *Br Dent J* 2014;217:559-63.
3. Sharma AA, Park JH. Esthetic considerations in interdental papilla: Remediation and regeneration. *J Esthet Restor Dent* 2010;22:18-28.
4. Chow YC, Eber RM, Tsao YP, Shotwell JL, Wang HL. Factors associated with the appearance of gingival papillae. *J Clin Periodontol* 2010;37:719-27.
5. Kurth JR, Kokich VG. Open gingival embrasures after orthodontic treatment in adults: Prevalence and etiology. *Am J Orthod Dentofacial Orthop* 2001;120:116-23.
6. Castro LO, Borges GJ, Castro IO, Porto OC, Estrels C. Change of incisive papilla height due to orthodontic movement: An evaluation in study models and three-dimensional images. *Stomatos* 2012;18:52-9.
7. Wilcko WM, Wilcko T, Bouquot JE, Ferguson DJ. Rapid orthodontics with alveolar reshaping: Two case reports of

- decrowding. *Int J Periodontics Restorative Dent* 2001;21:9-19.
8. Ferguson DJ, Machado I, Wilcko MT, Wilcko WM. Root resorption following periodontally accelerated osteogenic orthodontics. *APOS Trends Orthod* 2016;6:83-9.
 9. Ahn HW, Lee DY, Park YG, Kim SH, Chung KR, Nelson G, *et al.* Accelerated decompensation of mandibular incisors in surgical skeletal class III patients by using augmented corticotomy: A preliminary study. *Am J Orthod Dentofacial Orthop* 2012;142:199-206.
 10. Wang B, Shen G, Fang B, Yu H, Wu Y, Sun L, *et al.* Augmented corticotomy-assisted surgical orthodontics decompensates lower incisors in class III malocclusion patients. *J Oral Maxillofac Surg* 2014;72:596-602.
 11. Wilcko MT, Ferguson DJ, Makki L, Wilcko WM. Keratinized gingiva height increases after alveolar corticotomy and augmentation bone grafting. *J Periodontol* 2015;86:1107-15.
 12. Coatoam GW, Behrents RG, Bissada NE. The width of keratinized gingiva during orthodontic treatment: Its significance and impact on periodontal status. *J Periodontol* 1981;52:307-13.
 13. Trentini CM, Moriarty JD, Phillips C, Tulloch JF. Evaluation of the use of orthodontic records to measure the width of keratinized tissue. *J Periodontol* 1995;66:438-42.
 14. Ferguson DJ, Wilcko MT, Wilcko WM, Makki L. Scope of treatment with periodontally accelerated osteogenic orthodontics therapy. *Semin Orthod* 2015;21:176-86.
 15. Artun J, Krogstad O. Periodontal status of mandibular incisors following excessive proclination. A study in adults with surgically treated mandibular prognathism. *Am J Orthod Dentofacial Orthop* 1987;91:225-32.

How to cite this article: Alzaabi M, Ferguson DJ, Makki L, Wilcko MT. Maxillary central incisor gingival papilla and zenith heights with and without periodontally accelerated osteogenic orthodontics. *APOS Trends Orthod* 2019;9(3):172-7.